

Laparoscopic Adhesiolysis for Subfertility

S Chew, C Chan, S C Ng, S S Ratnam

ABSTRACT

Aim: Laparoscopic adhesiolysis has been associated with pregnancy rates of 12% to 58%. This study looks at our experience with laparoscopic adhesiolysis in the management of subfertile patients.

Method & Results: Between January 1992 and March 1995, 27 subfertile patients who had laparoscopic adhesiolysis done were studied. Four patients (15%) had a second look laparoscopy. The overall pregnancy rate (after excluding 6 patients with bilateral tubal blockage or severe male factor) was 33% (7/21). The take home baby rate was 14.3% (3/21) and the ectopic pregnancy rate was 4.7% (1/21).

Conclusion: Laparoscopic adhesiolysis still remains a useful and effective procedure for infertile couples with pelvic adhesions.

Keywords: laparoscopic adhesiolysis, pregnancy rate

INTRODUCTION

Pelvic adhesive disease has been implicated as a cause in 15% – 20% of infertile couples. Laparoscopic adhesiolysis with restoration of pelvic anatomy has been associated with intrauterine pregnancy rates of 12% to 58%⁽¹⁻⁵⁾. The results are comparable to those obtained by microsurgical adhesiolysis via laparotomy⁽⁶⁾. Our study aimed to review our experience with laparoscopic adhesiolysis in the management of subfertile patients.

MATERIALS AND METHODS

We retrospectively analysed the data of subfertile patients who had laparoscopic adhesiolysis performed between January 1992 and March 1995. The patients' age, past history of endometriosis, pelvic inflammatory disease, previous surgery, duration and cause of subfertility were noted. Patients whose husband's sperm count was persistently less than 10 million/mL were classified as having severe male factor; and patients whose husband's semen analysis was abnormal but with sperms counts in excess of 10 million/mL were classified as having mild male factor. The laparoscopic finding of adhesions and endometriotic deposits were scored using the revised American Fertility Society (r-AFS) classification (1985). Adhesiolysis was accomplished at the first diagnostic laparoscopy (via 3 – 4 puncture sites), using

mainly carbon dioxide laser usually at 18 W superpulse, continuous mode (Illumina 750, Lasersonic Inc., USA). At the end of the procedure, the adhesions were assessed to be either completely, more than 50% or less than 50% lysed. Tubal patency was also tested with transcervical chromotubation using methylene blue. In some cases, adjuvants such as Interceed (oxidised sequestered cellulose, Ethicon, USA) or Hyskon (32% Dextran 70) (Kabi Pharmacia AB, Sweden) were used. A second look laparoscopy was suggested to all but was accepted by four patients and the adhesions again assessed to be either completely, more than 50% or less than 50% lysed. Patients with moderate and severe endometriosis diagnosed at the time of the first laparoscopy were also counselled to have postoperative hormonal therapy for six months. All patients were followed up after the first laparoscopy and those patients who conceived spontaneously during this period were analysed (excluding those with tubal blockage or severe male factor).

RESULTS

Twenty-seven patients with subfertility underwent laparoscopic adhesiolysis at the National University Hospital during the study period. The ages of these patients ranged from 27 to 44 years (mean \pm S.D. = 33.5 ± 4.3 years). None had a past history of pelvic inflammatory disease but 12 patients (44%) gave a previous history of endometriosis. Seven of these patients also had previous hormonal suppression of their endometriosis with danazol ($n = 5$) and gonadotrophin releasing hormone analogues (GnRHa) ($n = 2$). Eighteen patients (66%) had previous surgery. These included nine with laparotomy and cystectomy for endometriosis, four with previous laparoscopies, two with lower segment caesarean sections, one with appendicectomy, one with salpingectomy for ectopic pregnancy and one with a laparoscopic cystectomy performed. The period of involuntary subfertility ranged from 1 to 14 years (mean \pm S.D. = 4.4 ± 3.2 years) (Fig 1). There were 16 patients with mild and 2 with severe male factor problems.

At laparoscopy, the r-AFS adhesion scores ranged from 4 to 40 (mean \pm S.D. = 23.5 ± 16.3) (Fig 2). Endometriosis was present in 16 (59%) patients and in addition to adhesiolysis, these patients also had their endometriotic deposits ablated at the time of surgery.

Department of Obstetrics
& Gynaecology
National University Hospital
5 Lower Kent Ridge Road
Singapore 119074

S Chew, MBBS, M Med (O&G),
MRACOG
Lecturer

C Chan, MBBS, FRACOG,
FAMS
Associate Professor

S C Ng, M Med (O&G),
MRCOG, FAMS
Professor

S S Ratnam, FRCOG, FRCS,
DSc (Hon)
Professor

Correspondence to:
Dr S Chew

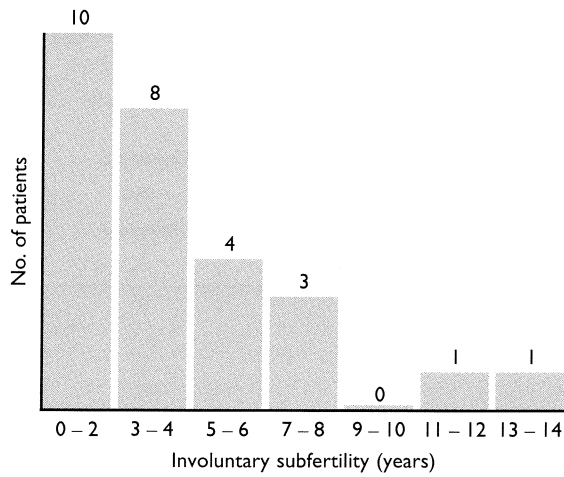


Fig 1 – Period of Involuntary subfertility

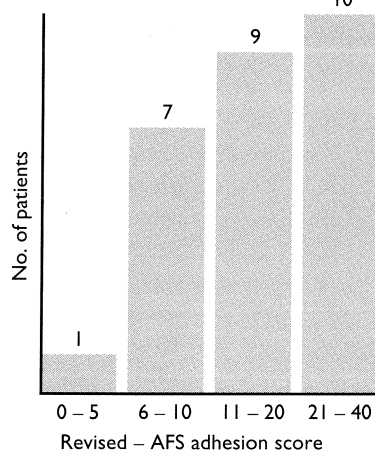


Fig 2

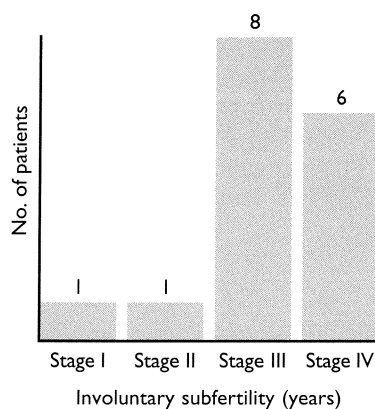


Fig 3

The mean (\pm S.D.) AFS score was 47 (\pm 3) (range 1 – 90) (Fig 3). In 23 (85%) patients, the carbon dioxide laser was used for adhesiolysis. The monopolar diathermy and scissors were used for adhesiolysis in one (4%) and three (11%) patients respectively when the laser was not available.

After adhesiolysis, there were 4 patients (15%) with less than 50% clearance and 16 patients (59%) in whom more than 50% of the adhesions were lysed. In 7 patients (26%), the adhesions were completely lysed at the end of the procedure. Three patients had adjuvant therapy (two with Interceed and another with Hyskon) to reduce the risk of adhesion reformation. There were no intraoperative complications requiring laparotomy and post-operative recoveries were uneventful. Ten patients were put on post-operative hormonal therapy for endometriosis (4 with danazol, 5 with GnRH analogues and 1 with gestrinone).

There were four (15%) patients who had a second look laparoscopy performed (Tables I and II). The intervals between the initial and the second look laparoscopy ranged from 1 – 12 weeks. The adhesion scores at the initial procedure were all reduced respectively when compared to the adhesion scores at the second look laparoscopy (32 to 8, 40 to 20, 8 to 0, 9 to 3) (Table I). Filmy adhesions recurred in the first three cases and there were no de novo adhesions. The adhesiolysis was deemed complete in 2 patients and more than 50% complete in the third case (Table I). Interceed was used as an adjuvant therapy in the prevention of adhesion reformation in three cases. Two patients conceived after the second look laparoscopy. The first patient was 39 years old who first presented after four years of subfertility. Her husband's semen analysis was normal. She had an adhesion score of 9 at the first laparoscopy as well as minimal endometriosis. The adhesion score was 3 when a second look laparoscopy was performed a week later. She conceived the next month but miscarried at six weeks gestation. In the second case, a 30-year-old patient with subfertility for two years had an adhesion score of 8 at the first laparoscopy. She conceived 3 months after her first laparoscopy and presented with pain, bleeding and a suspicious adnexal mass on transvaginal scan. At the time of laparoscopy, the pelvis was free from adhesions but a tubal ectopic pregnancy was noted and a laparoscopic salpingostomy was done. Although the laparoscopy was performed to exclude an ectopic pregnancy, we included it as a second look laparoscopic procedure because an assessment of the pelvis for adhesions was also done. There were no additional problems of male factor disease or endometriosis in this couple. The other 2 patients who had second look laparoscopies but failed to conceive, had longer periods of infertility (5 and 7 years), additional male factor problems, endometriosis, and higher adhesions scores (Tables I and II).

There were 10 patients put on post-operative hormone therapy for endometriosis for six months. Only one patient on gestrinone conceived 13 months after her first laparoscopic adhesiolysis. The mean

Table I – Summary of the laparoscopic findings of the patients with second look laparoscopy

Case no.	Adhesion score at 1st laparoscopy	Interval between 1st & 2nd look (wks)	Adhesion score at 2nd look	Technique of adhesiolysis	% Complete	Adjuvant therapy	Pregnancy
1	32	1	8	CO ₂ laser	Complete	Interceed	No
2	40	1	20	CO ₂ laser	> 50%	Interceed	No
3	9	1	3	CO ₂ laser	Complete	Interceed	Yes +
4	8	12	0	-	-	No	Yes*

* Ectopic pregnancy 3/12 after first laparoscopy

+ Conceived 1/12 after second look but miscarried at 6 weeks gestation

Table II – Summary of the other antifertility factors of patients with second look laparoscopy

Case no.	Age	Period of infertility (years)	Male factor	Presence of endometriosis
1	31	5	Mild	Yes (r-AFS 90)
2	32	7	Mild	No
3	39	4	No	Yes (r-AFS 1)
4	30	2	No	No

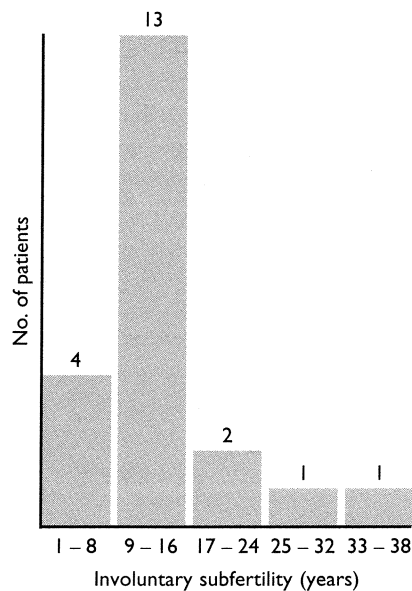


Fig 4 – Period of follow-up (months)
* (excluding patients with severe male factor and tubal blockage)

follow-up for these patients with endometriosis and treated with post-operative hormone therapy was 16.3 ± 8.7 months.

For the remaining 17 patients, there were 4 with bilateral tubal blockage and 2 with severe male factor disease. Excluding these 6 patients with either bilateral tubal blockage or severe male factor, the mean follow-up period for the remaining 21 patients was 13.8 ± 8.4 months (range 1 – 38 months) (Fig 4). Altogether there were 5 patients who conceived with 7 pregnancies including the two who had second look

procedures. A summary of these 5 patients who conceived is shown in Table III. The ages of these 5 patients ranged from 29 to 39 years, with periods of subfertility varying from 1 to 4 years. Their adhesion scores ranged from 4 to 28 and they conceived 1 to 16 months (mean 6.7 months) after their initial adhesiolysis. Of the 7 pregnancies, one was a tubal pregnancy, 3 ended as early first trimester pregnancy losses and 3 were full term deliveries (including 1 set of twins).

DISCUSSION

Subfertility is still an important indication for adhesiolysis. Adhesions may cause infertility by distorting pelvic anatomy with or without causing tubal blockage. Peritubal adhesions may affect the ovum pick-up by the fimbriae. Periovarian adhesions may also interfere with the normal ovulatory function⁽⁷⁾.

Laparoscopic adhesiolysis may be accomplished with sharp scissor dissection, electrocautery or lasers. Adhesiolysis with sharp dissection and electrocautery was advocated by Semm⁽⁸⁾ who described complete lysis of adhesion with cutting and coagulation in a report involving 374 patients. The CO₂ laser has been increasingly used in laparoscopic adhesiolysis. Theoretical advantages of the laser in adhesiolysis include the precise destruction of abnormal tissue with minimal bleeding and with less thermal damage to adjacent tissue. In our study, adhesiolysis was performed by sharp scissor dissection in 3 cases, monopolar cautery in one patient, while the rest (23 patients) had CO₂ laser adhesiolysis. Despite the use of the CO₂ laser in the majority of our cases, there is however, no evidence in the literature to suggest that

Table III – Summary of patients who conceived after adhesiolysis

Case no.	Age	Infertility (years)	Male factor	Adhesion score (r-AFS)	Presence of endometriosis	Time interval between (mths) adhesiolysis and pregnancy	Outcome of pregnancy
1	32	2	No	4	No	16/12	Term delivery
2	30	2	Mild	28	No	(i) 1/12 (ii) 12/12	(i) Miscarriage at 8 weeks of gestation (ii) term delivery
3*	39	4	No	9	Yes (r-AFS=1)	1/12	Miscarriage at 6 weeks
4*	30	2	No	8	No	3/12	Etopic pregnancy
5	29	1	Mild	8	Yes (r-AFS=21)	(i) 1/12 (ii) 13/12	Missed abortion at 8 weeks. Twins (spontaneous conception) Term delivery

* Had 2nd look laparoscopy

this modality is superior to the rest. Filmar et al⁽⁹⁾ using a rat model, showed that the CO₂ laser and electromicrosurgery were equally effective in adhesiolysis. Luciano et al⁽¹⁰⁾ used CO₂ laser and microcautery on rabbit uterine horns and found no difference between the two modalities in terms of tissue healing and post-operative adhesion formation. Tulandi et al⁽¹¹⁾ in a prospective randomised study, performed salpingoovariolysis using the CO₂ laser or microcautery needle. Although their data suggested a decreased time to conception with the CO₂ laser, there was however, no difference in the cumulative pregnancy rates between the two modalities. Thus at present, the literature seems to suggest that sharp dissection with electrocautery and CO₂ laser for adhesiolysis are equally effective.

Adhesions may reform in patients after reproductive surgery despite careful surgical technique and the use of adjuvant therapy. Diamond et al⁽¹²⁾ have also described de novo adhesions forming in patients after reproductive pelvic surgery. These adhesions form in apparently unoperated pelvic sites and are thought to be caused by talc deposition, tissue abrasion and other peritoneal trauma. In our 4 patients who had second look laparoscopies, there were no de novo adhesions found. However, filmy adhesions had reformed in 3 (75 %) patients one week after the initial adhesiolysis. One patient with an initial adhesion score of 8 at the time of the first adhesiolysis was free of adhesions when a second laparoscopy was done 12 weeks later. In this patient, tubal pregnancy occurred despite the absence of any adhesions. It is possible that microscopic damage of the endosalpinx, in the absence of peritubal adhesions, might have led to tubal ectopic pregnancy. Various adjuvant agents have been used post-operatively in an attempt to reduce adhesion reformation. A common adjuvant used is Hyskon (32% dextran 70). This highly viscous liquid acts by minimising the contact between serosal and peritoneal surfaces during the period of mesothelial healing. Interceed (TC7), is an oxidised regenerated cellulose that acts by providing a barrier between the healing and surrounding tissue, thus

reducing the risk of adhesion formation. Some investigators have also found that the extent and severity of reformed adhesion may increase with the time interval from the initial surgery. DeCherney and Mezer⁽¹³⁾ reported that an early second look laparoscopy done 4 – 16 weeks post-operatively showed that 15% of the reformed adhesions were moderate to severe, whereas a second look laparoscopy done 16 – 19 months later resulted in 63% moderate to severe adhesions.

At present, the role of the second-look laparoscopy (SLL) is still being determined. Since adhesion reformation does occur post-operatively, the SLL may then be useful for evaluation and treatment of these newly formed adhesions. For our 4 patients who had SLL performed, all had reduced adhesion scores and the 3 patients with reformed adhesions had these lysed with the CO₂ laser. In our series, the timing of the SLL ranged from 1 – 12 weeks. Although the timing of the SLL is still controversial, Raj and Hulka⁽¹⁴⁾ have reviewed the data on SLL performed at varying post-operative intervals and have suggested that a 4-8 week time interval may be optimal.

At present, whether SLL with adhesiolysis of reformed adhesions can actually improve conception rates is still a moot point. Of the 4 patients who underwent SLL in our 10 series, two conceived. However, one pregnancy was a tubal pregnancy while the other ended as a miscarriage at six weeks gestation. Trimbo Kemper et al⁽¹⁵⁾ reported a series in which SLL was done eight days after surgery to lyse fresh adhesions and a third laparoscopy performed in the second post-operative year. Although they did not find an increase in pregnancy rates with this approach, they did report a reduced incidence of ectopic pregnancy. Furthermore, Tulandi et al⁽¹⁶⁾ who reported on the outcome of SLL one year after surgery, also found that there was no significant increase in pregnancy rates in his series.

SLL may also be useful in assessing the effectiveness of adjuvant therapy in reducing post-operative adhesions. Unfortunately the experience with adjuvant therapy in our series is limited. Only

3 patients had either Interceed (n = 2) or Hyskon (n = 1) applied at the initial laparoscopic adhesiolysis procedure. Furthermore, only 3 patients who had SLL with repeat adhesiolysis had Interceed used. Although an initial study⁽¹⁷⁾ has suggested that Hyskon could reduce adhesion formation, a subsequent prospective, randomised controlled study by Jansen⁽¹⁸⁾ failed to confirm its efficacy in adhesion prevention. In 1992, the Obstetrics and Gynecology Adhesion Prevention Committee⁽¹⁹⁾ reported that the use of Interceed was effective in reducing the incidence and extent of post-operative adhesions, even in patients with severe endometriosis.

The pregnancy rates after laparoscopic adhesiolysis were analysed by Howard 1992⁽⁶⁾. His review of the current literature suggests that the pregnancy rates with laparoscopic adhesiolysis range from 24% to 59% (mean 43%). The incidence of ectopic pregnancy in these studies range from 5% to 11%.

In our present series, of the 27 patients who underwent laparoscopic adhesiolysis, four patients had bilateral tubal blockage and two had husbands with severe male factor. Of the remaining 21 patients, five (18.5%) conceived during the study period. The overall pregnancy rate was 33% (7/21) and the take home baby rate was 14.3% (3/21). The ectopic pregnancy rate was 4.7% (1/21). Our overall pregnancy rate of 33% is lower than the mean of 43% as reported by Howard⁽⁶⁾. This may be due to the fact that our patients, with a mean age of 34 years, had relatively long periods of infertility (mean of 4.4 years), 18 (66%) had concomitant male factor problems and 16 (59%) patients had associated endometriosis with a high mean AFS score of 47.

The role of laparoscopic adhesiolysis in infertility has been critically appraised⁽⁶⁾. Compared with microsurgical adhesiolysis via laparotomy, the laparoscopic approach has several advantages. Firstly, laparoscopic adhesiolysis may be performed as a day surgery procedure at the same time as the diagnostic laparoscopy. It is also associated with shorter hospitalisation and recovery times. Several authors^(20,21) have also reported fewer de novo adhesions associated with laparoscopic surgery compared to open laparotomy. Therefore although the overall pregnancy rates after laparoscopic adhesiolysis are similar to those obtained after microsurgical adhesiolysis at open surgery⁽⁶⁾, laparoscopic adhesiolysis remains a useful and effective procedure for infertile patients with pelvic adhesions.

REFERENCES

- Gomel V. Salpingo-ovariolysis by laparoscopy in infertility. *Fertil Steril* 1983; 40:607-11.
- Madelenat P, Palmer R. Etude critique des liberations percoelioscopiques des adherences peri-annexielles. *J Fr Gynecol Obst Reprod* 1979; 8:347-51.
- Bruhat MA, Mage G, Manhes H, Soualhat C, Ropert JF, Pouly JL. Laparoscopy procedures to promote fertility: ovariolysis and adhesiolysis: results of 93 selected cases. *Acta Eur Fertil* 1983; 14:113-7.
- Donnez J. CO₂ laser laparoscopy in infertile women with endometriosis and women with adnexal adhesions. *Fertil Steril* 1987; 48:390-6.
- Serour GI, Badrouni MH, El Agizi HM, Hamed AF, Abdel-Aziz F. Laparoscopic adhesiolysis for infertile patients with pelvic adhesive disease. *Int J Gynecol Obstet* 1989; 30:249-52.
- Howard FM. Breaking new ground or just digging a hole? An evaluation of gynecologic operative laparoscopy. *J Gynecol Surg* 1992; 8:143-58.
- Hamilton CJCM, Evers JLH, Hoogland HJ. Ovulatory disorders and inflammatory adnexal damage: a neglected cause of failure of fertility microsurgery. *Br J Obstet Gynecol* 1986; 93:282-7.
- Semm K. Change in classic gynecologic surgery: review of 3,300 pelviscopies in 1971-1976. *Int J Fertil* 1979; 24:13-20.
- Filmar S, Gomel V, McComb P. The effectiveness of CO₂ laser and electromicrosurgery in adhesiolysis: a comparative study. *Fertil Steril* 1986; 45:407-11.
- Luciano AA, Whitman G, Maier DB, Randolph J, Maenza R. A comparison of thermal injury, healing patterns and postoperative adhesion formation following a CO₂ laser and electromicrosurgery. *Fertil Steril* 1987; 48:1025-9.
- Tulandi T. Salpingo-ovariolysis: a comparison between laser surgery and electrosurgery. *Fertil Steril* 1986; 45:489-91.
- Diamond MP, Daniell JF, Feste J, et al: Adhesion reformation and de novo adhesion formation after reproductive pelvic surgery. *Fertil Steril* 1987; 47:864-6.
- DeCherney AH, Mezer HC: The nature of posttuboplasty pelvic adhesions as determined by early and late laparoscopy. *Fertil Steril* 1984; 41:643-6.
- Raj SG, Hulka JF. Second-look laparoscopy in infertility surgery: therapeutic and prognostic value. *Fertil Steril* 1982; 38:325-9.
- Trimbos-Kemper TCM, Trimbos JB, Van Hall EV: Adhesion formation after tubal surgery: results of the eighth day laparoscopy in 188 patients. *Fertil Steril* 1985; 43:395-400.
- Tulandi T, Falcone T, Kafka I: Second-look laparoscopy 1 year following reproductive surgery. *Fertil Steril* 1989; 52:421-4.
- Adhesion study group: Reduction of postoperative pelvic adhesions with intraperitoneal 32% dextran 70: a prospective, randomised clinical trial. *Fertil Steril* 1983; 40:612-9.
- Jansen RPS: Failure of peritoneal adjuncts to improve the outcome of pelvic surgery in Young Women. *Am J Obstet Gynecol* 1985; 153:363-71.
- Sekiba K. The Obstetrics and Gynecology adhesion prevention committee: Use of interceed (TC7) Absorbable adhesion barrier to reduce post-operative adhesion reformation in infertility and endometriosis surgery. *Obstet Gynecol* 1992; 79:518-22.
- Nezhat CR, Nezhat FR, Metzger DA, Luciano AA. Adhesion reformation after reproductive surgery by videolaseroscopy. *Fertil Steril* 1990; 53:1008-12.
- Operative laparoscopy study group. Postoperative adhesion development after operative laparoscopy: Evaluation at early second-look procedures. *Fertil Steril* 1991; 55:700-5.