Singapore Med J 1999; Vol 40(3):165-170

Hospital Resuscitation of Cardiac Arrest Patients

Y H Lim, V Anantharaman

ABSTRACT

Resuscitation of collapsed cardiac patients is often a not-too-successful affair. It has been repeatedly emphasised that the most important aspect of cardiac resuscitation is early access, early recognition of ventricular fibrillation and early defibrillation in patients with ventricular fibrillation. However, the co-ordination of the various phases of cardiac resuscitation itself, which is often forgotten, would need a good organisation so that a systematic assessment of the patient can be done while resuscitation is in progress.

In this report, we describe a case of successful prolonged cardiac resuscitation with emphasis on the organisation of resuscitation as well as early defibrillation. We would also like to emphasise that all procedures that were done were performed correctly and their effects on the monitored patient were assessed frequently so as to maximise efficiency, myocardial salvage and patient survival.

Keywords: organisation of resuscitation, early defibrillation, ventricular fibrillation

INTRODUCTION

While it is well recognised that electrical conversion is the treatment of choice for ventricular fibrillation, the importance of other aspects of resuscitation, viz early recognition of imminent cardiac arrest, airway control, ventilation, and circulatory adjuncts and for these to be provided early and in an organised fashion is often not adequately appreciated. The management of refractory ventricular fibrillation needs to be well organised.

We report a patient with persistent VF whose successful resuscitation brings home the lessons of early and organised resuscitations, and utilisation of the various aspects of this patient's management to discuss various issues in cardiac arrest management.

Department of Emergency Medicine
Singapore General Hospital
Outram Road
Singapore 169608

Y H Lim, MBBS, FRCS (Edin)
Senior Registrar

V Anantharaman, MBBS, MRCP (UK)
Senior Consultant and Head

Correspondence to:
Dr Y H Lim

CASE REPORT

A 72-year-old Chinese male, SKS, presented to the Department of Emergency Medicine of the Singapore General Hospital with chest pain.

The patient, a martial arts instructor, had a previous history of hypertension and non-insulin dependent diabetes mellitus for a number of years for which his daily regular medication included aspirin, nifedipine, chlorpropamide and metformin. He also had an episode of amaurosis fugax two years earlier.

He presented with a history of repeated episodes of vague central chest discomfort, each lasting for just a few minutes. The patient was unable to quantitate the actual duration of this discomfort. It was brought on by physical exertion. He had no associated breathlessness, diaphoresis, nausea or vomiting. There was no radiation of discomfort and it was not related to meals. The patient did not use nitroglycerine tablets to obtain relief of symptoms. One of the episodes of chest discomfort had been associated with a fainting spell of "extremely short duration" from which he recovered spontaneously and did not suffer any injury or other obvious sequelae. He was completely asymptomatic on the day of consultation. He was triaged to the department's critical care area on the basis of his history.

Physical examination by the emergency physician revealed that he was comfortable at rest. His vital signs were as follows: heart rate 98 per minute, regular, with normal heart sounds. He was not tachypnoeic. His blood pressure was recorded at 128/72 mmHg. There was no evidence of heart failure. All his peripheral pulses were felt and were equal. No bruits were heard over the abdomen.

An initial electrocardiogram (ECG) (Fig 1) demonstrated left ventricular hypertrophy with an acute, antero-septal myocardial infarction. A portable erect chest X-ray was done and no abnormality was reflected. His random blood sugar level was 12.5 mmol/L, as reflected by the Reflolux(TM) glucose reflectance meter.

Soon after chest X-ray when the patient was awaiting transfer to the Coronary Care Unit, he suddenly developed a generalised seizure which lasted a few seconds, turned blue and collapsed. He was immediately pushed to the resuscitation room. The resuscitation team consisted of two doctors (the authors) and two staff nurses. The cardiac monitor showed ventricular fibrillation (Fig 2). Three stacked DC current shocks at 200 joules, 200 joules and 360 joules were delivered with no cardiac response.

External chest compression was immediately instituted. The patient was intubated with a size 8 cuffed endotracheal tube and ventilated with 100% oxygen. The resuscitation sequence for this patient was as follows:

- Intravenous adrenaline 1 mg in 10 mL was administered followed by two DC shocks at 360 joules with no response.

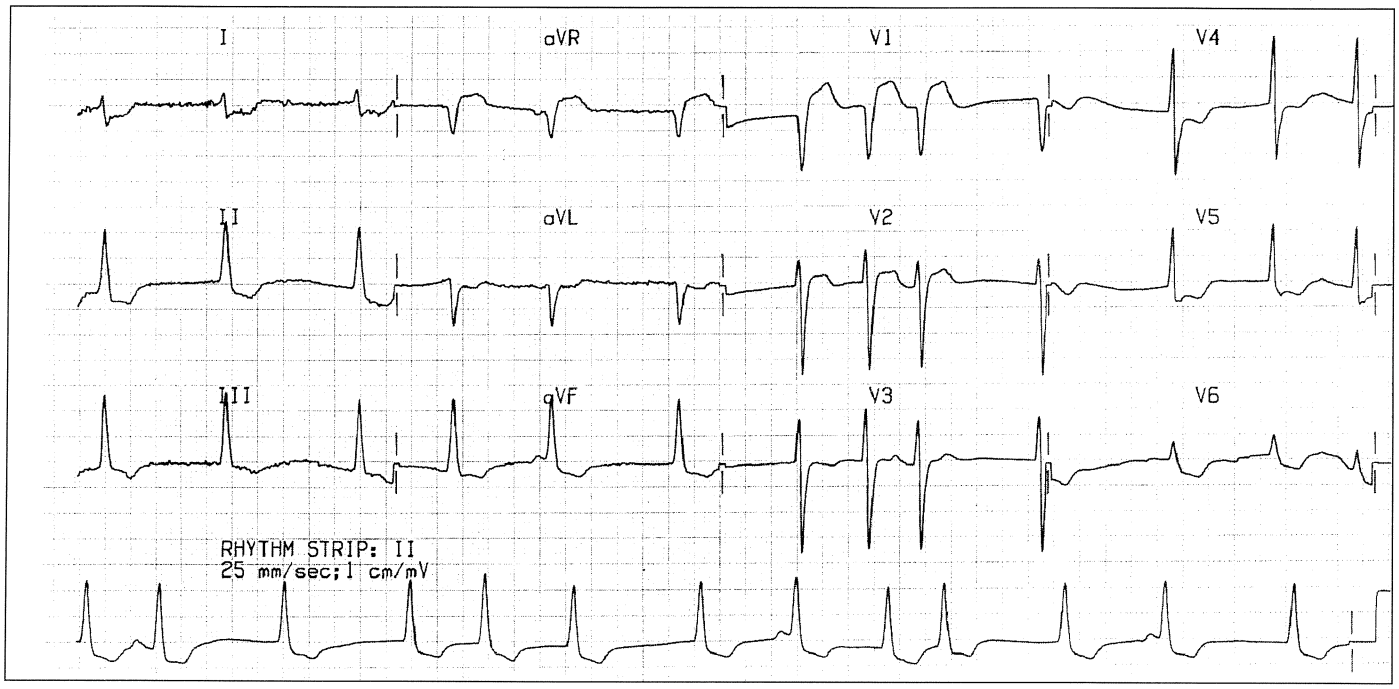

Fig 1 – Initial electrocardiogram – demonstrated left ventricular hypertrophy with an acute, antero-septal myocardial infarction.

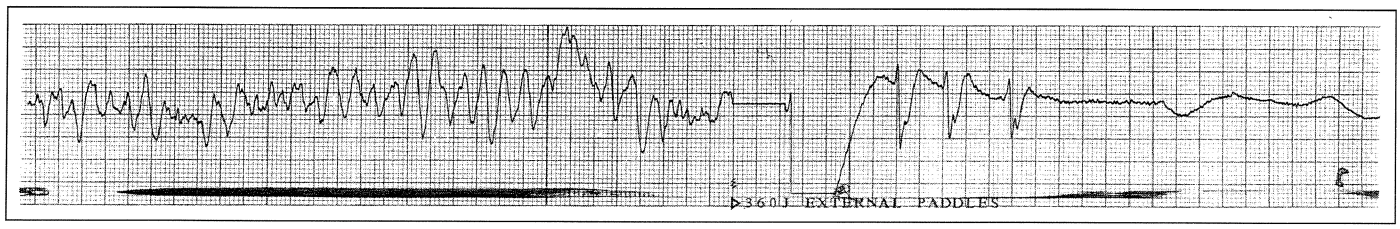

Fig 2 – Ventricular fibrillation as shown on the cardiac monitor.

- Intravenous lignocaine 100 mg was administered followed by two DC shocks at 360 joules with no conversion of the ventricular fibrillation (VF).
- Intravenous amiodarone 150 mg was then administered followed by one DC shock at 360 joules. The patient remained in persistent VF.
- Finally, intravenous magnesium sulphate 1g was administered followed by one DC shock at 360 joules. The ECG rhythm initially converted to atrial fibrillation and subsequently a palpable carotid pulse was felt.

The total time that elapsed between collapse and final electrical conversion was 28 minutes. During this time the patient received nine electrical shocks, two at 200 joules and the rest at 360 joules. In addition, he received intravenous doses of adrenaline, lignocaine, amiodarone and magnesium sulphate. Cardiopulmonary resuscitation and ventilation with 100% oxygen continued to be administered.

Post-conversion, the 12-lead ECG was, as shown in Fig 3. The patient was initially in deep coma and unresponsive. His pupils dilated to 4 mm in diameter but were reactive to light. He was flaccid in all four limbs.

Following conversion, he stayed a further 15 minutes in the resuscitation room before he was transferred to the Coronary Care Unit by a team of one doctor, one nurse and one health attendant, equipped with a cardiac monitor-cum-defibrillator, manual resuscitator and a set of resuscitative drugs. At the time of leaving the Emergency Department, the patient had begun moving both his arms and legs spontaneously.

He opened his eyes spontaneously in the Coronary Care Unit four hours from the time of collapse. He was extubated the next day and physical examination then revealed him to be neurologically intact. He was discharged well ten days after admission.

DISCUSSION

This is not the first time that a patient with an acute myocardial infarction had collapsed in the Emergency Department, nor will it be the last. The issues highlighted by this patient and which will be discussed are multiple and are as follows:

1. Need for early recognition of acute myocardial infarction in an Emergency Department.
2. Need for close monitoring even prior to transfer to an Intensive Care Unit.
3. Need for organisation of cardiac resuscitations.
4. Protocol for management of ventricular fibrillation.
5. Need for clear protocols for management of cardiac emergencies.

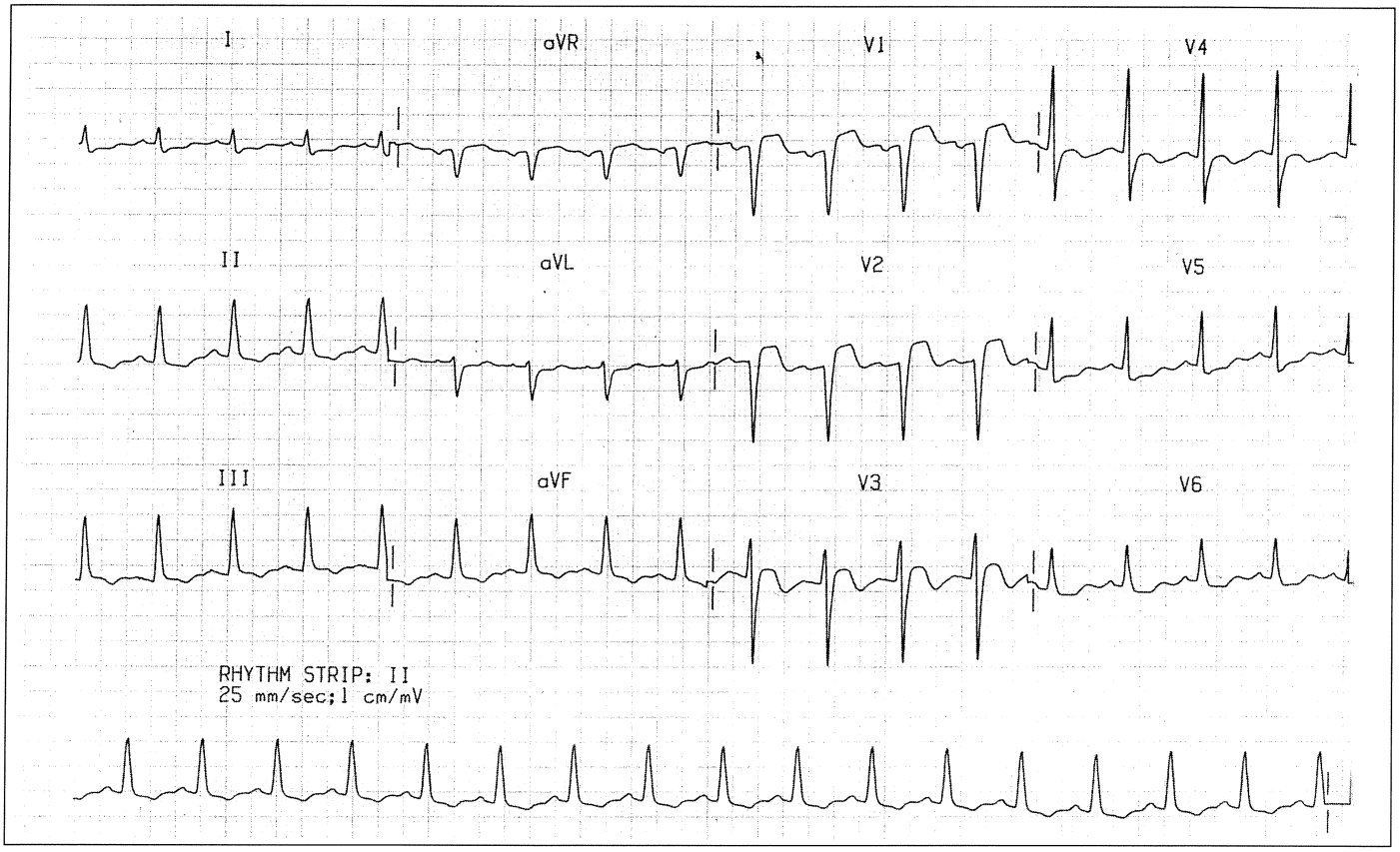

Fig 3 – Post-conversion 12-lead ECG.

Although many of the above have often been highlighted in recommendations of the American Heart Association[1] and in Advanced Cardiac Life Support[2] training programmes, their implementation and observance in medical institutions have never been mandated and are often left to individual practice.

Early recognition

There are two aspects of early recognition that one ought to be aware of. Firstly, there is the need to understand that a person is experiencing symptoms suggestive of a cardiac emergency which has potential for sudden cardiac death. The first link of the 'Chain of Survival' promulgated by the American Heart Association viz, 'Early Access' refers generally to accessing the Emergency Medical Services by members of the public. However early access has two prerequisites: the first is early recognition of a potential cardiac emergency; the second one is knowing the contact number of the Emergency Medical Services and ensuring their rapid access to the patient.

In a hospital environment, early recognition of a potential cardiac emergency should be prompt. A patient complaining of chest pain should not be made to wait for medical attention as long as myocardial infarction is considered a likely event. Systems are needed, even perhaps at registration and triage (in the case of Emergency Departments) to pluck such patients and push them through a fast-track service so that a cardiac emergency may be identified as early as possible. A few systems are available and some are enumerated:

1. Abnormal vital signs in a patient with a history of chest pain, eg. brady or tachycardia, tachypnoea or hypotension would result in a patient being directed to a higher priority attendance track. The danger lies in AMI patients with initial normal vital signs being made to wait for urgent care, with the potential dire consequences of such a wait.
2. An ECG could be initiated immediately for every patient presenting to the triage/registration desk of an Emergency Department with chest pain. Abnormalities suggestive of acute myocardial ischaemia would then warrant immediate attention by a physician, as happened to the patient described above.
3. All patients presenting with chest pain could be immediately attended to in a dedicated Fast-Track Chest Pain Evaluation and Treatment Unit (CPETU)[3] which may be an appendage of an Emergency Department that collaborates closely with a specialised Cardiology Unit. In a CEPTU, a careful clinical assessment followed by ECG and use of various markers would identify patients with definite acute myocardial infarction/unstable angina pectoris and critical interventions for these patients could be initiated. For patients in whom such diagnosis are not immediately made, a protocol of serial ECGs, continuous ECG monitoring and serial cardiac enzymes, followed by, in some instances, a 2-D echocardiography and/or exercise stress testing can identify additional patients with acute coronary syndrome. Such a unit may also ensure more appropriate inhospital chest pain admissions and less inadvertent discharges.
4. Any combination of the above three.

Regardless of which method is used, early recognition of acute myocardial infarction and early attendance of the patient by an adequately equipped medical team will go a long way towards minimising delay in response to an event of sudden cardiac arrest.

Close monitoring

The early hours of an acute myocardial infarction are associated with a relatively high incidence of serious, life-threatening arrhythmias, such as ventricular tachycardia (VT) and ventricular fibrillation (VF)[4], which are eminently treatable. However, continuous ECG monitoring is required for immediate detection of such arrhythmias. In addition, such patients, if still at the Emergency Department, should be in the resuscitation area where all supplies and equipment for resuscitation are close at hand and can be brought to bear on the patient within a few seconds. Even if the patient is being transported to the Coronary Care Unit, continuous ECG monitoring together with the relevant equipment and supplies for at least the first few minutes of any resuscitation and personnel who are trained to initiate such a resuscitation should be part of the transport team. Such an immediate response protocol has been in place at the Singapore General Hospital for at least the last nine years. This also allows our patient's collapse to be noted immediately and appropriate resuscitative measures to be initiated.

Organisation of cardiac resuscitations

Traditionally, resuscitations have often been characterised by frenzy, chaos, loud voices, doctors and nurses rushing to and fro, and valuable minutes often lost because of inadequate supply of drugs and absence of critical equipment. All these can be avoided, as was the case in our patient, with two conditions:

1. Trained medical and nursing manpower arranged around the patient, knowing their roles and responsibilities and playing these roles. Such a team-oriented and patient-oriented organisation, as illustrated in Fig 4 can go a long way to minimising the chaos of resuscitations. Such organisation requires practice and discipline. A decisive team leader, clear instructions and all members of the team trained in their various roles are important aspects of such an organisation.
2. Resuscitative equipment and supplies all within arms reach. This is the dream of every member of any resuscitation team. Resuscitations are often characterised by nurses having to go off to obtain an equipment or a drug not available in the resuscitation trolley. Even a resuscitation trolley, by itself, poses problems. Drawers need to be opened. Floor space is taken by resuscitation trolleys, defibrillator trolleys, procedure trolleys, etc, so much so that the human members of the resuscitation team have to often work around these trolleys to function. When a portable X-ray

Fig 4 – EMERGENCY DEPARTMENT RESUSCITATION TEAM

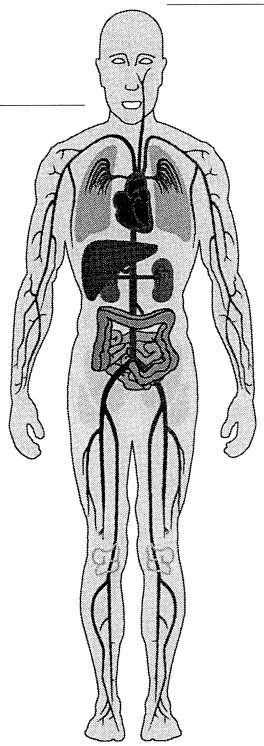

Doctor 1
- Team leader.
- Immobilises cervical spine/maintains airway/bag mask ventilation.
- Intubates patient.
- Initiates ventilation and only then hands over or converts patient to mechanical ventilator.
- Attempts exit jugular/CVP cannula, if required.
- Gives all major instructions on critical interventions, IV and medications.
- Instructs activation of inpatient specialists, if required.

Nurse 1
- Nurse in charge.
- Assists in airway management : maintains ventilation, assists in intubation and suctioning.
- Documents resuscitation record :
  events of arrest, vital signs, interventions performed.
  medications given (route & dosage)
  vital signs
  patient's condition and progress

Doctor 2
- Performs 1° survey and 2° survey.
- Initiates CPR if required.
- Performs major procedures
  eg. needle thoracotomy if required.
- Sets I/V drips and gives I/V, if D3 is not available.
- Performs all functions of D3 in absence of D3.

Nurse 2
- Assists in undressing patient.
- Performs and assists in any procedure requested by team leader eg. IV line insertion, drugs, defibrillation, catheterisation, etc.
- Facilitates procuring of required equipment and supplies.
- Ensures delivery of specimens to laboratory.
- Calls for other personnel required in resuscitation eg. specialists, radiographers etc.
- Collects patient's property.
- Accompanies patient to CT scan if required.
- Performs duites of N3 if N3 not available.

Note: If an additional doctor/nurse is available, his/her functions would be as follows:

Nurse 3
- Controls traffic flow in resuscitation room.
- Assists in CPR if needed.
- Keeps patient's family members informed at appropriate time, of events.

Doctor 3
- Sets IV drips on instructions from D1.
- Gives IV medications on instructions from D1.
- Performs DC shock/bladder catheterisation and other procedures on instructions from D1.
- Stops major external bleeds.
- Helps to undress patient.

machine is added to the list of equipment, one can imagine the crowd of inanimate objects around the collapsed patient. Fortunately, the resuscitation room at the Singapore General Hospital currently uses ceiling mounted X-rays. There is a need to arrange equipment and drugs used for resuscitation and plan a resuscitation bay where all these would be easily available, and yet valuable floor space is not used up by bulky trolleys, but instead, kept available for the personnel to use their skills on the patient to good effect.

VF protocol

Every ward/department, including an Emergency Department, should have a clear protocol for handling sudden collapses.

The initial actions in the event of a witnessed cardiac arrest may depend on whether one person or more are in the vicinity, and the ready availability of equipment.

In the event of a lone rescuer, in a monitored patient, the initial response is to look at the monitor first, and if pulseless VT or VF is present, defibrillate immediately with up to three stacked shocks of direct current beginning at 200 joules and finishing at 360 joules. A precordial thump may be given just once. Though a thump has been reported to have a variable success rate[5,6] for VT, and only rarely successful for VF[5], the American Heart Association recommends it as an optional treatment technique for witnessed cardiac arrest where a patient is breathless and a defibrillator is not immediately available[7]. Moreover, the thump can be delivered easily and quickly. It should however, never be allowed to delay electrical conversion.

Where a resuscitation team is available at the scene, the ABCs of life support go into effect immediately. One person checks responsiveness, opens the airway, assesses breathing and initiates bag-mask ventilation, while another ensures that a defibrillator is brought to the patient, confirms that the patient is in VF, applies defibrillation pads on the patient or gel to the paddles appropriately, sets the appropriate energy level and charges the defibrillator to 200 joules initially. The first shock is delivered as early as possible and if electrical conversion has not yet occurred, a second shock and then a third at 360 joules are delivered.

Since our patient was in persistent VF, CPR was continued, endotracheal intubation was carried out and 100% oxygen administered. An intravenous line had already been established prior to the collapse, and 10 mL of 1:10,000 intravenous adrenaline was given. After a further half minute of CPR, the patient was shocked twice at 360 joules with no effect. It would also have been fair to have given further doses of adrenaline or even higher doses up to 3 mg or 5 mg as recommended in Advanced Cardiac Life Support Protocols.

Although these protocols recommend an array of other drugs, such as those given for the patient described to be followed by further direct current shocks at 360 joules, an often asked question is "How many shocks is enough" or "When do we stop resuscitation in persistent VF". It would appear reasonable to administer as many shocks as necessary to terminate the arrhythmia. There is currently no more effective alternative method of terminating VF or pulseless VT. Rational thinking would also tell us that while the resuscitation of such patients is in progress, one would need to ensure the following:

a. Is CPR adequately administered?
b. Is the airway adequate? Are both lungs being adequately ventilated with 100% oxygen?
c. Have pharmacologic agents been adequately administered?
d. Is the patient likely to have electrolyte abnormalities, such as occasional hyperkalemia? If so, treatment with calcium chloride and sodium bicarbonate may be required.
e. Is low magnesium suspected? – In which case a bolus dose of I/V magnesium sulphate 1 to 2 gm over 1 to 2 minutes may be useful.

We are not sure which of the pharmacological agents administered was most instrumental in decreasing the defibrillation threshold of the patient which resulted in him responding to the ninth shock. We wish to emphasise that no effort should be spared to ensure that all procedures carried out are done as correctly as possible to maximise efficiency, myocardial salvage and patient survival.

CONCLUSION

Resuscitation of collapsed cardiac patients is often a not-too-successful affair. In this paper we have offered reasons as to why such resuscitations have not been too successful. Hospitals, and especially Emergency Departments which encounter such situations daily, have to pay attention to factors that compromise survival rates in their cardiac arrest patients. Very early recognition of acute cardiac problems, adequate monitoring, team and equipment organisation of cardiac resuscitations, and strict adherence to protocols for management of the wide variety of cardiac emergencies encountered should all contribute towards ensuring more survivals and happier outcomes. We like to believe that our patient survived to be discharged from hospital neurologically intact in spite of nine defibrillations, primarily because most of the positive factors described were brought into play.

REFERENCES

1. Kember RE et al. Guidelines for cardiopulmonary resuscitation and emergency cardiac care: Recommendations of the 1992 American Heart Association National Conference, JAMA, 1992; 268:2184-5.
2. Cummins RO (ed). Textbook of advance cardiac life support. USA: WB Saunders American Heart Association.
3. Gibler WB, Aufderheide TP. Emergency Cardiac Care. Mosby, 1994:140-68.

4. Pantridge JF, Webb SW, Adgay AAJ, et al. The first hour after the onset of acute myocardial infarction. In: Yu PN, Guedwin JF, eds. Progress in Cardiology. Philadelphia Pennsylvania: Lea & Febiger 1975:173-88.
5. Caldwell G, Millar G, Quinn E, Vincent R, Chamberlain DA. Simple mechanical methods for cardioversion: defence of the precordial thump and cough version. Br Med J 1985; 291:627-30.
6. Miller J, Tresch D, Horwitz L, Thompson BM, Aprahamian C, Darin JC. The Precordial Thump. Ann Emerg Med 1984; 13:791-4.
7. Kerber RE et al. Guidelines for cardiopulmonary resuscitation and emergency cardiac care: Recommendations of the 1992 American Heart Association National Conference. JAMA 1992; 268:2213.