

Excimer Laser Photorefractive Keratectomy for the Correction of Myopia

T L Wee, W K Chan, P Tseng, D Tan, V Balakrishnan, C H Low

ABSTRACT

Aim of Study: To ascertain the efficacy, predictability, safety and stability of photorefractive keratectomy (PRK) for the correction of myopia.

Methods: Nine-hundred and seventy-one eyes of 628 patients had PRK performed for the correction of myopia. The mean pre-operative myopia was $-5.7D \pm 2.21D$ (range $-1.0D$ to $-15.25D$). The mean attempted correction was $-5.0D \pm 1.9D$ (range $-1.0D$ to $-9.90D$).

Results: Four-hundred and sixty-seven eyes had a follow-up of 6 months or more. Ninety-three percent of low myopic eyes (pre-operative myopia of less than or equal to 6.0D) and 75% of high myopic eyes (pre-operative myopia of more than 6.0D) attained an unaided visual acuity of 6/12 or better. Seventy-four percent of low myopic and 50% of high myopic eyes were within 1D of the intended correction. The mean post-operative refraction at 6 months was $0.60D \pm 1.46D$. Eight eyes in the high myopia group and 1 eye in the low myope group lost 2 or more lines or best-corrected visual acuity.

Conclusion: PRK was safer and produced better results for low myopes.

Keywords: excimer, laser, photorefractive keratectomy, myopia

INTRODUCTION

Excimer laser photorefractive keratectomy (PRK) for the correction of myopia has been available in Singapore since January 1992. As of September 1995, a total of 971 eyes of 628 patients have had excimer PRK performed for myopia at the Singapore National Eye Centre.

PRK uses a 193nm Argon-Fluoride excimer laser to perform photoablation of corneal stroma. Photoablation of the central cornea results in its flattening and thus reducing the refractive power of the eye⁽¹⁾.

Preliminary reports of eyes with short-term follow-up have indicated that PRK is effective for the correction of myopia⁽²⁻⁴⁾. This paper reports the efficacy, predictability, stability and safety of PRK in eyes with 6 months or more of post-operative follow-up.

PATIENTS AND METHODS

Study design

This study was a prospective, non-randomised open-ended clinical trial carried out at the Singapore National Eye Centre. It was approved by the Medical Board and monitored by the SNEC Excimer Laser Committee.

Patients

Nine-hundred and seventy-one eyes of 628 patients had PRK following informed consent. Five-hundred and forty-six patients (87%) were Chinese, 26 (4%) Malays, 27 (4%) Indians and 29 (5%) were of other races. Fifty-two percent of the patients were females. The median age was 31 years.

Four-hundred and sixty-seven eyes had a follow-up period of 6 months or more and are reported in this paper.

The low myope group of up to 6D of pre-operative myopia consisted of 296 eyes (63%) while the remaining 171 eyes (37%) had pre-operative myopia more than 6D of spherical equivalent. The mean pre-PRK spherical equivalent was $-5.7D \pm 2.21D$ (range $-1.0D$ to $-15.25D$). The mean correction attempted was $-5.0D \pm 1.9D$ (range $-1.0D$ to $-9.90D$).

Inclusion criteria were: 1) age 21 or older; 2) best corrected visual acuity of 6/9 or better in both eyes with stable refraction; 3) astigmatism of less than $-1.50D$.

Exclusion criteria were: 1) progressive myopia; 2) keratoconus; 3) active or residual ocular or systemic disease that would influence corneal healing; 4) any corneal scarring, irregular astigmatism or corneal neovascularisation within 1 mm of intended ablation zone.

Pre-operative procedure

The excimer laser used was a 193-nm Argon-Fluoride excimer laser (ExciMed UV 200LA, Summit Technology, Inc., Waltham, Mass). A PRK beam test was performed prior to the first case of the day as per the manufacturer's instructions. The laser was set for an ablation zone of 5.0-mm, ablation rate of 0.25 micrometer/pulse, repetition rate of 10 Hz, fluence of 180 mJ/cm² and programmed with the dioptres of intended correction.

Pre-operative examinations included: 1) detailed

Department of
Ophthalmology
National University Hospital
5 Lower Kent Ridge Road
Singapore 119074

T L Wee, FRCSE
Registrar

V Balakrishnan, FRCSE
Consultant

Singapore National Eye
Centre
11 Third Hospital Ave
Singapore 168751

W K Chan, FRCSE
Consultant

P Tseng, FRCSG
Senior Consultant

D Tan, FRCSE
Senior Consultant

C H Low, FRCSE
Visiting Senior Consultant

Correspondence to:
Dr T L Wee

ophthalmic and systemic history; 2) uncorrected and best corrected visual acuity; 3) refraction; 4) slitlamp biomicroscopy; 5) keratometry; 6) tonometry; 7) dilated retinal examination; 8) computerised videokeratography (Corneal Mapping System, EyeSys Technologies, Houston, Texas).

Patients on contact lenses were asked to remove them at least 2 weeks prior to the pre-operative examination.

Operative procedure

Pilocarpine 1% was instilled into the eye to be treated 30 minutes prior to the onset of the laser procedure. Amethocaine 0.5% eyedrops was instilled for topical anaesthesia. Two patient training sessions were then performed to confirm patient fixation, once with methylcellulose and once on bare epithelium. The corneal epithelium over the entrance pupil was then mechanically removed. The cornea was cleaned with cellulose sponges and the laser applied according to the parameters set.

At the end of the procedure, a combination of eye tobramycin and dexamethasone ointment was applied and the eye patched.

Post-operative procedure

Each patient was seen on the first post-operative day and daily until the cornea achieved complete epithelialisation. Subsequently, the patient was seen at regular intervals. An ointment consisting of a combination of tobramycin and dexamethasone was applied five times a day till re-epithelialisation. After complete re-epithelialisation, fluoromethalone 1% eyedrops was applied five times a day until one month post-operatively. Thereafter fluoromethalone 0.1% was applied four times daily until 2 months post-operatively, decreasing by one drop per day per month until 4 months post-operatively. The use of steroid drops was titrated against corneal haze and refractive changes. The aim was to discontinue steroid drops in a gradual manner between 4 and 6 months post-operatively.

Post-operative examinations included the following: 1) unaided visual acuity; 2) refraction; 3) slitlamp biomicroscopy including assessment of corneal clarity, and 4) tonometry.

RESULTS

Four-hundred and sixty-seven eyes reached 6 months or more of follow-up and are reported.

Visual acuity

Pre-operatively, only 5 eyes from the low myope group had an unaided visual acuity of 6/12 or better (Fig 1). At 6 months post-PRK, 87% of all eyes achieved 6/12 or better of unaided visual acuity. In the low myope group, 93% achieved this result. In the high myope group, 75% of eyes attained this result (Fig 2). Four hundred and forty eyes (94%) gained 2 or more lines of unaided visual acuity (Fig 3).

Refraction

The mean pre-operative refraction of all eyes was $-5.66D \pm 2.21D$ (range $-1.0D$ to $-15.25D$). Their mean post-operative refraction at 6 months was $0.60D \pm 1.46D$. Mean pre-operative refraction for the low myopes was $-4.36D \pm 1.13D$ (range -1.13 to $-6D$) while the mean post-operative refraction for these eyes at 6 months follow-up was $0.34D \pm 1.05D$. The mean pre-operative refraction for high myopes was $-7.95D \pm 1.74D$ (range -6.13 to $-15.25D$). The mean 6 months post-operative refraction for this group was $1.06D \pm 1.91D$.

Predictability

Sixty-five percent of eyes had a final refraction within 1D of the intended correction. Seventy-four percent and 50% of the eyes in the low myope group and in the high myope group respectively achieved this result (Figs 4 and 5).

Stability

Refraction appears to be stable from 3 months onwards for the low myopes where the eyes have an average fluctuation in refraction of less than 1D. The high myope group exhibited a slightly larger variation in refraction of up to about 1.25D (Fig 6).

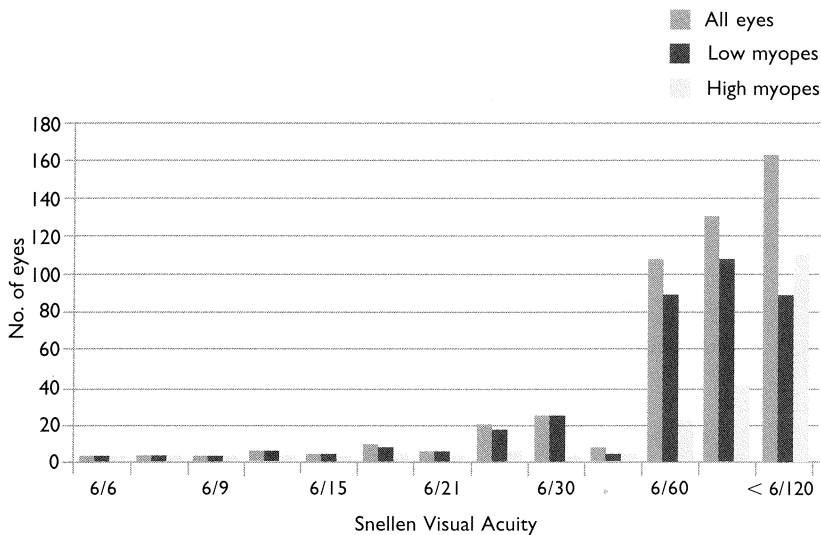


Fig 1 - Pre-operative unaided visual acuity.

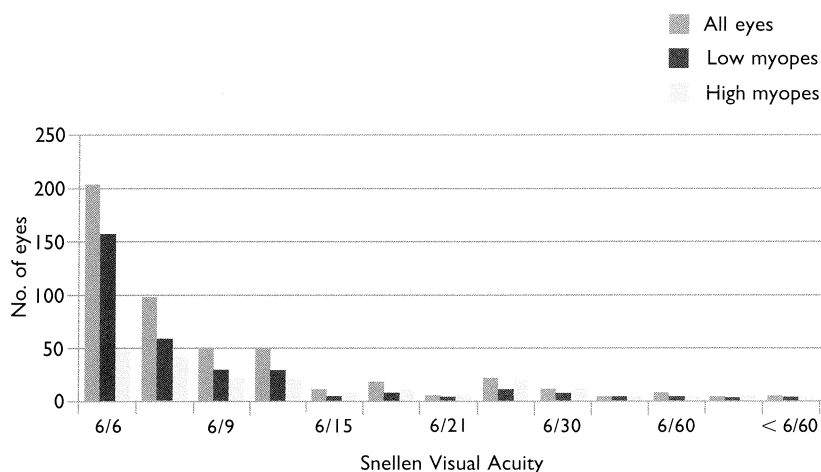


Fig 2 - Post-operative unaided visual acuity.

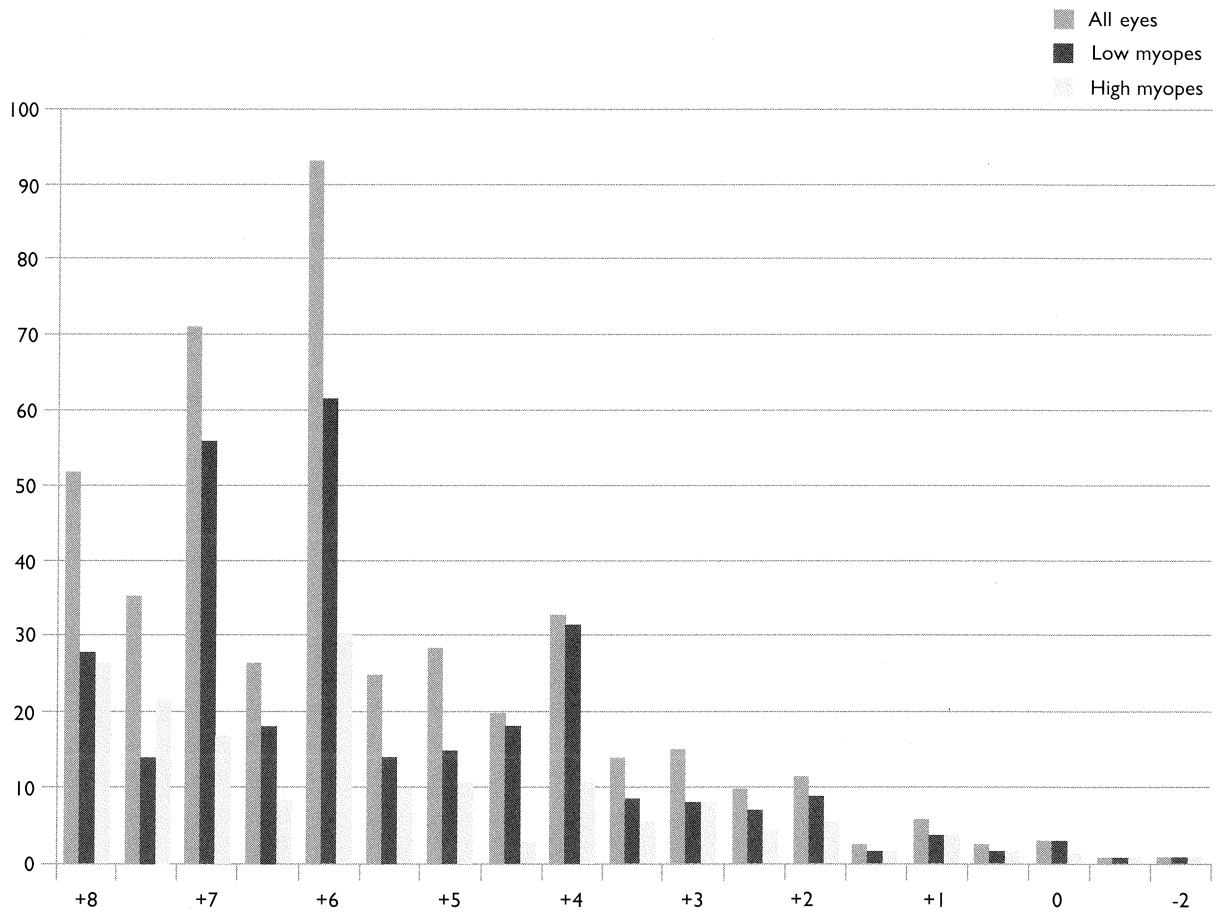


Fig 3 – Gain and loss of unaided Snellen lines post-PRK

At 6 months post-PRK, 97% of all eyes, comprising 97% of low myopic eyes and 97% of high myopic eyes gained 2 or more Snellen lines of unaided visual acuity. Four eyes, 3 from the low myope group and 1 from the high myope group had no change in their unaided Snellen visual acuity. No eyes lost any Snellen lines of unaided visual acuity.

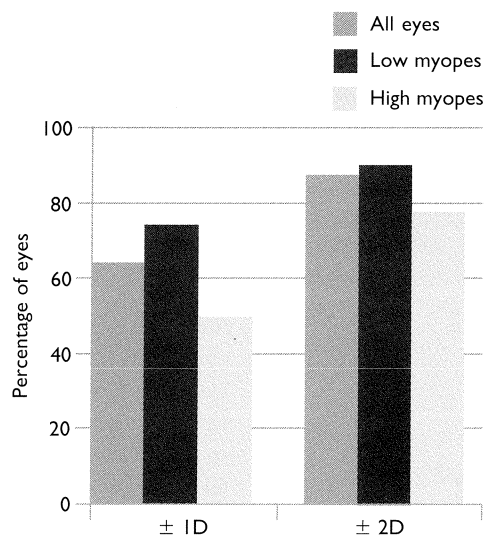


Fig 4 – Percentage of eyes within 1D and 2D of intended correction following PRK

Sixty-five percent of all eyes were within 1D of the intended correction. Eighty-eight percent of all eyes were with 2D of the intended correction.

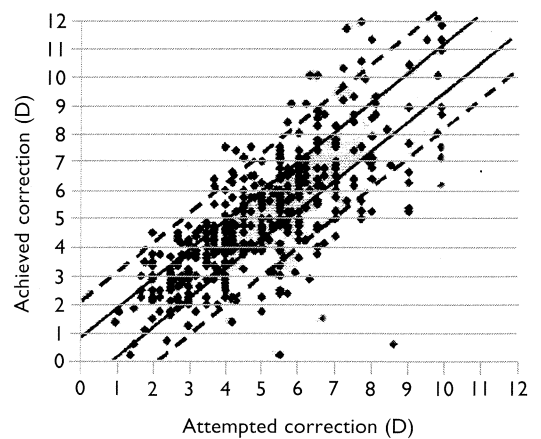


Fig 5 – Achieved versus Attempted correction for all eyes.

The points within the solid lines and dashed lines represent eyes within 1D and 2D of the intended correction respectively.

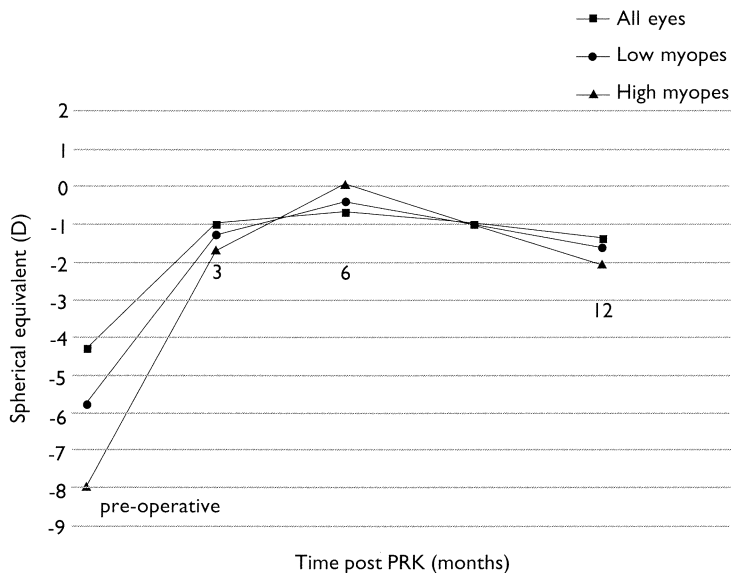


Fig 6 – Stability of refraction.

The refraction in low myopes is stable by 3 months. The high myope group demonstrates greater fluctuation in refraction up to 1 year.

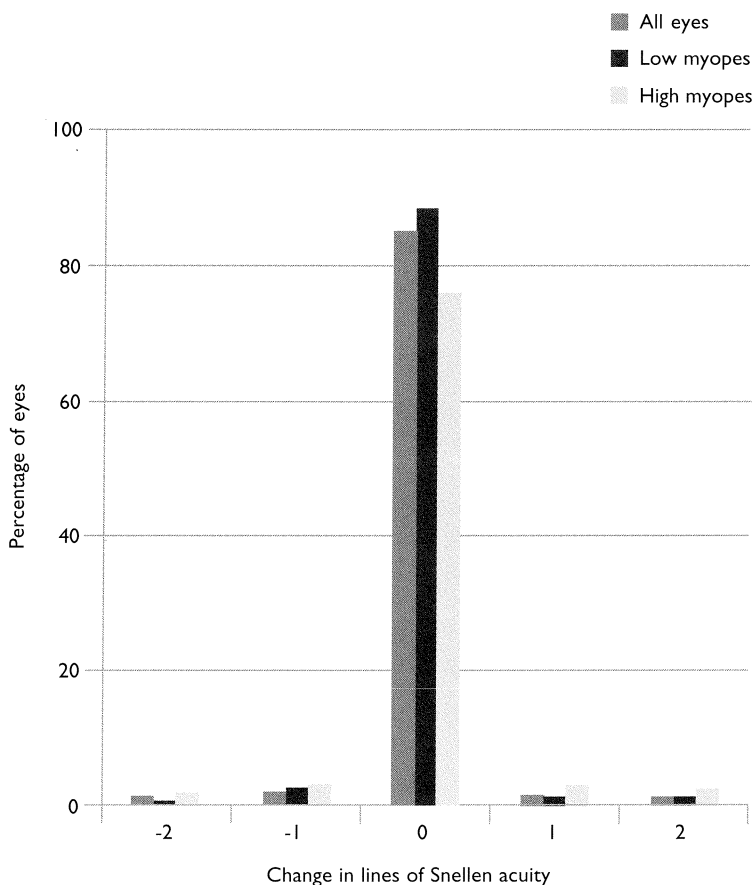


Fig 7 – Change of best-corrected visual acuity.

The majority of eyes had no change in their best-corrected visual acuity 6 months after PRK.

Complications

Loss of best-corrected visual acuity

Ninety-six percent of the low myopes and 88% of the high myopes had either no change or had an improvement in their best-corrected visual acuity. Nine eyes (0.02%) lost 2 or more Snellen lines of best-corrected visual acuity, of which 4 improved to their original best-corrected visual acuity at 12 months follow-up (Fig 7). These eyes lost vision due to corneal haze.

Corneal clarity

At 6 months post-PRK, 89% of eyes had clear corneas. 8.2%, 1.6% and 0.8% of eyes had mild, moderate and severe haze respectively. Ninety-three percent of low myopic eyes and 82% of high myopic eyes had clear corneas after PRK.

DISCUSSION

Photorefractive keratectomy is one of the newest modalities for the treatment of myopia. Previous surgical attempts at the correction of myopia have included radial keratotomy⁽⁵⁾, keratomileusis⁽⁶⁾ and epikeratophakia⁽⁷⁾. Excimer laser used has significant advantages over other previous refractive surgical methods in that it ablates with a high degree of precision with practically no collateral damage. Computer generated algorithms relating the diameter and depth of ablation needed for a given refractive change were devised based on the amount of corneal tissue that needs to be removed per pulse.

In order for a surgical treatment modality for the correction of myopia to gain widespread acceptance, it must be effective, predictable, stable and safe.

Our results have shown that at 6 months, 87% of 467 eyes had an unaided visual acuity of 6/12 or better which is the legal requirement to drive a motor vehicle in Singapore. This result is better in the low myopes where 93% of eyes attained that level of unaided visual acuity. Balakrishnan⁽²⁾, Salz⁽³⁾ and Tengroth⁽⁴⁾ reported 94%, 88% and 91% respectively. Eyes with more than 6D of myopia had a slightly poorer result with 75% attaining 6/12 or better. Chan⁽⁸⁾ reported 75% of his series of high myopic eyes attaining this target. This was most likely related to a more aggressive wound healing response and consequent regression of myopia following a greater depth of ablation required for the correction of these high myopes. In addition, these eyes had more corneal haze compared to their low myopic counterparts. This was also probably related to the greater depth of ablation. In our series, 65% of all eyes were within 1 dioptr of intended correction. Seventy-four percent of our low myopic eyes met this objective. Balakrishnan⁽²⁾ reported 84% in his series, Salz⁽³⁾ and Tengroth⁽⁴⁾ 86%. Fifty percent of our high myopic eyes achieved a refraction of within 1D of the intended correction at 6 months, compared to 34% by Chan⁽⁸⁾ and 20% by Gartry⁽⁹⁾. Sher⁽¹⁰⁾ reported 69% of his high myopic eyes within 2D of intended correction at 6 months.

Nine eyes (0.02%) in our study had loss of best-corrected visual acuity of 2 or more Snellen's lines at 6 months. This compares favourably to reports from Seiler⁽¹¹⁾ and Kim⁽¹²⁾ who reported 1.2% and 0.3% respectively. All of our eyes lost best-corrected visual acuity due to corneal haze. The best-corrected visual acuity of 4 of these eyes improved to their original acuity by 1 year. Eight of these 9 eyes belonged to the high myopia group, which tends to have greater haze as discussed earlier. Ninety-three percent and 82% of the low and high myopic eyes had clear corneas at 6 months. This compares favourably with the results of Kim⁽¹²⁾.

CONCLUSION

PRK is a promising modality for the surgical correction of low myopes. The results for high myopes were poorer mainly as a result of visually significant corneal haze. For high myopes, newer treatment modalities like laser in-situ keratomileusis (LASIK) may offer better results⁽¹³⁾.

REFERENCES

1. Trokel SL, Srinivasan R, Baren B. Excimer laser surgery of the cornea. *Am J Ophthalmol* 1983; 96:710-5.
2. Balakrishnan V, Lim AS, Low CH, et al. Excimer laser photorefractive keratectomy in Singapore: a new treatment modality for myopia. *Singapore Med J* 1993; 34:309-12.
3. Salz JJ, Maguen E, Nesburn AB, et al. A two-year experience with the excimer laser photorefractive keratectomy for myopia. *Ophthalmology* 1993; 100:873-82.
4. Tengroth B, Fegerholm P, Hamberg-Nystrom H, Fitzsimmons TD. Excimer laser photorefractive keratectomy for myopia. Clinical results in sighted eyes. *Ophthalmology* 1997; 99:1209-19.
5. Waring GO III, Lynn MJ, Nizam A, et al. Results of the Prospective evaluation of radial keratotomomy (PERK) study five years after surgery. *Ophthalmology* 1991; 98:1164-76.
6. Barraquer JI. Keratomileusis for myopia and aphakia. *Ophthalmology* 1981; 88:701.
7. McDonald MB, et al. The nationwide study of epikeratophakia for myopia. *Am J Ophthalmol* 1987; 103:375.
8. Chan WK, Heng WJ, Tseng P, Balakrishnan V, Chan TK, Low CH. Photorefractive keratectomy for myopia of 6 to 12 dioptres. *J Refract Surg* 1995 (Suppl); 11: S286-S292.
9. Gartry DS, Muir MGK, Marshall J. Excimer laser photorefractive keratectomy, 18-month follow-up. *Ophthalmology* 1992; 99(8):1209-19.
10. Sher NA, Barak M, Daya S, et al. Excimer laser PRK in high myopia. A multicenter trial. *Arch Ophthalmol* 1992; 110:935-43.
11. Seiler T, Holschbach A, Derse M, Jean B, Genth U. Complications of myopic photorefractive keratectomy with the excimer laser. *Ophthalmology* 1994; 101:153-60.
12. Kim JH, Hahn TW, Lee YC. Some problems after photorefractive keratectomy. *J Refract Corneal Surg* 1994; 10 (suppl):S226-S230.
13. Salah T, Waring GO III, Maghraby AE, Moadel K, Grimm SB. Excimer laser in situ keratomileusis under a corneal flap for myopia of 2 to 20 dioptres. *Am J Ophthalmol* 1996; 121:143-55.