

A Review of 5 Years' Experience in the Use of Botulinum Toxin A in the Treatment of Sixth Cranial Nerve Palsy at the Singapore National Eye Centre

B L Quah, Y L F Ling, P Y Y Cheong, V Balakrishnan

ABSTRACT

Introduction: This retrospective study reports our experience on the use of botulinum toxin A (BTXA) in the treatment of sixth cranial nerve palsy at the Singapore National Eye Centre. BTXA is derived from clostridium botulinum; it causes temporary paralysis of the extraocular muscle (medial rectus) into which it is injected, thus preventing its contracture and allows the antagonist lateral rectus muscle to take up the slack and reduce or correct the ocular misalignment.

Methods: Nineteen patients had BTXA injection for esotropia due to sixth cranial nerve palsy during the period September 1992 to August 1997. The sixth cranial nerve palsy was related to nasopharyngeal carcinoma in 76.7% of cases. Follow-up after the last injection ranged from zero (defaulted) to 21 months (mean 8, median 6 months).

Results: A total of 25 injections were given to 19 patients. Seven patients (36.8%) had final ocular alignment within 10 prism dioptres of orthotropia of which six achieved fusion at primary gaze position. There was no correlation between the number of injections per patient and the size of strabismus or grade of lateral rectus muscle function. The incidence of ptosis was 48%, subconjunctival haemorrhage 16% and hypertropia 16%.

Discussion: Our results suggest that those patients with smaller strabismus and a shorter time interval between onset of strabismus and botulinum injection tend to achieve better outcome in terms of fusion or ocular alignment within 10 prism dioptres of orthotropia. The treatment of strabismus with BTXA is an acceptable approach in selected patients. The procedure is simple, safe, cheap, effective, and avoids the risks of general anaesthesia. It can substitute for or eliminate the need for strabismus surgery in some cases of sixth nerve palsy.

Keywords: botulinum toxin A, sixth cranial nerve palsy, esotropia, nasopharyngeal carcinoma, ptosis

INTRODUCTION

Botulinum toxin A (BTXA) was first used in the Singapore National Eye Centre to treat strabismus in September 1992.

BTXA is derived from clostridium botulinum which is a large, anaerobic, gram positive, rod-shaped organism. It produces eight immunologically distinguishable exotoxins (A, B, C1, C2, D, E, F and G)⁽¹⁾. Three types (A, B and E) are commonly associated with toxicity to humans. In fact, botulinum toxin had been used to make weapons for biological warfare. The type A toxin is easily cultured and was the first one to be obtained in highly purified, stable and crystalline form⁽²⁾.

The clinical application of BTXA as an alternative to strabismus surgery was established in 1980 by Dr Alan B Scott⁽³⁾. The kinetics of botulinum A toxin uptake at the nerve terminal involves 3 steps: binding, internalisation, and paralysis. BTXA binds to the presynaptic nerve terminal of the striated muscle into which it is injected, and after internalisation, prevents quantal acetylcholine release causing flaccid paralysis of the muscle⁽⁴⁾. The paralytic effect of botulinum toxin is dose-related, peaking at 5 to 7 days after injection. The muscle gradually recovers normal activity as new neuromuscular junctions are formed by sprouting from presynaptic axons over 6 – 8 weeks⁽⁵⁾. Ocular alignment can thus be altered by injecting appropriate amounts of BTXA under local anaesthesia directly into the extraocular muscles to cause transient paralysis. As an example, in lateral rectus palsy, weakness of abduction in the affected eye and overaction of the ipsilateral antagonist medial rectus muscle results in esotropia; BTXA is injected into the medial rectus muscle which becomes slightly atrophied and stretched while the antagonist paretic lateral muscle takes up the slack thereby reducing the ocular misalignment. If binocular functions are re-established when the eyes are realigned, as the treated muscle recovers function, the incomitant strabismus may not recur⁽⁶⁾.

One unit of botulinum toxin (about 0.25 nanograms) is the lethal dose for 50% (LD/50) of mice. The LD/50 for humans is estimated at about 39 units/kg^(7,8). Antibodies to the toxin have not been detected in patients given small doses for ocular use, so repeat injections can be given when necessary.

Indications for the use of botulinum toxin injection to treat strabismus include:

1. Recent loss of binocular function eg. paralytic

Singapore National
Eye Centre
11 Third Hospital Ave
Singapore 168751

B L Quah, MMed (Ophth),
FRCS (Edin)
Senior Registrar

Y L F Ling, FRCS (Edin),
FRCOphth
Consultant

P Y Y Cheong, FRCS (Edin),
FRCOphth
Visiting Consultant

V Balakrishnan, MMed
(Ophth), FRCS (Edin),
FRCOphth
Consultant and
Medical Director

Correspondence to:
Dr B L Quah

- strabismus, myositis, dysthyroid strabismus
- 2. Surgically over- or undercorrected strabismus
- 3. Sensory deviation
- 4. Postretinal detachment surgery strabismus
- 5. Patients who are unwilling or unfit to undergo surgery

The advantages of BTXA injections are: ease of administration (it can be performed in the clinic under topical anaesthesia), little or no postoperative discomfort, absence of scar as there is no incision. The disadvantages are that it requires repeated injections in 60% of the cases despite which results may still be impermanent⁽⁷⁾. Ocular misalignment tends to recur more easily after BTXA injection than after surgery if fusion is not established. The spread of the toxin to the extraocular muscles after injection may have side-effects such as ptosis and vertical eye deviations. In contrast, strabismus surgery can achieve a satisfactory result in 70% – 90% of cases with one operation^(9,10).

We report a retrospective study on the indications for and outcome of the use of botulinum toxin A in the treatment of sixth cranial nerve palsy at the Singapore National Eye Centre over a 5-year period from September 1992 to August 1997.

METHODS

Nineteen patients had BTXA injection for esotropia due to 6th cranial nerve palsy during the period September 1992 to August 1997. The male: female ratio was 2.8:1 and the age ranged from 15 to 78 years (mean 47.8, median 46 years). Sixteen patients had unilateral and 3 patients had bilateral 6th cranial nerve palsy. The most common cause of 6th cranial nerve palsy in our patient series was nasopharyngeal carcinoma (76.7%) (Table I). Follow-up after last injection ranged from zero (defaulted follow-up after botulinum injection) to 21 months (mean 8, median 6 months). The primary deviation of the strabismus was measured using the prism cover test or the krimsky method if the former was not possible. Esotropia on distance fixation ranged from 12 to more than 154 prism dioptres, median 45 prism dioptres.

Extraocular muscle function was graded as follows:

- 0 = Normal duction
- 1 = Can rotate eye from midline to 75% of full rotation
- 2 = Can rotate eye from midline to 50% of full rotation
- 3 = Can rotate eye from midline to 25% of full rotation
- 4 = No movement past midline
- 5 = Cannot rotate eye from opposite field to midline

The mean grade of lateral rectus function in our patients was - 3, range - 0.5 to - 5.

The technique of BTXA injection for strabismus was as follows: BTXA was administered with a 27-gauge monopolar electrode needle (Fig 1) on a 1.0 cc tuberculin syringe containing 0.1 mL of toxin. The needle shaft was insulated so the needle recorded signals received only from the tip. The monopolar electrode tip was inserted into the extraocular muscle transconjunctivally (Fig 2) and transmitted the electromyographic response of the muscle to an amplifier (Fig 3). The amplifier magnified the electrical

Table I – Cause of sixth cranial nerve palsy

Diagnosis	No.
Nasopharyngeal carcinoma (NPC)	14
Ischaemia	2
Cerebrovascular accident	1
Head injury from road traffic accident	1
Intracranial thrombophlebitis	1

impulses and made them audible through the unit's speaker. Prior to the insertion, topical proparacaine or amethocaine was instilled in the eye. The patient was asked to gaze in the direction away from the muscle to be injected so that the surgeon could insert the needle into the extraocular muscle. The patient was then asked to turn the eye toward the muscle being injected which activated the motor units of the muscle. As the needle was guided into the muscle, the EMG sound of the muscle activity increased until the needle reached the largest part of the muscle. The sound assisted the surgeon by assuring that the tip of the needle was in the correct position in the muscle. BTXA was injected into the muscle when the EMG sound reached its peak.




Fig 1 – 27-gauge monopolar electrode needle.



Fig 2 – Administration of BTXA.

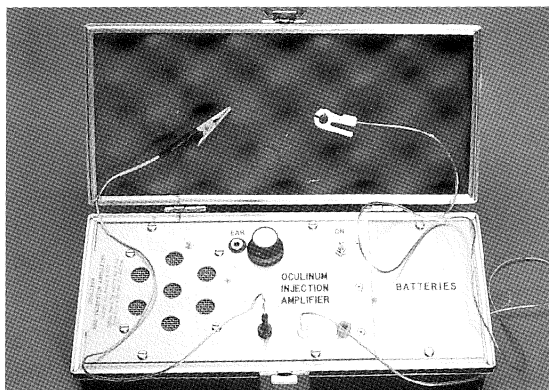


Fig 3 – Amplifier.

Table II – Characteristics of patients who achieved final ocular alignment within 10 prism dioptres of orthotropia

Patient no.	Diagnosis	Initial deviation (prism dioptres)	Grade of lateral rectus function	No. of injections and dose	Time taken to achieve alignment	Fusion	Follow-up
4	Bilateral 6th nerve palsy, ischaemia	20	- 0.5	1 (5 U)	1 month	Yes	15 months
5	Unilateral 6th nerve palsy, ischaemia	30	- 0.5	1 (5 U)	4 months	Yes	20 months
6	Unilateral 6th nerve palsy, NPC	30	- 3	1 (5 U)	8 months	No	8 months
8	Unilateral 6th nerve palsy, NPC	No record	- 4	1 (5 U)	10 months	Yes	21 months
11	Unilateral 6th nerve palsy, cerebrovascular accident	No record	- 3	1 (2.5 U)	6 months	Yes	6 months
12	Unilateral 6th nerve palsy, NPC	12	- 0.5	2 (2.5, 5 U)	4 days	Yes	12 months
16	Unilateral 6th nerve palsy, intracranial thrombophlebitis	16	- 0.5	1 (5 U)	1 month	Yes	7 months

Table III – Characteristics of patients with residual strabismus greater than 10 prism dioptres

Patient no.	Diagnosis	Initial deviation (prism dioptres)	Grade of muscle function	No. of injections and dose	Follow-up	Eventual strabismus surgery
2	Unilateral 6th nerve palsy, NPC	50	- 5	1 (5 U)	5 months	No
3	Bilateral 6th nerve palsy, NPC	> 133	- 4	3 (2.5, 5 U)	1 month	No
7	Unilateral 6th nerve palsy, NPC	55	- 4	1 (5 U)	4 months	Yes
14	Unilateral 6th nerve palsy, NPC	45	- 4	1 (5 U)	6 months	No
20	Unilateral 6th nerve palsy, NPC	35	- 1	2 (2.5, 1.25 U)	9 months	Yes

The dose of BTXA injected ranged from 1.25 to 5.0 units, most had either 2.5 or 5.0 units. BTXA was injected into the ipsilateral medial rectus muscle. Two patients with bilateral palsies had BTXA injected into both medial rectus muscles.

RESULTS

A total of 25 injections were given to our series of 19 patients. The number of injections per patient ranged from 1 to 3 (mean 1.3, median 1). Of the 19 patients who had BTXA injections, 7 (36.8%) achieved final ocular alignment within 10 prism dioptres of orthotropia. Six of these patients had one injection and one patient had two injections. The time interval between the onset of strabismus and BTXA injection in these seven patients ranged from 2 months to 2 years (mean 10.3, median 7 months). The time taken to achieve ocular alignment within 10 prism dioptres of orthotropia ranged from 4 days to 10 months after the last injection. Follow-up after last injection ranged from 6 to 21 months. All of them achieved fusion at primary gaze position except for one patient (Table II).

Of the remaining 12 patients who were not documented as having achieved ocular alignment

within 10 prism dioptres of orthotropia, 4 defaulted follow-up, 2 did not have records of orthoptic measurement in their casenotes and one patient had recurrence of nasopharyngeal carcinoma with further cranial nerve palsies. The characteristics of the remaining 5 patients are shown in Table III. The time interval between the onset of strabismus and BTXA injection in these five patients ranged from 5 months to 10 years (mean 46 months, median 42 months).

There was no correlation between the number of injections per patient and the magnitude of initial deviation or grade of lateral rectus muscle function in the 19 patients.

In our series of 25 injections, there were 12 occurrences (48%) of ptosis, 4 cases (16%) of subconjunctival haemorrhage and 4 cases (16%) of hypertropia. Most cases of ptosis were mild and recovered within one to six months. The subconjunctival haemorrhages were all mild and resolved spontaneously within weeks. The four patients who developed hypertropia in the eye with BTXA injection had an average vertical deviation of 20 prism dioptres; the progress or resolution of hypertropia was not documented in the casenotes. None of the patients had globe penetration or systemic complications from BTXA injection.

DISCUSSION

It is generally agreed that BTXA injection may be effective in sixth nerve palsy^(9,11-14). Contracture of the antagonist medial rectus muscle can be avoided by BTXA injection into the muscle. The injection can also balance the paralysis and straighten the eye to correct primary gaze diplopia. Even in permanent 6th nerve palsy where muscle transposition surgery is necessary, BTXA injection of the medial rectus may improve the surgical result by reducing the contracture of the adductor muscle. Recession of the medial rectus muscle may even be avoided, thus reducing the risk of anterior segment ischaemia^(9,13,15).

Generally, a sixth nerve palsy due to a vascular lesion, such as diabetes mellitus, hypertension, or atherosclerosis, tends to recover spontaneously and does not require BTXA injection^(16,17). However Eustis and Parks⁽¹⁸⁾ showed that newly acquired constant strabismus can result in irreversible loss of binocular single vision after a period of 2 to 3 months. Injection during the acute period, even in patients expected to recover lateral rectus function, might help to prevent this occurrence. In cases of chronic total sixth nerve palsy, BTXA injection alone is ineffective in correcting the ocular misalignment because of the shortening and stiffness of the antagonist medial rectus muscle⁽¹³⁾.

Patients with sixth nerve palsy who may benefit from BTXA injection are those having bothersome diplopia requiring strong prisms, an abnormal head posture or even occlusion of the eye with consequent reduction of visual field and cosmetic defect. In these patients, BTXA injection for temporary effect is especially appropriate if the palsy is expected to resolve slowly either in part or full, or if they are unwilling or unfit to undergo surgery or when the palsy is caused by an inoperable lesion. The vast majority of our patients had sixth cranial nerve palsy from nasopharyngeal carcinoma. BTXA injection is especially appropriate in improving the cosmetic appearance of these patients as it is less invasive compared to surgery. These patients may have corneal hypoesthesia from concomitant fifth cranial nerve lesion, and dry eyes and impaired anterior segment vascular supply due to radiotherapy. Strabismus surgery may further compromise the anterior segment vascular supply and affect the tear film of the eye, thus aggravating the pre-existing ocular complications of nasopharyngeal carcinoma, not to mention the general anaesthesia risks involved in performing surgery on this group of patients.

Our results suggest that those patients with smaller strabismus and a shorter time interval between onset of strabismus and botulinum injection tend to achieve better outcome in terms of fusion or ocular alignment within 10 prism dioptres of orthotropia (normal alignment of the visual axes of both eyes) (Tables II and III).

The most common side effects of BTXA injection are ptosis and hyperdeviation. Scott reported in 1989 that ptosis was found in 16% of adults and 25% of children after BTXA injection of horizontal muscles⁽⁷⁾. In our series of 25 injections, the incidence of ptosis was 48%. The

levator muscle is extremely sensitive to even small amounts of botulinum toxin and ptosis has been reported to occur even after injection of BTXA into the inferior rectus muscle⁽¹⁹⁾. To reduce the incidence of ptosis, we advised the patients to sit up immediately after the injections and remain in an upright position for that evening⁽²⁰⁾. This is believed to prevent the spread of toxin to the levator muscle.

The incidence of hypertropia was 16% in our series which is comparable to another study which found vertical deviation in 17% of patients, with 2% having vertical strabismus of two or more prism dioptres for six months or more⁽⁷⁾. This is a problem in patients with fusion as diplopia may be bothersome. Furthermore, the vertical deviation may prevent fusion and result in a recurrence of the initially corrected horizontal deviation⁽¹⁴⁾. None of our patients had scleral perforation which had a reported incidence of 0.11%⁽⁷⁾. Local subconjunctival haemorrhage occurred in four of our patients but was not a problem.

Patients with the best results after injection often have an initial overcorrection of the strabismus. They must be warned that diplopia may accompany this temporary overcorrection and last for several weeks. Patients must also be told that the effect of the toxin may not be permanent and that the strabismus may not be totally corrected and may require additional injections or strabismus surgery.

The treatment of strabismus with BTXA is an acceptable approach in selected patients. The procedure is simple, safe, cheap, effective, and avoids the risks of general anaesthesia. It can substitute for or eliminate the need for strabismus surgery in some cases of sixth nerve palsy.

REFERENCES

1. Melling J, Hambleton P, Shone CG. Clostridium botulinum toxins: nature and preparation for clinical use. *Eye* 1988; 2:16-23.
2. Schantz EJ, Scott AB. Use of crystalline type A botulinum toxin in medical research, in Lewis GE (ed): *Biomedical aspects of botulinum*. New York, Academic press, 1981:143-9.
3. Scott AB. Botulinum toxin injection into extraocular muscles as an alternative to strabismus surgery. *J Pediatr Ophthalmol Strabismus* 1980; 17:21-5.
4. Dolly JO, Black J, Williams RS, Melling J. Acceptors for botulinum toxin reside on motor nerve terminals and mediate its internalization. *Nature* 1984; 307:457-60.
5. Duchon LW. An Electron microscopic study of the changes induced by botulinum neurotoxin in the motor endplates of slow and fast muscle fibres of the mouse. *J Neurol Sci* 1979; 14:47-60.
6. Elston JS, Lee JP, Powell CM, Hogg C, Clark P. Treatment of strabismus in adults with botulinum toxin A. *Br J Ophthalmol* 1985; 69:718-24.
7. Scott AB. Botulinum toxin treatment of strabismus. *Focal points 1989: Clinical Modules for Ophthalmologists* 7:1-11. San Francisco, Am Acad Ophthalmology.
8. Scott AB. Botulinum treatment for blepharospasm, in Smith BC (ed): *Ophthalmic Plastic and Reconstructive Surgery, Vol 1*. St Louis, CV Mosby, 1987:609-13.
9. Magoon EH. The use of botulinum toxin injection as an alternative to strabismus surgery. *Contemp Ophthalmic Forum* 1987; 5:222-9.

10. Magoon EH. Botulinum chemodenervation for strabismus and other disorders. *Int Ophthalmol Clin* 1986; 25:149-59.
11. Biglan AW, Burnstine RA, Rogers GL, Saunders RA. Management of strabismus with botulinum A toxin. *Ophthalmol* 1989; 96:935-43.
12. Gammon JA, Gemmil M, Tigges J, Lerman S. Botulinum chemodenervation treatment of strabismus. *J Pediatr Ophthalmol Strabismus* 1985; 22:221-6.
13. Scott AB, Kraft SP. Botulinum toxin injection in the management of lateral rectus paresis. *Ophthalmol* 1985; 92:676-83.
14. Wagner RS, Frohman LP. Longterm results: Botulinum for sixth nerve palsy. *J Pediatr Ophthalmol Strabismus* 1989; 20:106-8.
15. Rosenbaum AL, Kushner BJ, Kirschen D. Vertical rectus muscle transposition and botulinum (Oculinum) to medial rectus for abducens palsy. *Arch Ophthalmol* 1989; 107:820-3.
16. Moster ML, Savino PJ, Sergott RC, et al. Isolated sixth nerve palsies in younger adults. *Arch Ophthalmol* 1984; 102:1328-30.
17. Rush JA, Younge BR. Paralysis of cranial nerve III, IV, and VI. *Arch Ophthalmol* 1981; 99:76-9.
18. Eustis HS, Parks MM. Acquired monofixation syndrome. *J Pediatr Ophthalmol Strabismus* 1989; 26:169.
19. Magoon E, Dakoske C. Botulinum toxin injection for vertical strabismus. *Am Orthoptic J* 1985; 35:48-52.
20. Stavis M. Ptosis: A preventable side effect following botulinum injection for anterior strabismus. *Am Orthoptic J* 1985; 35:53-5.