

# Enzymatic Dissolution of Post-Operative Haemothorax by Purified Streptokinase

E K W Sim, S K Sim, M L Wong, C N Lee, W X Chan

## ABSTRACT

Enzymatic dissolution of haemothorax is highly effective in the evacuation of proteinaceous material from the pleural space. Its use in post-cardiotomy haemothorax has not been described. We report the case of a 4-year-old girl with Fallot's Tetralogy diagnosed at birth. She underwent a total correction of Fallot's Tetralogy at 4 years of age. Chest X-ray taken post-operatively showed a large pleural collection in her right haemithorax. Repeated intrapleural infusion of purified streptokinase into the right upper pleural chest tube greatly reduced the extent of the right haemothorax. Enzymatic dissolution of haemothorax by purified streptokinase has proven to be a rapid and successful method of therapy. It has provided an alternative which is less invasive and has a low morbidity.

**Keywords:** haemothorax, streptokinase, cardiac surgery, congenital heart disease, Fallot's Tetralogy

## INTRODUCTION

A post-operative clotted haemothorax following cardiac surgery is an infrequent complication which, when diagnosed, necessitates early evacuation to avoid development into fibrothorax or empyema<sup>(1,2)</sup>.

An alternative to thoracotomy for evacuation of the haemothorax is to inject intrapleural streptokinase. We describe a patient who developed a clotted right haemothorax after repair of Fallot's Tetralogy. Intrapleural injection of purified streptokinase resulted in successful resolution of the haemothorax.

## CASE REPORT

A 4-year-old Chinese girl, with Fallot's Tetralogy diagnosed at birth, had 2 previous modified Blalock-Taussig shunts at 6 weeks and 21 months of life respectively. She had total correction of Fallot's Tetralogy with take-down of Blalock-Taussig shunts at 4 years of age. Post-operatively, she was stable haemodynamically but chest X-ray of the patient 12 hours later showed a large pleural collection in the upper zone of the right haemithorax (Fig 1). It contained pockets of air and was of similar attenuation

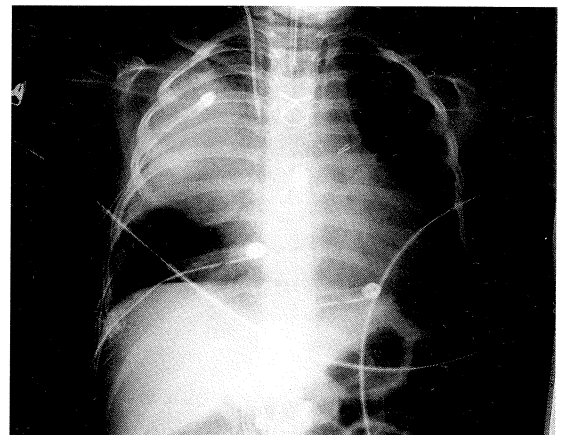


Fig 1 - Post-operative pulmonary artery chest X-ray showing extensive right haemothorax around the site of the right pulmonary artery repair.

to soft tissue (78 Hounsfield units) and represented a loculated haemothorax. Chest tube thoracostomy drainage was performed and although the chest tube was in a good position, the haemothorax was still not resolved over the next two days.

On the third post-operative day, purified streptokinase 50,000 U in 20 mL saline was injected into the right upper pleural chest tube and the tube was clamped for 4 hours. A total of 120 mL was drained over the next 20 hours. The procedure was completed uneventfully. After the drainage, radiographic results showed the right haemothorax significantly smaller compared to the previous findings. The patient developed low-grade fever which subsided after 12 hours. Repeat intrapleural infusion of purified streptokinase was done with a smaller dosage of 25,000 U in 10 mL saline. On the fifth post-operative day, the procedure was repeated following which, 113 mL of heavy bloodstained fluid was drained. Chest X-ray taken after the procedure showed that the extent of the right haemothorax had diminished markedly (Fig 2).

## DISCUSSION

Enzymatic dissolution of haemothorax is far less invasive compared to rib-resection or thoracotomy, but it is often overlooked as an option for fear of inducing a recurrent bleed (especially in the early

Division of Cardiothoracic  
Surgery  
National University Hospital  
5 Lower Kent Ridge Road  
Singapore 119074

E K W Sim, MBBS,  
FRCS (Edin, Glas), FAMS  
Head and Consultant

6 Napier Road  
#04-12/13  
Gleaneagles Medical Centre  
Singapore 258499

C N Lee, FRCS  
Cardiothoracic Surgeon

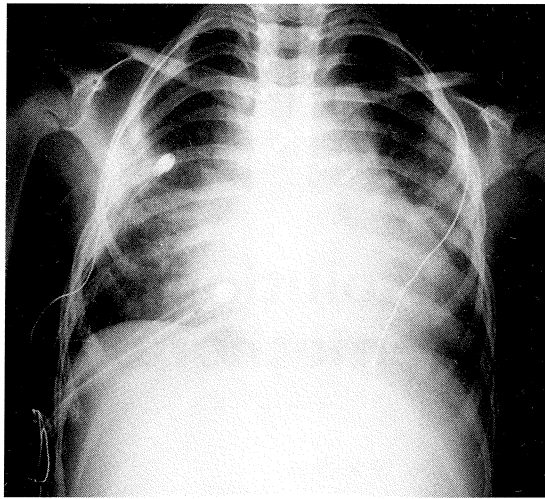
W X Chan  
Research Assistant

Department of Paediatrics  
National University Hospital

S K Sim, MMed (Paeds)  
Senior Registrar

M L Wong, MMed (Paeds)  
Consultant

Correspondence to:  
A/Prof E K W Sim



**Fig 2** – Chest X-ray taken after intrapleural of streptokinase showing marked improvement of the right haemothorax.

post-operative period) and side effects, such as fever, allergic reactions and prolongation of bleeding<sup>(1,3)</sup>. Aye and colleagues<sup>(4)</sup> reported 14 patients ranging in age from 24 to 82 years who underwent intrapleural streptokinase therapy for unresolved pleural space collections. Thirteen of the 14 patients (93%) had successful evacuation of pleural space collections. There was no significant complications associated with the use of streptokinase, proving enzymatic dissolution to be a safe and effective means of evacuation in haemothorax. It is an especially useful adjunct to tube thoracostomy and may decrease the need for more invasive procedures.

The goal of therapy in haemothorax is the evacuation of offending material to permit clinical resolution. Chest tube drainage is usually the first resort. If haemothorax persists and results in subsequent trapped lung, thoracotomy would be necessary. The recent usage of thoracoscopic techniques does provide a less invasive option and has a lower morbidity than thoracotomy. However, it may be inadequate in some cases when the thoracoscope view is not optimal.

Enzymatic dissolution has produced spectacular results in many cases and has proven itself to be highly effective in the evacuation of proteinaceous material from the pleural space. The method provides the least invasive option and the response is rapid in successful cases. However, if failure to respond to streptokinase injections occur, operative interventions should be proceeded without further delay.

Side effects in streptokinase use are minimal. In our patient, there were no side effects; the low-grade fever was due to lower right exit wound infection. Streptokinase is known to cause cerebrovascular accidents when injected intravascularly. However, the dosage used in this form of therapy is very small. Moreover, streptokinase is not absorbed across the pleura significantly<sup>(5)</sup>.

Enzymatic dissolution of haemothorax by purified streptokinase has provided an alternative which is less invasive and has a low morbidity. Resolution has proven to be rapid and successful by this method of therapy. Removal of material that would be too viscous or particulate to be removed by tube drainage alone is effectively enhanced. Purified streptokinase when used as an adjunct to tube thoracostomy is an effective therapy for evacuation of haemothorax at an early stage. This would greatly reduce the chances for development of further complications which could result in death.

#### REFERENCES

1. Beall A, Bricker D, Crawford H, et al. Considerations in the management of penetrating thoracic trauma. *J Trauma* 1968; 8:408.
2. Milfeld D, Mattox K, Beall A. Early evacuation of clotted hemothorax. *Am J Surg* 1978; 136:686.
3. Cordice J, Cabezon J. Chest trauma with pneumothorax and hemothorax. *Chest Trauma* 1965; 50:316.
4. Aye RW, Froese DP, Hill LD. Use of purified streptokinase in empyema and hemothorax. *Am J Surg* 1991; 161:560-2.
5. Berglin E, Ekroth R, Teger-Nilsson AC, et al. Intrapleural instillation of streptokinase effects on systemic fibrinolysis. *Thorac Cardiovasc Surg* 1981; 29:124-6.