

Epidemiology, Presentation and Management of Congenital Muscular Torticollis

B C S Ho, E H Lee, K Singh

ABSTRACT

Aim of Study: Congenital muscular torticollis is a condition of debatable aetiology and management. Untreated, cervical function and facial cosmesis may be severely compromised. The aim of this study was to establish the epidemiology, presentation and management of congenital muscular torticollis in Singapore.

Patients: Ninety-one patients with torticollis were seen at the National University Hospital (NUH) from January 1994 to December 1997. Torticollis was first noted at a median age of 2 months with the median age of presentation being 6 months. At presentation, a sternomastoid tumour was noted in 33 patients and 62 patients had facial asymmetry. Thirteen of 22 patients with neonatal records available had mandibular hypoplasia at birth on the side where the sternomastoid was affected. Half of the patients (45) had a right sided lesion, with 46 being left sided. The rates of assisted breech delivery, instrumental deliveries (forceps and vacuum) and Caesarean section were higher in the study group. Nine (59.1%) of 13 patients with vertex presentation, had a lesion on the side of the presenting shoulder. Forty-eight of 72 patients responded well to therapy with improvement; 20 underwent surgery and the median age of presentation of 19.5 months in this group was significantly later than that of 4 months in the group which responded to physiotherapy alone.

Conclusion: Birth trauma appears to be the main aetiological factor in congenital muscular torticollis. Patients generally respond well to physiotherapy. This study revealed 2 findings hitherto unreported: (1) mandibular hypoplasia may be an useful early sign of this condition, and (2) the side affected may depend on the side of shoulder delivered first. More studies, however, are required to confirm these findings.

Keywords: birth trauma, mandibular hypoplasia, congenital torticollis

INTRODUCTION

Congenital muscular torticollis is an intriguing condition of unknown origin characterised by

shortening and tightness of the sternocleidomastoid muscle. Patients usually present with head tilt, facial asymmetry and plagiocephaly (Fig 1). A sternomastoid mass or tumour may or may not be clinically apparent. Untreated, cervical function and facial cosmesis may be severely compromised.

Various aetiological factors have been proposed to explain this disorder⁽¹⁾. Popular theories include birth trauma, fetal malposition in-utero, infection and ischaemia. Recently, Davids, Wenger and Mubarak, based on a combined anatomical, clinical and MRI study, postulated that muscular torticollis could be a sequelae of uterine or perinatal compartment syndrome⁽²⁾. The exact aetiology, however, remains unclear at present.

The treatment of choice in muscular torticollis is as controversial as its aetiology. While most advocate physiotherapy as the mainstay of treatment⁽³⁻⁹⁾, some feel that simple observation will suffice⁽¹⁰⁾. Surgery is usually reserved for persistent cases, the results of which are generally good^(11,12).

The aim of this study was to determine the epidemiology, presentation and management of congenital muscular torticollis in Singapore.

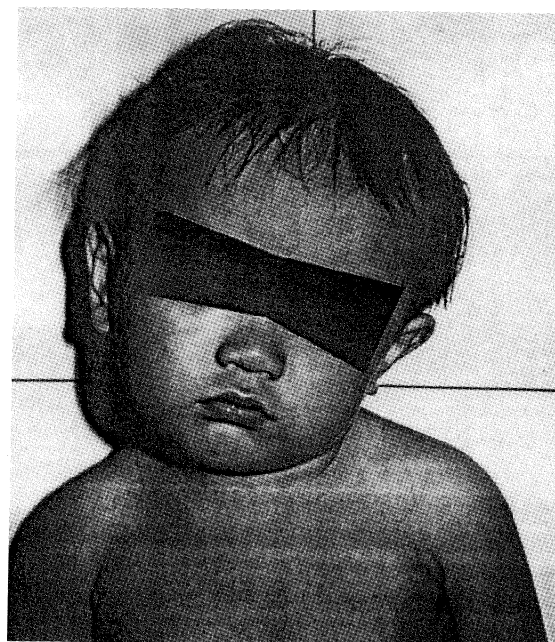

Fig 1 – Child with congenital muscular torticollis. Note the head tilt, left-sided facial asymmetry and plagiocephaly.

Department of Orthopaedic
Surgery
National University Hospital
5 Lower Kent Ridge Road
Singapore 119074

B C S Ho
5th Year Medical Student

E H Lee, MD, FRCS (C)
Professor and Head

Department of Obstetrics
and Gynaecology
National University Hospital

K Singh, MD, FRCOG,
MMed (O&G)
Associate Professor and
Senior Consultant

Correspondence to:
Prof E H Lee

METHOD

Medical records of 91 patients seen and treated at the National University Hospital (NUH) from January 1994 to December 1997 were retrospectively studied. Patients with postural torticollis, squint, cervical spine anomalies and other non-muscular causes were omitted from our study. Records were analysed for demographic features, clinical presentation, treatment and outcome.

Twenty-two neonatal and 13 obstetric records were reviewed. Neonatal records were used to assess the presence of mandibular hypoplasia at birth, detected and documented by the neonatologist. Obstetric records were studied to determine the occiput orientation at delivery in patients with vertex presentation.

Statistical analysis was performed where appropriate with Fisher's exact probability test and Wilcoxon rank sum test.

Physiotherapy involved passive neck stretching exercises performed by trained physiotherapists, and by parents at home. Patients were assessed for their response to physiotherapy in the following areas: range of neck movement, facial asymmetry, head tilt and sternomastoid tightness. Results were considered as satisfactory or unsatisfactory based on the criteria in Table I. The overall result was good when all aspects (functional and cosmetic) were satisfactory, fair when any one criterion was unsatisfactory, and poor when both cosmetic and functional aspects were unsatisfactory.

RESULTS

Demographic characteristics

There were 43 (47.3%) male and 48 (52.7%) female patients. The male to female ratio was about 1:1. The majority was Chinese (80.2%) (Table II).

The median age at presentation was 6 months (ranging from birth to 8 years). Most patients presented within the first year of life, especially in the first 6 months (Fig 2).

Table II – Demographic characteristics of patients with congenital muscular torticollis

Characteristic	No. of patients (%)
Gender : M/F	43 : 48
Race :	
Chinese	73 (80.2%)
Malay	13 (14.3%)
Indian	1 (1.1%)
Others	4 (4.4%)
Side of lesion : R/L	45 : 46
Associated disorders:	
Facial asymmetry	63 (69.2%)
Plagiocephaly	38 (41.8%)
Calcaneovalgus foot	4 (4.4%)
Recurvatum knee	1 (1.1%)
Sprengel shoulder	1 (1.1%)
Developmental dysplasia of hip	1 (1.1%)
Sternomastoid tumour : Y/N	33 : 58

Torticollis was first noted at a median age of 2 months (Fig 3). There was an average of 4 months interval between notice of torticollis and presentation. At presentation, 33 patients had a sternomastoid tumour. The median age at which the tumour was noted was 1.8 months.

Half of the patients (45) had a right sided lesion (Table II). None had bilateral involvement. In those with right sided lesions, 4 were breech delivered babies. Only one patient was delivered breech in those with left sided lesions. The ratio of right to left sided lesions in breech deliveries was 4:1. This difference was, however, not statistically significant ($p = 0.203$). None of the patients had a positive family history of congenital muscular torticollis.

The most commonly associated disorders were facial asymmetry (69.2%) and plagiocephaly (41.8%). Only one patient had developmental dysplasia of the hip (Table II).

Obstetric and birth history

There were 47 normal vaginal deliveries, 19 Caesarean sections, 11 vacuum extraction, 9 forceps and 5 breech deliveries (Table III). These figures were compared with those obtained from the Obstetric Unit at NUH over a similar period. Although only 5 breech deliveries were recorded in our series, this was about 6 times more than the expected incidence. Similarly, rates of instrumental (forceps and vacuum) deliveries and Caesarean sections were also higher than expected.

Forty-nine patients were primiparae while 32 were multiparae. The birth order in 10 patients is not known (Table IV).

Table I – Criteria for grading overall results of physiotherapy (Leung and Leung, 1987)

Criteria	Results	
	Satisfactory	Unsatisfactory
Cosmetic	Facial asymmetry absent or only apparent to examiner No head tilt No palpable tightness	Facial asymmetry obvious to parent and examiner Head tilt observed Tightness or loss of sternomastoid column
Functional	< 10 degrees limitation of rotation or side flexion	> 10 degrees limitation of rotation or side flexion

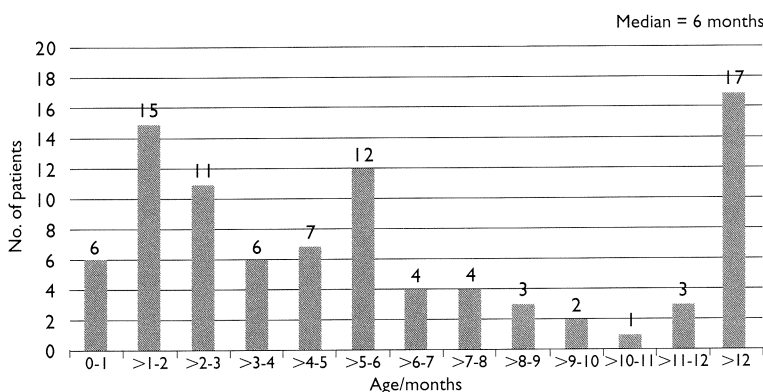


Fig 2 – Age at presentation of congenital muscular torticollis.

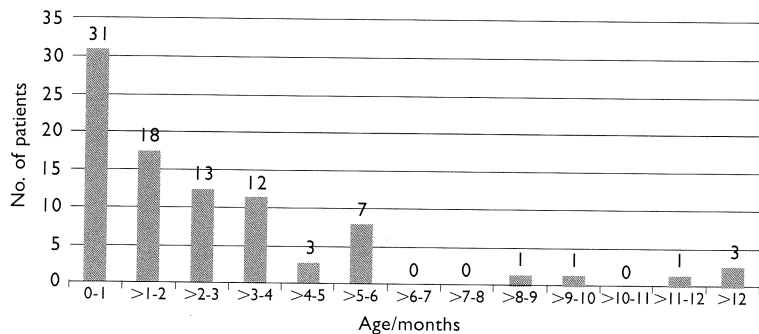


Fig 3 – Age at which muscular torticollis was first noted.

Table III – Comparison of delivery modes between patients with muscular torticollis and those of the NUH obstetric unit from 1994 – 1996

Delivery mode	No. of patients (%) (n = 91)	No. of patients (%) (n = 9837)
NVD	47 (51.6%)	7397 (75.2%)
Caesarian section	19 (20.9%)	1561 (15.9%)
Vacuum extraction	11 (12.1%)	181 (1.8%)
Forceps	9 (9.9%)	602 (6.1%)
Breech	5 (5.5%)	96 (0.9%)

Table IV – Birth order in patients with muscular torticollis

Birth order	No. of patients (%) (n = 91)
1st	49 (53.8%)
2nd	23 (25.3%)
3rd	5 (5.5%)
4th	4 (4.4%)
Unknown	10 (11.0%)

Table V – Occiput orientation of babies born in vertex position

	LOA	ROA	LOP
Right-sided torticollis	5	2	0
Left-sided torticollis	1	4	1

Obstetric records of 13 patients were available for study. All 13 were born in the vertex position; 6 were noted to be in left occiput anterior (LOA), 6 in right occiput anterior (ROA) and one in left occiput posterior (LOP) position. Five out of the 6 in an LOA position had right sided torticollis and 4 out of the 6 in an ROA position had left sided torticollis. That is, in 9 out of 13 cases (59.1%), the affected sternocleidomastoid muscle was ipsilateral to the presenting shoulder side (Table V).

Out of 22 patients whose neonatal records were available, 13 (59.1%) had mandibular hypoplasia at birth. All of them were noted on the side where the sternomastoid was affected.

Treatment

A total of 87 patients received physiotherapy; one patient was put under observation as her condition was very mild and 3 were managed surgically without prior trial of physiotherapy. The period of follow-up ranged from one month to 57 months. Seventy-two patients had adequate documentation and follow-up. Of these, the result was good in 25 (34.7%) patients, fair in 23 (31.9%) patients and poor in 24 (33.3%) patients.

Twenty patients underwent corrective surgery and the median age at operation was 3 years. Open release of the sternal and/or clavicular head of the sternomastoid muscle was performed in 17 patients. The remaining 3 had Z-lengthening of the sternal head of the sternomastoid muscle as described by Ferkel et al⁽¹³⁾. Notably, the median age at first presentation in these 20 patients was 19.5 months. This was comparably later than the group of 25 patients in whom good results were obtained with physiotherapy alone (median age at presentation was 4 months). The difference of 15.5 months was statistically significant ($p = 0.001$).

DISCUSSION

In our study, there was no gender predominance in congenital muscular torticollis. Other workers have reported similar findings^(5,11,14). Interestingly, Cheng and Au⁽⁶⁾ reported in a series of 624 patients, a male:female ratio of 3:2. Their study however, included 174 patients with postural torticollis. This group of patients was not considered in our study and may explain the discrepancy. There was no racial predilection either. Chinese constituted the majority (78%) of the population in Singapore⁽¹⁵⁾ and the high prevalence of muscular torticollis among Chinese (80.2%) in this study merely reflects this fact.

The average age at first presentation has been reported to be as early as 4.3 weeks⁽¹⁴⁾. In our study, the median age at presentation was 6 months. Despite a wide range of ages at the initial presentation (birth to 8 years), the majority of patients presented in the first year of life. These findings concur with that of Hummer and MacEwen⁽¹⁶⁾.

The median age at which torticollis was first noted was 2 months. There was an average of 4 months interval between notice of torticollis and presentation. How does one explain this delay? Parents may have thought the lesion was self-limiting and only presented when they found that the condition did not improve. Furthermore, because our hospital is a tertiary referral centre, patients may have been managed by the government polyclinic doctor or the private general practitioner before being referred to us for persistence of torticollis.

In many studies on congenital muscular torticollis, breech deliveries constitute a fairly large proportion of cases^(5,8-10,17). It must be remembered, however, that these studies were conducted as long as 20 years ago. The trend of delivery mode is changing. Recent years have seen an increase in Caesarian section rates and a significant reduction in breech deliveries. In our series,

most patients were normal vaginally delivered (51.6%). Breech deliveries made up only 5.5% of all deliveries. The rates of breech, forceps and vacuum deliveries, though relatively low, were nevertheless significantly higher than expected. This supports the role of birth trauma as an aetiological factor in muscular torticollis. About one-fifth of the patients were delivered by Caesarian section, a mode of delivery that has often been misconstrued as being non-traumatic. It is possible that birth trauma could still occur if the incision made is not large enough to facilitate easy delivery. Moreover, in many of these patients, there was a history of difficult labour and abnormal presentation, suggesting that in utero malposition of the fetus may be another contributing aetiological factor.

The preponderance of primiparae among patients with congenital muscular torticollis has been reported in various studies^(5,8). Our findings were no different. As the primiparous mother has a smaller untried uterus, abnormal positioning of the fetus is not unexpected. This points to fetal malposition as a possible causative factor of this disorder. Also, birth trauma could occur more easily in such a situation.

Many studies have reported a predominance of right sided lesions^(5,8,14,17). This was not so in our study, where the ratio of right to left sided lesions was 1:1. Ling⁽¹⁴⁾ has suggested that the discrepancy may be due to the proportion of breech deliveries in each series. In our study, there were 5 breech deliveries, of which 4 were right sided (a right to left ratio of 4:1 in breech delivered patients). We were unable to establish a significant association between right sided lesions and breech deliveries. This could, in part, have been due to the paucity of breech deliveries.

Davids, Wenger and Mubarak observed in their study of 9 babies born in the vertex position with documented LOA or LOT that 8 of them had left sided torticollis⁽²⁾. They concluded that the affected sternomastoid muscle was contralateral to the presenting shoulder side. Our experience in this study of 13 patients showed otherwise. In 9 patients, the affected sternomastoid muscle was ipsilateral to the presenting shoulder side (5 LOA with right sided lesions, and 4 ROA with left sided lesions). There was only one case of LOA associated with a left sided lesion, and 2 ROA associated with a right sided lesion. Our findings suggest that the side affected may depend on the side of shoulder that is delivered first. The delivery of the baby's shoulders involves 2 manoeuvres. Downward traction on the head is first applied to deliver the anterior or presenting shoulder, followed by upward traction to deliver the posterior shoulder. The initial downward traction, we believe, is usually the more traumatic one and may explain why the sternomastoid muscle ipsilateral to the presenting shoulder is the one more likely to be injured in the process. The implications of this finding are two: (1) it supports the theory of birth trauma as the cause of muscular torticollis in vertex presenting babies, and (2) the side of lesion may depend on

the side of shoulder delivered first. It must be emphasised that studies on larger populations are needed to confirm the findings.

There was no family history of muscular torticollis in our patients. Similarly, in Ling's⁽¹⁴⁾ patients, there was a positive family history in only 3.6% of the patients. These low figures show that this condition is probably not hereditary.

Facial asymmetry and plagiocephaly are common, though not invariable, deformities associated with congenital muscular torticollis. Both are believed to be secondary to the torticollis. Plagiocephaly, characterised by flattening of the skull on the side of the contracted sternomastoid, is caused by external pressure on the skull due to the position the child assumes when sleeping. The reported co-existence of hip dysplasias with congenital muscular torticollis varies from 0.6% to 20%^(14,15,18). Only one patient (1.1%) in our study had developmental dysplasia of the hip. Nonetheless, we believe that it is a good practice to routinely screen all patients presenting with muscular torticollis for dysplastic hips since the latter, if not treated early, may result in severe hip dysfunction and gait disturbances later on in life.

The association between mandibular hypoplasia and congenital muscular torticollis has not been reported previously. We found that 13 (nearly 60%) out of 22 patients had mandibular hypoplasia at birth. Mandibular hypoplasia may therefore be a useful early sign of muscular torticollis. Further studies are required to confirm this finding.

The optimal management of muscular torticollis has been argued for many years. Most agree that physiotherapy is the mainstay of treatment. Surgery is usually reserved for patients whose conditions are persistent or when cervical function and facial deformities become unacceptable. The majority (66.6%) of our patients responded well to physiotherapy with fair to good results. Requirement for surgery hinges on the age at presentation.

The aetiology of congenital muscular torticollis remains as elusive as it was more than one hundred years ago. The preponderance of first-borns, breech and difficult deliveries is consistent with a traumatic origin of congenital muscular torticollis. Even in cases of spontaneous vaginally delivered babies, trauma to the sternomastoid muscle may still occur based on the afore proposed mechanism. Although intrauterine malposition of the fetus may also account for this disorder, we believe that birth trauma is the main aetiological factor.

Most patients with congenital muscular torticollis present early and respond well to physiotherapy. Requirement for surgery hinges on the age of the child at the initial presentation. This study revealed two findings hitherto unreported: (1) mandibular hypoplasia may be a useful early sign of muscular torticollis, and (2) the side affected may depend on the side of shoulder delivered first. However, more studies are needed to confirm these findings.

REFERENCES

1. Lidge RT, Bechtol RC, Lambert CN. Congenital muscular torticollis-etiologic and pathology. *J Bone Joint Surg (Am)* 1957; 39:1165-82.
2. Davids JR, Wenger D, Mubarak SJ. Congenital muscular torticollis: Sequelae of intrauterine or perinatal compartment syndrome. *J Pediatr Orthop* 1993; 13:141-7.
3. Leung YK, Leung PC. The efficacy of manipulative treatment for sternomastoid tumours. *J Bone Joint Surg (Br)* 1987; 69:473-8.
4. Binder H, Eng GD, Gaiser JF, Koch B. Congenital muscular torticollis: results of conservative management with long-term follow-up in 85 cases. *Arch Phys Med Rehabil* 1987; 68:222-5.
5. Ling CM, Low YS. Sternomastoid tumour and muscular torticollis. *Clin Orthop* 1972; 86:144-50.
6. Cheng JCY, Au AWY. Infantile torticollis: a review of 624 cases. *J Pediatr Orthop* 1994; 14:802-8.
7. Canale ST, Griffin DW, Hubbard CN. Congenital muscular torticollis. *J Bone Joint Surg (Am)* 1982; 64:810-6.
8. MacDonald D. Sternomastoid tumour and muscular torticollis. *J Bone Joint Surg (Br)* 1969; 51:432-43.
9. Hulbert KF. Congenital torticollis. *J Bone Joint Surg (Br)* 1950; 32:50-9.
10. Coventry MB, Harris L. Congenital muscular torticollis in infancy. Some observations regarding treatment. *J Bone Joint Surg (Am)* 1959; 41:815-22.
11. Ippolito E, Tudisco C, Massobrio M. Long-term results of open sternocleidomastoid tenotomy for idiopathic muscular torticollis. *J Bone Joint Surg (Am)* 1985; 67:30-8.
12. Ling CM. The influence of age on the results of open sternomastoid tenotomy in muscular torticollis. *Clin Orthop* 1976; 116:142-8.
13. Ferkel RD, Westin GW, Dawson EG, Oppenheim WL. Muscular torticollis: a modified surgical approach. *J Bone Joint Surg (Am)* 1983; 65:894-900.
14. Ling CM, Balachandran N. A prospective study of sternomastoid tumour in a closed community. *Proceedings of the Tenth Singapore-Malaysia Congress of Medicine* 1975; 10:233-6.
15. Ministry of Health, Singapore. Annual Report, 1993.
16. Hummer CD Jr, MacEwen GD. The coexistence of torticollis and congenital dysplasia of the hip. *J Bone Joint Surg (Am)* 1972; 54:1255-6.
17. Chandler FA, Altenberg A. "Congenital" muscular torticollis. *JAMA* 1944; 125:476-83.
18. Weiner DS. Congenital dislocation of the hip associated with congenital muscular torticollis. *Clin Orthop* 1976; 121:163-5.