

Porphyria Cutanea Tarda

B P Khoo, Y K Tay

ABSTRACT

Porphyrias are a group of rare metabolic disorders in which excessive quantities of porphyrins, or their precursors, are produced. They are due to specific enzyme deficiencies resulting in abnormalities in the control of the porphyrin-haem metabolic pathway. Porphyria cutanea tarda (PCT) is the most common of all the porphyrias. However this condition is rarely seen in our Asian countries.

We describe a patient with PCT who presented clinically with blistering eruptions over the sun-exposed areas. Coral pink fluorescence of uroporphyrins in an acidified urine specimen is diagnostic. Definitive treatment involves the use of low-dose chloroquine and interval venesection.

Keywords: Sun exposure, Skin fragility, Hyperpigmentation, Liver dysfunction, Uroporphyrin

Singapore Med J 2000 Vol 41(6):292-294

INTRODUCTION

Hematorporphyria chronica was originally described by Gunther⁽¹⁾ as a syndrome of skin lesions and darkly coloured urine occurring later in life than either congenital or acute porphyrias, without the attacks of abdominal pain or neurologic dysfunction. It was later named as porphyria cutanea tarda (PCT) by Waldenström⁽²⁾ in 1937. This disease occurs universally⁽³⁾ and is the most common porphyria.

CASE REPORT

A 57-year-old Chinese woman presented with blisters on both hands of 5 days' duration. She gave an account of skin fragility and blister formation for the past several years over these sites including the nose. There was no other significant medical history except for her diabetes mellitus for which she was on long-term glibenclamide and metformin.

Physical examination revealed 2 tense bullae over the left thenar eminence and dorsum of right hand. There were a few old ulcerations with surrounding

scar tissue formation over the dorsum of left hand. She had a slate-grey hyperpigmentation over the face with mild facial hypertrichosis, and a single erosion was noted on the nose (Fig. 1). Her initial diagnosis was that of bullous pemphigoid, a common blistering disorder for her age group.

Initial investigations including full blood count, eosinophil count, anti-nuclear antibodies and urine microscopy were essentially normal or negative except for mild glycosuria.

A punch biopsy specimen was then taken from the left hand. The haematoxylin-eosin stained sections showed a re-epithelialized subepidermal blister with a mild interstitial lymphocytic infiltrate in the upper dermis. There were no eosinophils or neutrophilic aggregates seen. Direct immunofluorescence showed non-specific speckled deposits of C3 at the dermoepidermal junction and in the walls of a few superficial dermal blood vessels.

On further investigation, she was discovered to have a positive urine porphyrin (Fig. 2). Blood porphyrin and stool porphyrin were however not detected. Further sections of the skin specimen were stained for periodic acid-Schiff (PAS) and these showed cuffs of PAS positive material around the small vessel walls in the dermal papillae and upper dermis (Fig. 3). Other tests to investigate for underlying disorders including the ultrasonography of the hepatobiliary system, hepatitis screen, serum liver function test were

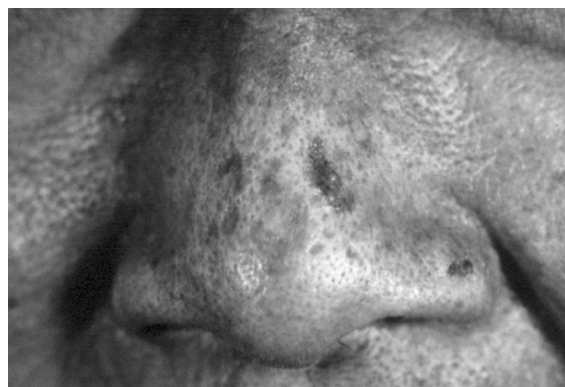

Fig. 1 Denuded blisters on the nose.

Raffles Surgicentre
182 Clemenceau
Avenue
Singapore 239923

B P Khoo, MBBS,
MRCP (UK),
FAMS
Consultant

National Skin
Centre
1 Mandalay Road
Singapore 308205

Y K Tay, MBBS,
MMed (Int Med),
MRCP (UK),
MRCP (I), FAMS
Consultant

Correspondence to:
Dr B P Khoo

essentially normal except for a raised gammaGTP at 139 U/l.

Our patient however defaulted follow up subsequently.

DISCUSSION

The porphyrias are currently defined according to clinical features and the porphyrin pattern in the blood, urine and faeces.

PCT occurs mainly in middle-aged adults and there is no racial predilection. It is usually classified as acquired (type I) or hereditary (type II) inherited as an autosomal dominant trait, with the former making up 80% of all PCT patients⁽⁴⁾.

The metabolic abnormality is a reduction in hepatic uroporphyrinogen (URO) decarboxylase activity⁽⁵⁾. In acquired PCT, URO decarboxylase is deficient only in the liver but not in RBC⁽⁶⁾, whereas in hereditary PCT, URO decarboxylase is decreased by 50% in all tissues⁽⁷⁾. Porphyrins which are accumulated in the skin are readily excited by light of 400 nm wavelength. Absorption of light energy results in production of free oxygen radicals which damage the skin⁽⁸⁾. Common precipitating agents that are believed to inhibit URO decarboxylase include alcohol, estrogens, hexachlorobenzene, iron, chlorinated phenols and tetrachlorodibenzo-p-dioxin.

Patients typically present with fragile skin over sun-exposed areas. Vesicles and bullae occur predominantly on the dorsum of hands, forearms and face after minor trauma. Scarring and milia formation may ensue. Other features include hyper and hypopigmentation, plaques of pseudoscleroderma and facial hypertrichosis.

PCT-like syndromes are occasionally associated with hepatic tumours⁽⁹⁾, hepatitis⁽¹⁰⁾, and lupus erythematosus⁽¹¹⁾. Other reported associations include Sjogren's syndrome⁽¹²⁾, sarcoidosis⁽¹³⁾ and HIV infection⁽¹⁴⁾.

The diagnosis is confirmed by the presence of a coral pink fluorescence of uroporphyrins in an acidified urine specimen when examined under Wood's lamp (Fig. 2). If the urine fluorescent test is negative, it is then essential to perform quantitative 24-hour urine uroporphyrin and coproporphyrin (COPRO) tests in which the ratio of URO:COPRO will be more than 3:1, whereas the ratio is less than 1:1 in variegated porphyria (VP).

PCT differs from VP and acute intermittent porphyria (AIP) in that PCT patients do not have acute attacks of abdominal pain, peripheral neuropathy and respiratory failure. Other important differential diagnoses to consider are epidermolysis bullosa acquisita and drug-induced photosensitivity.

General management would include the avoidance

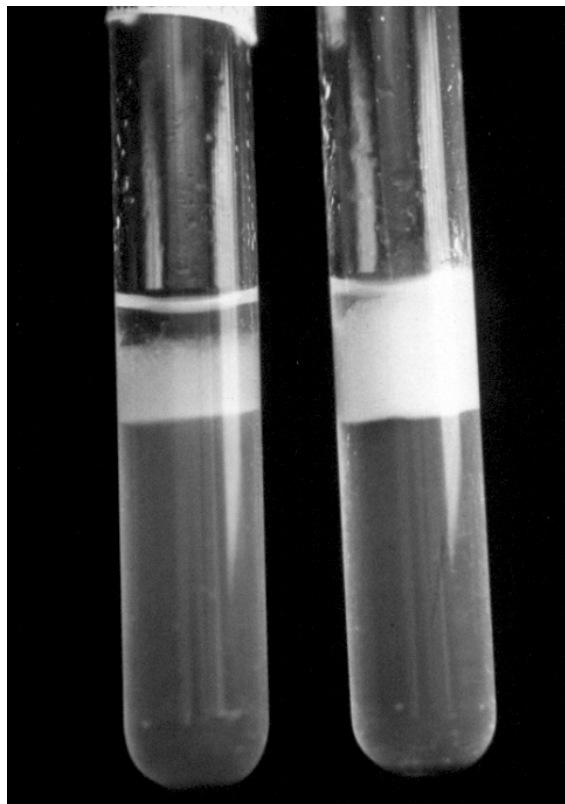


Fig. 2 Coral pink fluorescence of uroporphyrins under Woods' lamp (right tube) compared to control urine specimen (left tube).

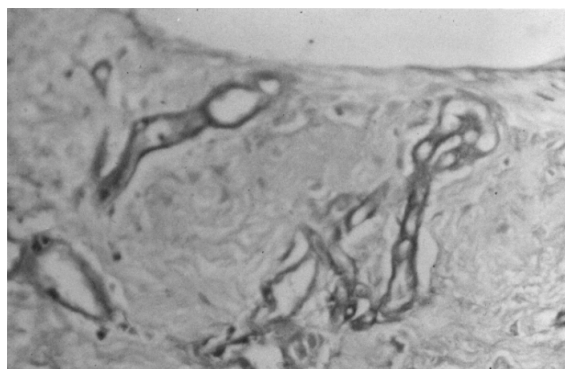


Fig. 3 Histological section (PAS stain) shows PAS positive material deposited around blood vessels.

of precipitating agents and sun exposure.

Definitive treatment consists of venesection which is the treatment of choice. 500 ml of blood are removed at fortnightly intervals until the haemoglobin level falls to 10 g/dl. For patients whom venesection is contraindicated, low-dose chloroquine (125 mg) twice weekly may be useful although its exact mechanism is not known. Caution has to be taken as higher doses of chloroquine may paradoxically exacerbate PCT symptoms and produce hepatotoxicity. Combination of an initial few sessions of venesection followed by low-dose chloroquine is advocated by some authorities.

In summary, most cases of PCT present themselves to the internist or the gastroenterologist because of

liver-related signs and symptoms. But they may first present as a photodermatitis to the dermatologist occasionally. Therefore it is important not to miss out on this rare disease after having excluded the more common blistering disorders.

REFERENCES

1. Gunther I. Die harnatoporphyrie. *Dtsch Arch Kim Med* 1911; 105:89.
2. Waldenstrom J. Studien uber Porphyrie. *Acta Med Scand (suppl)* 1937; 82:1.
3. Elder GH. The cutaneous porphyrias. *Semin Dermatol* 1990; 9:63-9.
4. Elder GH. Porphyria cutanea tarda: a multifactorial disease. In: Champion RH, Pye RJ, editor. *Recent Advances in Dermatology*. Vol 8. Edinburgh: Churchill Livingstone, 1990; 55-69.
5. Felsher BF, Carpio NM, Engleking DW, Nunn AT. Decreased hepatic uroporphyrinogen decarboxylase activity in porphyria cutanea tarda. *N Engl J Med* 1982; 306:766-9.
6. Elder GH, Lee GB, Tovey JA. Decreased activity of hepatic uroporphyrinogen decarboxylase in sporadic porphyria cutanea tarda. *N Engl J Med* 1978; 299:274-8.
7. Benedetto AV, Kushner JP, Taylor JS. Porphyria cutanea tarda in three generations of a single family. *N Engl J Med* 1978; 298:358-62.
8. Spikes JD. Porphyrins and related compounds as photodynamic sensitizers. *Ann NY Acad Sci* 1975; 244:496-508.
9. Solis JA, Betancor P, Campos R, Enriquez de Salamanca RE. Association of porphyria cutanea tarda and primary liver cancer. Report of ten cases. *J Dermatol* 1982; 9:131-137.
10. Coburn PR, Coleman JC, Cream JJ, Hawk JL, Lamb SG, Murray Lyon IM. Porphyria cutanea tarda and porphyria variegata unmasked by viral hepatitis. *Clin Exp Dermatol* 1985; 10:169-73.
11. Clemmensen O, Thomsen K. Porphyria cutanea tarda and systemic lupus erythematosus. *Arch Dermatol* 1982; 118:160-2.
12. Ramasamy R, Kubik MM. Porphyria cutanea tarda in association with Sjogren's syndrome. *Practitioner* 1982; 226:1297-8.
13. Mann RJ, Harinan RR. Porphyria cutanea tarda and sarcoidosis. *Clin Exp Dermatol* 1982; 7:619-23.
14. Wissel PS, Sordillo P, Anderson KE, Sassa S, Savillo RL, Kappas A. Porphyria cutanea tarda associated with the acquired immune deficiency syndrome. *Am J Hematol* 1987; 5:107-13.