

# Focal Nodular Hyperplasia: An Unusual Liver Mass in a Paediatric Patient

E L H J Teo, H K Ang, N T Ong, A P A Tan Kendrick

## ABSTRACT

We report an unusual case of focal nodular hyperplasia (FNH) occurring in a 19-month-old female without a typical central fibrous scar. Ultrasound demonstrated a solid, hypoechoic, highly vascular mass situated in the left lobe of the liver. Computed tomography showed a solid mass with no evidence of a central fibrous scar. A hepatic angiogram demonstrated enlarged right and left hepatic arteries supplying the vascular tumour, with early venous drainage into the inferior vena cava; a feature which has not been previously described. Surgical resection was carried out and a solid, nodular tumour measuring 9 x 4 x 4 cm was removed. The diagnosis of FNH was made histologically. The characteristic imaging findings of FNH will be discussed and a review of the literature of FNH in children will be presented.

**Keywords:** Focal nodular hyperplasia, benign, liver tumour, paediatric patients

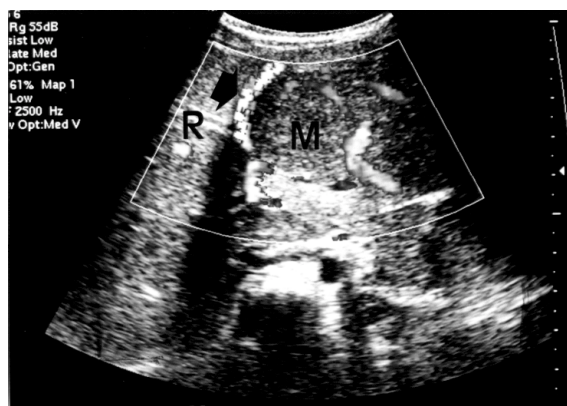*Singapore Med J 2000 Vol 41(7):352-355*

## CASE REPORT

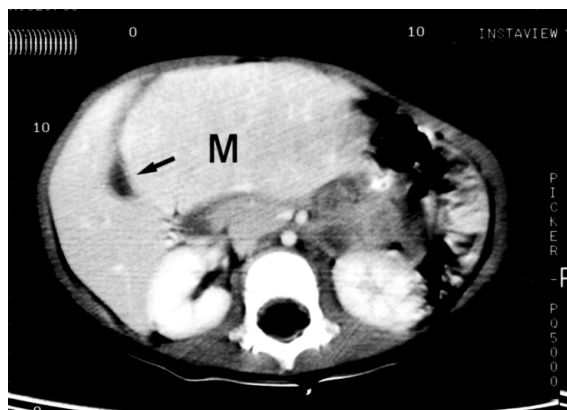
A 19-month-old female was referred to our institution from the outpatient services for the evaluation of an epigastric mass. The patient's mother discovered the mass approximately two weeks prior to admission. The patient was otherwise asymptomatic. The mass was constant in size over this period of time. The child was born prematurely at 33 weeks of gestation. She experienced a short episode of hypoglycaemia from which she fully recovered. There were no other neonatal complications. On physical examination, a firm mass occupying the epigastric region was palpable up to 5 cm below the xiphisternum. No bruits were heard over the mass. The patient was not jaundiced and there were no signs of chronic liver disease or cardiac failure. Liver function tests were normal. Alpha-fetoprotein was 2.0 UG/L (normal range 1-10 UG/L). Hepatitis B surface antigen was negative. 24-hour urine catecholamine excretion values were within normal limits. An

ultrasound scan demonstrated a solid, hypoechoic mass situated in the medial and lateral segments of the left lobe of the liver. Colour Doppler sonographic evaluation showed the mass to be very vascular with increased blood flow in the coeliac axis and hepatic artery, both of which were enlarged. The hepatic veins, main and right portal veins were normal but the left portal vein was displaced anteriorly around the tumour (Fig. 1).

A contrast-enhanced computed tomography (CT) scan revealed a large solid mass of similar attenuation to normal liver with no evidence of a central scar. The mass was situated within the inferior aspect of the left lobe of the liver (Fig. 2). The right lobe of the



**Fig. 1** Axial ultrasound image of the liver shows the hypoechoic mass (M) arising from the left lobe of the liver. The right lobe (R) of the liver is uninvolved. The left portal vein (arrow) is displaced anteriorly over the mass.



**Fig. 2** Contrast enhanced CT scan image obtained during the portal venous phase, at the level of the inferior aspect of the liver, shows the isodense mass (M) arising from the left lobe of the liver and displacing the gall-bladder (arrow) towards the right.

Department of  
Diagnostic Imaging,  
Pathology and  
Paediatric Surgery  
Kandang Kerbau  
Women's and  
Children's Hospital  
100 Bukit Timah Road  
Singapore 229899

E L H J Teo, MBBS,  
FRCR  
Senior Registrar

H K Ang, MBBS,  
FRCPath, FAMS  
Consultant

N T Ong, MBBS,  
FRCS (Edin), FAMS  
Consultant

A P A Tan Kendrick,  
BMBCh, FRCR,  
FAMS  
Consultant

Correspondence to:  
Dr E L H J Teo

liver was uninvolved and there was no invasion of the hepatic vasculature. There was no evidence of metastatic disease.

A pre-operative hepatic angiogram showed the left and right hepatic arteries to be enlarged and supplying the tumour, which was highly vascular. There was early visualisation of the inferior vena cava (Fig. 3). No thrombosis was noted in the hepatic vasculature.

The imaging findings at this stage were not characteristic of any particular lesion and differential diagnoses of hepatoblastoma, giant haemangioma and haemangi endothelioma were considered.

At surgery a large, solid, tumour was found to occupy the entire inferior portion of the left lobe of the liver. The right lobe of the liver and the hepatobiliary system were normal. There was no evidence of metastatic spread to the para-aortic lymph nodes or peritoneal cavity. The entire left lobe of the liver and part of segment 5 of the right lobe was resected.

Gross pathological examination of the mass revealed a solid, bulging subcapsular tumour weighing 218 grams and measuring 9 x 4 x 4 cm in size (Fig. 4). The cut surface of the tumour showed distinct circumscription from the adjacent normal liver tissue without a definable capsule. The tumour had a nodular appearance resembling a cirrhotic liver. There was no central scar.

Microscopic examination showed a tumour composed of nodules of hepatocytes separated by fibrous septa of varying thickness with numerous blood vessels and proliferation of biliary ductules within the septa (Fig. 5). The inflammatory cell accompaniment was of varying intensity consisting of lymphocytes and neutrophils.

Despite the lack of a central scar, the histological findings were consistent with FNH. Post-operative progress was uneventful and the patient was discharged 9 days after the operation. The patient was well at an outpatient follow-up visit 2 months after surgery.

## DISCUSSION

Focal nodular hyperplasia (FNH) is a rare, benign liver tumour composed of hyperplastic liver tissue, divided into nodules by vascular fibrous septa radiating peripherally from a central fibrous scar. The aetiology of FNH is unknown but is believed to be due to a reparative process secondary to focal liver cell death. An underlying congenital vascular malformation with localised ischaemic injury seems likely<sup>(1)</sup>. The angiographic and histological features in this patient would support the aetiology of an underlying vascular malformation. A prevalent and distinguishing feature is the central fibrous scar, which occurs in at least 50% of cases, especially in lesions greater than 1 cm in size<sup>(2)</sup>. There is no known association between the

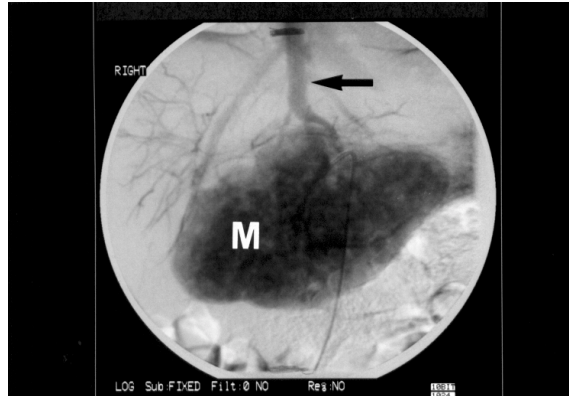


Fig. 3 Spot antero-posterior view obtained during the capillary phase of the hepatic angiogram, shows the highly vascular mass (M) with early visualisation of the inferior vena cava (arrow).

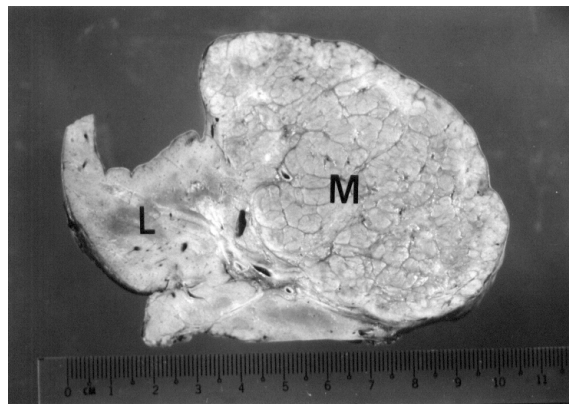


Fig. 4 Cut surface of the mass (M) shows distinct circumscription from the adjacent normal liver tissue (L) without a definable capsule. The tumour is solid with a nodular appearance, resembling a cirrhotic liver.

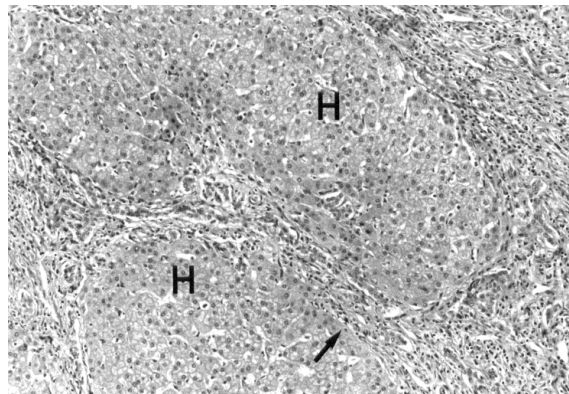


Fig. 5 Photomicrograph of tumour tissue shows nodules of normal hepatocytes (H) separated by fibrous septa (arrow) containing proliferated bile ductules and a mixed inflammatory infiltrate (H&E stain).

age of the patient and the presence and absence of a scar. Most lesions are solitary, measuring less than 5 cm in diameter<sup>(3)</sup>. The tumour rarely grows larger than this because its growth remains proportional to its blood supply and does not exceed it. This probably also accounts for the fact that the tumour does not usually have internal haemorrhage or necrosis<sup>(3)</sup>.

FNH accounts for less than 2% of hepatic tumours

in children or 0.02% of all paediatric Tumours<sup>(4)</sup>. A review of the Medline Data Bank covering the period from January 1966 to December 1993 revealed only 86 cases of paediatric FNH<sup>(4)</sup>. Due to the rarity of the lesion, there are no large series describing the imaging appearances of FNH in children in the literature. The imaging features are not thought to be different from the lesions seen in the adult population<sup>(5)</sup>.

80-95% of FNH is seen in females in the third to fifth decades of life. In paediatric patients the median age of occurrence is 6 years<sup>(2)</sup>. FNH is three to five times more common in females than in males and a similar ratio is seen in the paediatric population<sup>(2)</sup>.

In the adult population, oral contraceptives have been reported to promote the growth of FNH, but unlike hepatocellular adenomas (HCA), do not induce its formation<sup>(6)</sup>. In children, FNH appears unrelated to puberty<sup>(4)</sup>. FNH has also been associated with glycogen storage disease Type 1<sup>(2)</sup>. 80% of children with FNH are asymptomatic and the diagnosis is most often made on routine examination<sup>(4)</sup>. FNH is not known to undergo malignant change and does not usually undergo necrosis or haemorrhage. Treatment can therefore be individualised with some patients being treated conservatively. In recent years different imaging modalities have been used to try to diagnose FNH non-invasively and differentiate it from malignant liver lesions.

Traditionally, technetium (Tc)-99m sulphur colloid scintigraphy has been the modality of choice in diagnosing FNH. 80% of FNH will show uptake of Tc-99m sulphur colloid due to its rich vascular supply and more importantly, the presence of Kupffer's cells within the lesion. Most other space occupying lesions within the liver do not show Tc-99m sulphur colloid uptake. However, hepatocellular carcinomas (HCC) and HCA may occasionally contain Kupffer's cells and show Tc-99m sulphur colloid uptake. The Tc-99m sulphur colloid technique is therefore not pathognomonic<sup>(3)</sup>.

Ultrasound findings in FNH are also non-specific but usually show a well-defined, homogenous, hyper- or isoechoic mass<sup>(3)</sup>. The characteristic central scar is seen in only 20% of patients<sup>(7)</sup> and colour doppler examination often shows increased flow in the central scar and septa- giving rise to a 'spoke-wheel' appearance<sup>(8)</sup>. This correlates with the characteristic pattern seen on angiography where an artery enters the lesion, branches, and supplies the mass centrifugally<sup>(9)</sup>. This pattern may be seen in up to 75% of cases<sup>(10)</sup>. The early venous drainage seen in this case is atypical and has not been previously described in the literature.

The attenuation of FNH is low or isodense to normal liver on unenhanced CT scans<sup>(7)</sup>. Calcification seen

within a lesion should suggest a diagnosis other than FNH as only 1% of FNH calcifies<sup>(11)</sup>. Typically, contrast enhanced CT findings of FNH will show marked enhancement of the lesion during the arterial and early portal venous phases, with the lesion becoming isodense to the liver during the late portal venous phase. The central scar is seen in only one third of cases and appears hypodense to the rest of the lesion. In the late portal venous phase, diffusion of contrast from the parenchyma into the central scar causes it to become hyperdense compared to the rest of the lesion<sup>(3)</sup>. Although typical findings on CT do occur, atypical findings are common and can mimic those of hypervascular primary or metastatic hepatic neoplasms<sup>(12)</sup>.

On magnetic resonance imaging (MRI), FNH is usually isointense, but may be hypointense to normal liver on T1-weighted sequences. On T2-weighted sequences, the lesion is also usually isointense but may be hyperintense to normal liver. The central scar is usually hyperintense on T2-weighted sequences<sup>(13)</sup>. The enhancement pattern of FNH in dynamic gadolinium-enhanced MR imaging is similar to the CT enhancement pattern. On early sequences, the lesion is hyperintense compared to normal liver, followed by isointensity on delayed images. Contrast then diffuses into the central scar, which begins to increase in intensity. This enhancement pattern, however, is not specific and can be seen in other lesions such as HCC, HCA, fibrolamellar carcinoma and giant haemangioma<sup>(13)</sup>. Recently it has been reported that the reticuloendothelial cells within the FNH take up intravenous superparamagnetic iron oxide contrast materials, which appear as areas of low signal intensity on T2-weighted MR sequences<sup>(14)</sup>. This finding is again not specific as HCC and HCA may also contain Kupffer's cells and demonstrate uptake of superparamagnetic iron oxide contrast material.

In summary, there are imaging features highly suggestive but not pathognomonic of FNH. In some institutions, if a contrast enhanced CT scan shows a lesion with characteristics suggestive of FNH, a MRI scan with dynamic gadolinium enhancement and/or superparamagnetic iron oxide contrast material is performed. Should the imaging and clinical findings still strongly suggest FNH, then the patient is followed-up over time with periodic imaging. However, if doubt still exists as to the diagnosis of the lesion, biopsy or surgical resection of the lesion is performed for a definitive diagnosis<sup>(3)</sup>.

In conclusion, FNH occurring in a young child in is extremely rare. Furthermore, a characteristic central scar was absent in this patient resulting in atypical radiological findings. The presence of early venous drainage of the lesion on angiography has not been

previously described. Knowledge of the characteristic imaging findings of FNH is important, as these lesions may be managed conservatively and followed-up over time with periodic imaging. Biopsy or surgical resection is performed if the diagnosis is still in doubt.

## REFERENCES

1. Wanless I, Mawdsley C, Adams R. On the pathogenesis of focal nodular hyperplasia of the liver. *Hepatology* 1985; 5:1194-200.
2. Patterson K. Liver tumors and tumorlike masses. In: Parham DM, editor. *Paediatric neoplasia: morphology and biology*. Philadelphia: Lippincott-Raven, 1996:331-61.
3. Mergo JP, Ros PR. Benign lesions of the liver. *Radiol Clin North Am* 1998; 36(2):319-31.
4. Reymond D, Plaschkes J, Ridolfi Luthy A, Leibundgut K, Hirt A, Wagner HP. *J of Pediatr Surg* 1995; 30(11):1590-3.
5. Buonomo C, Taylor GA, Share JC, Kirks DR. Gastrointestinal tract. In: Kirks DR, Griscom NT, editors. *Practical pediatric imaging: Diagnostic radiology of infants and children*. 3rd edition. Philadelphia: Lippincott-Raven, 1997; 964.
6. Craig GR, Peters RL, Edmonson HA: Tumors of the liver and intrahepatic bile ducts. In: *Atlas of tumor pathology, series 2*. Washington, Armed Forces Institute of Pathology, 1989.
7. Shamsi K, De Schepper A, Degryse H, Deckers F. Focal nodular hyperplasia of the liver: Radiological findings. *Abdom Imaging* 1993; 18:32-8.
8. Wang LY, Wang JH, Lin ZY, Yu ML, Chuang WL, Chen SC et al. Hepatic focal nodular hyperplasia: findings on color Doppler ultrasound. *Abdom Imaging* 1997; 22(2):178-81.
9. Fechner RE, Roehm JO. Angiographic and pathological correlations of hepatic focal nodular hyperplasia. *Am J Surg Pathol* 1977; 1(3):217-24.
10. Rogers JV, Mack LA, Freeny PC, Johnson ML, Sones PJ. Hepatic focal nodular hyperplasia: angiography, CT, sonography, and scintigraphy. *AJR Am J Roentgenol* 1981; 137(5):983-90.
11. Caseiro-Alves F, Zins M, Mahfouz AK, Rahmouni A, Vilgrain V, Menu Y, et al. Calcification in focal nodular hyperplasia: A new problem for differentiation from fibrolamellar hepatocellular carcinoma. *Radiology* 1996; 198:889-92.
12. Choi CS, Freeny PC. Triphasic helical CT of hepatic focal nodular hyperplasia: incidence of atypical findings. *AJR Am J Roentgenol* 1998; 170(2):391-5.
13. Rummeny E, Weissleder R, Sironi S, Stark DD, Comptom CC, Hahn PF, et al. Central scars in primary liver tumours: MR features, specificity and pathological correlation. *Radiology* 1989; 171:323-326.
14. Vogl TJ, Hammerstingl R, Schwarz W, Mack MG, Muller PK, Pegios W, et al. Superparamagnetic iron oxide-enhanced versus gadolinium-enhanced MR imaging for differential diagnosis of focal liver lesions. *Radiology* 1996; 198:881-7.