

# Diffuse Panbronchiolitis – A Case Report

S C Poh, Y T Wang, W Y Wang

## ABSTRACT

Diffuse panbronchiolitis (DPB) is a chronic progressive obstructive disease of the airways. Of unknown aetiology, it is responsive to macrolide therapy. Although not uncommon among the Japanese, it is rare in other parts of the world. We report a case of DPB in a Chinese patient in Singapore.

**Keywords:** diffuse panbronchiolitis, macrolides, Chinese

*Singapore Med J 2001 Vol 42(6):271-274*

## INTRODUCTION

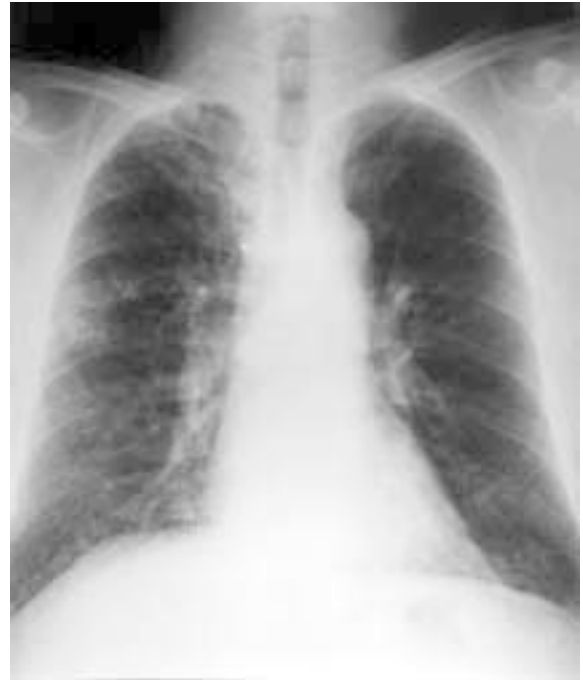Diffuse panbronchiolitis (DPB) is an idiopathic chronic obstructive airways disease first reported in 1969 by Japanese workers<sup>(1-4)</sup>. Pathologically it is characterised by infiltration of the bronchiolar wall by lymphocytes and plasma cells with peribronchiolar accumulation of distinctive foamy macrophages. The clinical features include a chronic cough with purulent sputum, wheezing and progressive respiratory failure and death. The poor prognosis has since 1985 been altered by prolonged treatment with low dose erythromycin<sup>(5,6)</sup> with improvement in the clinical symptoms and the return of respiratory functions to normal.

The disease has been described primarily in the Japanese with occasional cases reported in the other races. Tsang et al<sup>(7)</sup> report their experience with DPB in seven Chinese patients and in their review of the literature of DPB in non-Japanese subjects found a total of 19 Mongoloid (14 Chinese and 5 Koreans) and 13 non-Mongoloid cases. Recently, however, Park et al<sup>(8)</sup> stated that the disease is not rare in Koreans, with about 50 cases reported since 1992.

We report a case of DPB in a Chinese patient in Singapore.

## CASE REPORT

A 49-year-old Chinese presented in July 1996 with a three-year history of a cough productive of some yellowish green sputum. There was no associated dyspnoea nor wheezing. He had diabetes mellitus for



**Fig. 1** Chest radiograph demonstrating profuse predominantly basal nodules and tuberculosis infiltration in the right mid-zone.

the past three years and also suffered from sinusitis for the past 30 years. He used to smoke but stopped the habit 25 years ago. He was born in Singapore and had no other significant history except his older brother was treated for pulmonary tuberculosis 20 years ago.

Clinically he was well. There were no abnormal findings except for crepitations over the right upper lobe. The chest radiograph revealed some opacities in the right mid-zone and diffuse bibasilar nodules (Fig. 1). His sputum smear for tubercle bacilli was positive with the culture subsequently showing organisms sensitive to the standard anti-tuberculosis drugs. His tuberculosis improved with short course anti-tuberculosis chemotherapy which was stopped in January 1997. However, he continued to have a productive cough and occasional rhonchi were heard over his chest. The basal nodular opacities persisted on his chest radiograph. DPB was suspected and further investigations were done. Respiratory function tests showed airways obstruction with no significant response to aerosol bronchodilator. The diffusing capacity was

Department of  
Respiratory  
Medicine  
Tan Tock Seng  
Hospital  
11 Jalan Tan  
Tock Seng  
Singapore 308433

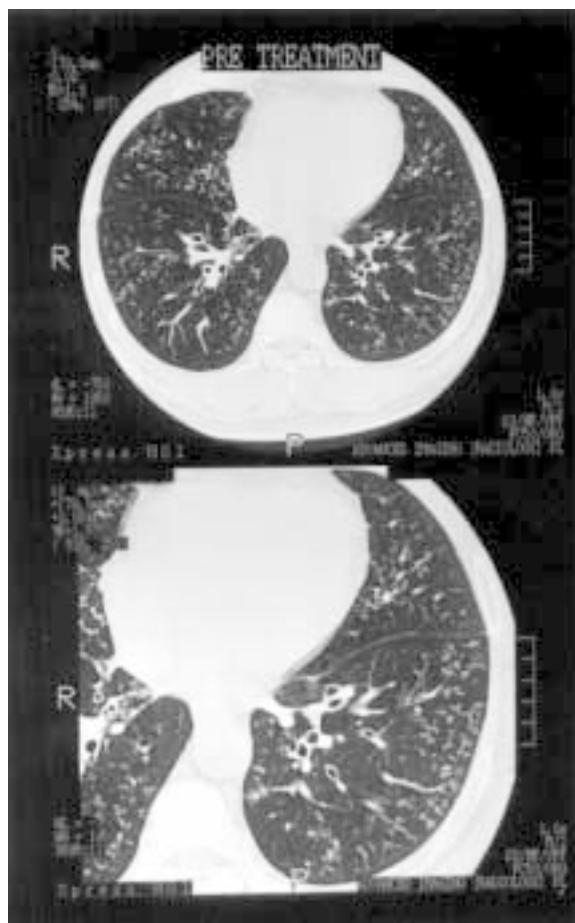
S C Poh, FRCP (Edin)  
Emeritus Consultant

Y T Wang,  
FRCP (Edin),  
MMed (Int. Med)  
Senior Consultant &  
Head

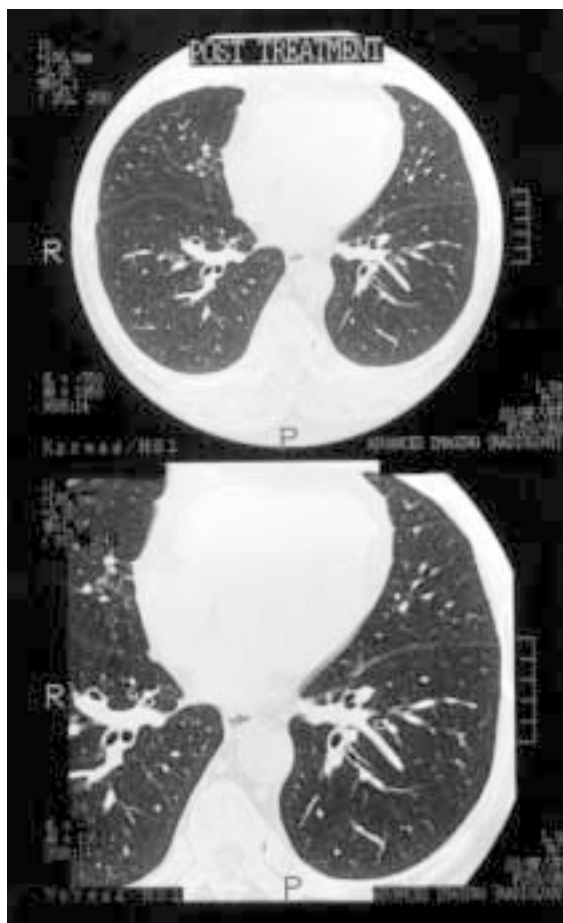
Advanced Imaging  
(Radiology) Pte Ltd  
300 Orchard Road  
#05-01/02  
Singapore 238861

W Y Wang, FRCR (UK)  
Consultant Radiologist

Correspondence to:  
Dr S C Poh  
Tel: (65) 357 7861  
Fax: (65) 357 7871



**Fig. 2a-b** (a) HRCT showing the typical tree-in-bud (Akira type 2) appearance of dilated centrilobular bronchioles filled with pus, fluid or infiltrate in the periphery of the lung. There is also dilatation and thickening of the bronchi. (b) Magnified view.



**Fig. 3a-b** (a) Complete resolution of the tree-in-bud appearance. The dilated and thickened bronchi have also returned to normal. (b) Magnified view.

**Table I. Respiratory function tests**

	Nov 1996	June 1998	Predicted
FEV <sub>1</sub>	2.25	2.95	2.93 L
FVC	3.02	3.88	3.49 L
FEV <sub>1</sub> /FVC%	75	76	84
MMFR	1.73	2.37	3.44 L/sec
FRC	3.41	3.00	2.40 L
RV	2.71	2.42	1.54 L
TLC	5.71	6.40	5.29 L
D <sub>lco</sub>	9.20	9.20	9.60 ml/min/mmHg

normal (Table I). Hypoxemia was present at rest (PaO<sub>2</sub> = 76 mmHg). The blood counts were normal. Culture of his sputum showed no growth of pathogens. His serum immunoglobulins revealed a raised IgA 6.95 G/L (0.7-3.76) and a slightly raised IgG 17.0 G/L (7.30-15.36). Cold agglutinins were negative with negative *Mycoplasma pneumoniae* titres. Anti-nuclear antibody was negative. The rheumatoid factor was positive.

Blood human leucocyte antigen (HLA) showed the presence of HLA-A2 and HLA-DR9 but was

negative for Bw 54. Radiographs of his sinuses revealed bilateral maxillary and frontal sinusitis. A thoracic high resolution computed tomograph (HRCT) demonstrated diffuse bronchiolar disease which were predominantly in the lower lobes accompanied by bronchiolar thickening and mild cylindrical bronchiectasis. The small centrilobular nodules were connected to small linear branching densities giving a "tree-in-bud" appearance typical of DPB. The patient declined a lung biopsy.

He was started on erythromycin therapy (500 mg daily). He experienced significant improvement soon after. He became asymptomatic; his chest was clear on repeated physical examination. Eighteen months later, his FEV<sub>1</sub> had returned to normal although he still had some hyperinflation. His IgA and IgG decreased but still remained raised (IgA 5.89 G/L and IgG 15.3 G/L). A thoracic HRCT done two years after the start of erythromycin therapy showed marked improvement. The radiographic findings pre- and post-treatment are shown in Figs. 2 and 3 respectively. An attempt was made at scoring pre- and post-treatment (Table II) as described by Akria et al<sup>(6)</sup> and Tsang et al<sup>(7)</sup>.

**Table II. Radiological Assessment.**

	Pre-treatment	Post-treatment
Akira HRCT grading	3	2
Nodular profusion (overall score)	1.3	0.8
Airway dilatation (overall score)	1.2	0.2
Airway thickening	1.3	0.7
Hypo-attenuation	Not significant	Not significant
Air trapping	Not tested	Not significant

**Table III. Clinical diagnostic features of diffuse panbronchiolitis.**

Symptoms and signs
Chronic cough, sputum production, exertional dyspnoea.
Chronic pansinusitis.
Pulmonary function
Progressive obstructive or mixed restrictive obstructive airways disease.
Diffusing capacity normal or low.
Radiology
Diffuse nodular opacities especially lower zones.
Hyperinflation.
HRCT demonstrating centrilobular nodules, thickened and ectatic bronchioles and peripheral air trapping.
Laboratory
No specific diagnostic features.
Increased serum cold agglutinin without raised anti-Mycoplasma pneumoniae antibody.
Increased serum IgA and IgG.
Presence of rheumatoid factor or antinuclear antibodies.
Sputum cultures positive for H. influenzae or P. aeruginosa.
HLA-Bw 54 common in Japanese patients.

## DISCUSSION

Although histological confirmation is lacking, the typical clinical picture, physiologic and serological findings and plain radiographic chest and thoracic HRCT features meet the diagnostic criteria for DPB outlined in Table III<sup>(10)</sup>. In addition, the response to treatment with erythromycin would confirm the diagnosis.

The lung function results showing an obstructive pattern and a normal diffusing capacity are consistent with those commonly observed in such patients. Unlike Tsang et al<sup>(7)</sup> who reported a negative rheumatoid factor in all their patients, our patient had a strongly positive rheumatoid factor.

The role of genetic and environmental factors in the pathogenesis of DPB is uncertain. A number of familial cases have been reported in Japan<sup>(11)</sup> and an association between HLA-Bw 54 and DPB was reported by Sugiyama et al<sup>(12)</sup> who showed that 63% of patients possessed the Bw 54 antigen compared with 11% of control subjects. This was confirmed by Keicho et al<sup>(13)</sup> although in their study of 76 patients. The frequency of the Bw 54 antigen was relatively lower than the 63% reported previously. This HLA haplotype was, however, not present in the seven Chinese patients reported by

Tsang et al<sup>(7)</sup> who found HLA-A2 and HLA-DR9 in most of their patients. Interestingly, our patient also tested positive for both HLA-A2 and HLA-DR9, but not for Bw 54. As the allele frequency of Bw 54 is highest and similar among Japanese and Koreans (antigen frequency of 12.2% and 12.6% respectively) and lower in Chinese and other Mongoloids<sup>(14)</sup>, a similar HLA association in Korean patients with DPB could be expected if the HLA-Bw 54 antigen is involved in susceptibility to the disease. However, Park et al<sup>(8)</sup> in their study of 30 Korean patients found the strongest positive association was with HLA-A11. They postulated that "the association of HLA antigens with DPB represent linkage disequilibria to the same disease gene(s) even if different HLA antigens are identified as risk factors in different ethnic groups", and that HLA class I genes are associated with DPB in both Koreans and Japanese.

Macrolides have been shown to be effective therapy in DPB although the precise mechanism is unknown. Anti-inflammatory actions rather than antimicrobial have been implicated including the reduction of pulmonary levels of pro-inflammatory cytokines IL8, TNF $\alpha$  and leukotriene B<sub>4</sub>, a potent neutrophil chemo-attractant<sup>(15,16)</sup>. Prior to the report of the efficacy of erythromycin by Kudoh et al in 1984<sup>(5)</sup>, DPB was associated with a poor prognosis. In a recent retrospective study on the survival of patients treated with low dose erythromycin, Kudoh et al<sup>(17)</sup> report a significant difference in the survival rates between patients treated with erythromycin and those in the non-treated group.

DPS has to be considered in the differential diagnosis of chronic bronchitis and emphysema, bronchiectasis, primary ciliary dyskinesia, cystic fibrosis and Wegener's granulomatosis. However, the clinical features, lung function abnormalities and bilateral nodular opacities on the chest radiograph should alert the physician to the diagnosis.

## REFERENCES

1. Yamanaka A, Saeki S, Tamura S and Saito K. The problems of chronic obstructive pulmonary disease especially diffuse panbronchiolitis. *Nakai-Inter Med* 1969; 23:442-51.
2. Homma H. Diffuse panbronchiolitis. *Jpn J Thorac Dis* 1975; 13:383-95.
3. Homma H. Definition of diffuse panbronchiolitis. *Jpn J Intern Med* 1976; 65:645-59.
4. Homma H, Yamanaka A, Tanimoto S, Tamura M, Chijimatsu Y, Kira S and Izumi T. Diffuse panbronchiolitis: a disease of the transitional zone of the lung. *Chest* 1983; 83:63-9.
5. Kudoh S, Kimura H, Uetake K, Hirayama M, Hisaya T, Teratani K, Sugiyama Y and Miyazaki H. Abstract of Annual Meeting. *Jpn J Thorac Dis* 1984; 22:254.
6. Kudoh S, Uetake T, Hagiwara M, Hus LH, Kimura H and Sugiyama Y. Clinical effect of low-dose long-term erythromycin chemotherapy on diffuse panbronchiolitis. *Jpn J Thorac Dis* 1987; 25:632-42.
7. Tsang KWT, Ooi CGC, Ip MSM, Lam WK, Ngan H, Chan EYT, Hawkins B, Ho CS, Amitani R, Tanaka E and Itoh H. Clinical profiles of Chinese patients with diffuse panbronchiolitis. *Thorax* 1998; 53:274-80.

8. Park MH, Kim YW, Yoon HI, Yoo CG, Han SK, Shim YS and Kim WD. Association of HLA class I antigens with diffuse panbronchiolitis in Korean patients. *Am J Respir Crit Care Med* 1999; 159:526-9.
9. Akira M, Kitatani F, Lee YS, Kita N, Yamamoto S, Higashihara T, Morimoto S, Ikezoe J and Kozuka T. Diffuse panbronchiolitis: evaluation with high resolution CT. *Radiology* 1988; 168:433-8.
10. Fitzgerald JE, King TE, Lynch DA, Tuder RM and Schwarz MI. Diffuse panbronchiolitis in the United States. *Am J Respir Crit Care Med* 1996; 154:497-503.
11. Suzuki M, Usui K, Tamura N, Araki T, Chijimatsu Y, Washizaki M, Inatomi K and Homma H. Familial cases of diffuse panbronchiolitis. *Jpn J Thorac Dis* 1981; 19:645-51.
12. Sugiyama Y, Kudoh S, Maeda H, Suzaki H and Takaku F. Analysis of HLA antigens in patients with diffuse panbronchiolitis. *Am Rev Respir Dis* 1990; 141:1459-62.
13. Keicho N, Tokunaga K, Nakata K, Taguchi Y, Azuma A, Bannai M, Emi M, Ohishi N, Yazaki Y and Kudoh S. Contribution of HLA genes to genetic predisposition in diffuse panbronchiolitis. *Am J Respir Crit Care Med* 1998; 158:846-50.
14. Imanish T, Akaza T, Kimura A, Tokunaga K and Gojobori T. Allele and haplotype frequencies for HLA and complement loci in various ethnic groups 1992. In Tsuji K, Aizawa M and Sasazuki T, editors. *HLA 1991; Vol 1*. Oxford University Press, New York:1065-220.
15. Koga T. Neutrophilia and high level of interleukin 8 in the bronchoalveolar lavage fluid of diffuse panbronchiolitis. *Kurume Med J* 1993; 40:139-46.
16. Oda H, Kadota J, Kohno S and Hara K. Leukotriene B<sub>4</sub> in bronchoalveolar lavage fluid of patients with diffuse panbronchiolitis. *Chest* 1995; 108:116-22.
17. Kudoh S, Azuma A, Yamamoto M, Izumi T and Ando M. Improvement of survival in patients with diffuse panbronchiolitis treated with low dose erythromycin. *Am J Respir Crit Care Med* 1998; 157:1829-32.