

A Ten-Year Review of Ruptured Sinus of Valsalva: Clinico-Pathological and Echo-Doppler Features

R P Shah, Z P Ding, A S H Ng, S S S Quek

ABSTRACT

Rupture of the sinus of valsalva (RSOV) is an uncommon condition with a variety of manifestations ranging from an asymptomatic murmur to cardiogenic shock. This retrospective 10-year review (1985 - 1995) of 18 patients from a single institution revealed that 6 (33%) were female and 12 (67%) were male with a mean age of 37.6 ± 13.4 years and that 72% were Chinese by ethnic descent with the remaining 28% being Malay. Eight patients (44.4%) presented with an asymptomatic murmur, 4 (22.2%) with acute chest pain, 4 (22.2%) with mild heart failure, 2 (11.1%) with severe heart failure, and 2 (11.1%) with cardiogenic shock. Rupture of the right aneurysmal coronary cusp (RCC) made up 15 (83.3%) while those of the non-coronary cusp (NCC) made up the remaining. Most of the RCC ruptures were directed into the right ventricle and all of the NCC ruptures were into the right atrium. Ventricular septal defects (VSDs) were found in 9 (50%) of the patients, (although detected by echocardiography in only one third of those patients), aortic regurgitation in 6 (33.3%) and aortic valve vegetations in 2 (11.1%). Echocardiography was found to be accurate in diagnosing RSOVs with 100% diagnostic accuracy after 1990 with four misdiagnoses before 1990. Of these four patients, two were misdiagnosed as having VSDs, one as having a coronary arteriovenous fistula and one as having a patent ductus arteriosus. The anatomical structure of the "windsock" was seen in 64% of the patients who were correctly diagnosed. The pattern of colour flow and spectral Doppler was seen in all patients and helped to localise the site of rupture and the direction of flow.

In summary, echocardiography is a simple and accurate way of diagnosing and defining RSOVs and is the imaging modality of choice.

Keywords: echocardiogram, Doppler, ruptured sinus of valsalva

INTRODUCTION

Ruptured sinus of valsalva (RSOV) is an uncommon condition with protean manifestations. The presentation may range from an asymptomatic murmur to acute cardiogenic shock and death. As clinical examination is not entirely reliable and the patient can sometimes be so ill as to preclude cardiac catheterisation, echocardiography has become the definitive investigative tool not only to define and diagnose the lesion but also to quantify its severity. It thus plays a critical role in the management of the patient. We conducted this retrospective review to determine the demographics of this condition in our local population, its clinical features, and accuracy of echocardiography as a primary diagnostic tool.

METHODS

Review of the cardiothoracic surgical records of our hospital from 1985 to 1995 revealed that 18 patients had been admitted to the Department of Cardiology, Singapore General Hospital with the diagnosis of RSOV. We then reviewed the patient demographics, clinical status, pre-operative echocardiographic findings, and correlated them with the surgical findings.

RESULTS

Out of a total of 7,586 patients undergoing open cardiac surgical procedures from 1985 to 1995 in our institution, there were 18 (0.24%) patients with RSOV consisting of 6 (33%) females and 12 (67%) males. The ages at presentation ranged from 20 to 65 years with an average age of 37.6 ± 13.4 years. The majority of patients were Chinese, numbering 13 (72%) and the rest (five patients) were Malays (28%). There were no patients belonging to the other ethnic groups such as Indians and Caucasians. There was no statistical correlation between patient demographics and type of RSOV.

As expected, there was a wide variation in the mode of presentation of our patients. Eight patients (44.4%) presented with an asymptomatic murmur that was detected during a physical examination for an unrelated medical condition. The rest of the patients included 4 (22.2%) patients with mild heart failure, 2 (11.1%)

Department of
Cardiology
Gleneagles Medical
Centre
1, Jalan Pangkor
Penang 10050
Malaysia

R P Shah, MBBS,
MMed (Int Med),
FRCP (Edin)
Consultant

Department of
Cardiology
National Heart
Centre
Mistri Wing
Third Hospital
Avenue
Singapore 169608

Z P Ding, MBBS,
MMed (Int Med)
Senior Consultant

A S H Ng, MBBS,
MMed (Int Med)
Senior Consultant

Mount Elizabeth
Hospital
3 Mount Elizabeth
Singapore 228510

S S S Quek, MBBS,
MMed (Int Med)
Consultant Cardiologist

Correspondence to:
Dr R P Shah
Tel: (604) 227 6111
Fax: (604) 226 2994
Email: dr_rajesh_shah
@hotmail.com

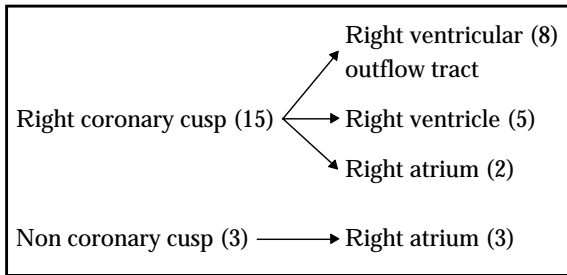


Fig. 1 Distribution of the types of ruptured sinuses of Valsalva in the study.

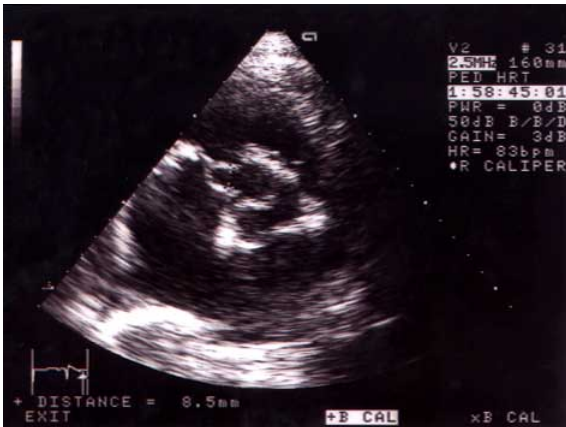

Fig. 2 2-D Echo picture showing the typical 'windsock' appearance of an aneurysm of the sinus of Valsalva.

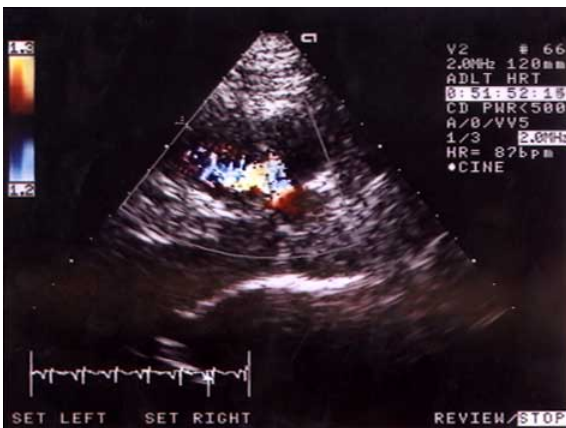

Fig. 3 The typical mosaic colour jet showing the blood flow across a ruptured sinus of Valsalva.

with severe heart failure, 4 (22.2%) with acute chest pain and 2 (11.1%) with cardiogenic shock.

Several other congenital and acquired cardiovascular conditions known to occur more frequently with RSOV were also detected. Concomitant ventricular septal defects (VSD) were found in half of the patients at surgery although the echocardiogram detected this in two patients (11.1%). Both of these VSDs measured more than 1.5 cm in diameter. Six patients (33.3%) with at least mild aortic regurgitation (AR) were diagnosed by echocardiography. Vegetations of the aortic valve were demonstrated in 2 (11.1%) patients on echo.

Infective endocarditis was subsequently confirmed by positive blood cultures.

Further analysis of the surgical anatomy of the RSOV was also carried out. Of the 18 patients studied, 15 (83.3%) had ruptures of the aneurysm of the right coronary cusp (RCC) and only three patients had ruptures of the aneurysm of the non-coronary cusp (NCC). There were no patients with ruptures of the aneurysm of the left coronary cusp (LCC). Most of the RCC aneurysms ruptured into the right ventricle and all of the NCC aneurysms ruptured into the right atrium (Fig. 1). This is in keeping with the anatomical juxtaposition of these structures.

We next looked into the accuracy of echocardiography in diagnosing these lesions. Of the 18 patients, three echo reports were not available, leaving a total of 15 analysable reports. 11 patients (73%) were correctly diagnosed on echo (including 100% of patients since 1990) and four were either missed or misdiagnosed (all before 1990). Of the four, two patients were diagnosed as having VSDs only, one as a coronary arteriovenous fistula (CAVF) and the last as having a patent ductus arteriosus (PDA). We did not analyse the use of transoesophageal echocardiogram, as it was only available in the last few patients.

All these 11 patients had the pathological anatomy of the RSOV correctly diagnosed by echocardiography and confirmed at surgery. However, the typical "windsock" pattern was only defined in seven of the 11 patients (64%) with the remaining four patients having suboptimal images. The diagnosis of rupture of the sinus of Valsalva aneurysm in all patients was made on the basis of the colour flow imaging pattern and Doppler spectra showing a continuous flow from the aorta to the respective right heart chambers. Hence, although 2-D echo imaging can establish the diagnosis of a sinus of Valsalva aneurysm, colour flow imaging and Doppler spectral analysis are necessary to diagnose rupture.

DISCUSSION

Ruptured sinus of Valsalva is a rare entity and was previously elusive to reliable diagnosis by non-invasive means. The unruptured aneurysm is usually silent and undiagnosed but may cause symptoms caused by right ventricular outflow tract obstruction⁽¹⁾. The rupture may occur into any cardiac chamber, predominantly the right ventricle or right atrium, but it may also rupture into the left ventricle⁽²⁾, the interventricular septum⁽³⁾, and the pericardial space⁽⁴⁾. The pathology of this condition is thought to be due to a failure of the fusion between the aortic media and the heart at the level of the annulus fibrosus of the aortic valve, with subsequent aneurysmal enlargement at this weak

point due to the high head of pressure at the root of the aorta⁽⁵⁾. It may be related to diseases of the connective tissue such as Marfan's syndrome⁽⁶⁾ and Behcet's disease⁽⁷⁾. Rupture can also occur with endocarditis affecting the aortic valve⁽⁸⁾ or a VSD⁽⁹⁾, reflecting the weakening of the aortic wall due to the inflammatory process and occasionally by severe chest trauma⁽¹⁰⁾.

Although the first reported case of RSOV diagnosed by echocardiography was in 1974⁽¹¹⁾, the gold standard for diagnosis of this lesion has traditionally been cardiac catheterisation and aortography. With the advent of newer generation ultrasound machines, transthoracic echocardiography and now transoesophageal echocardiography⁽¹²⁾ have taken centre stage for diagnostic confirmation. Workers have also looked at magnetic resonance imaging (MRI)⁽¹³⁾ as a diagnostic tool. Although the results are encouraging, the lower cost, equal accuracy, convenience and safety of an echocardiogram, especially in critically ill patients, far outweigh the benefits of MRI.

The 2-D echo features of RSOV include the aneurysmal dilatation of the sinus of valsalva where a "windsock" appearance may be identified. Echo dropout may indicate rupture of the tip and a negative contrast effect with agitated saline bubble contrast in the right heart indicates abnormal flow from the aorta to the respective right heart chamber. There may also be end diastolic opening of the pulmonary valve in ruptures into the right ventricle indicating a progressive rise of right ventricular diastolic pressure. Doppler features include a continuous high velocity unidirectional flow through the lesion. The diagnosis is usually confirmed on colour flow imaging, which reveals a unidirectional continuous mosaic jet from the aorta to the right heart chamber. These features may be more clearly seen on transoesophageal echocardiography. The Sakakibara and Konno classification⁽¹⁴⁾ has not been used routinely to describe the patho-anatomy of the RSOV, as it has not been found to be useful in determining the management or outcome of the patients.

Our data is consistent with recent data from other workers⁽¹⁵⁻¹⁹⁾ in that rupture of the aneurysm of the right coronary cusp sinus of valsalva into the right ventricle is by far the commonest type of RSOV. The reason for this is unknown and there is no statistical correlation with patient demographics. Left coronary sinus ruptures are extremely uncommon and we did not have patients with this type of lesion. In our cohort, although VSDs were documented at surgery in half of the patients only a third of these were diagnosed pre-operatively and only the larger VSDs at that. This appears to be because the presence of a turbulent RSOV jet masks the jet of the VSD. The fact that most

of the VSDs were subarterial in character made the colour jets even more difficult to identify. It is well known that the associated VSDs in the Asian population are more likely to be subarterial whereas those in Caucasians are usually perimembranous⁽¹⁸⁾. However, all the patients with at least mild aortic regurgitation were easily and correctly identified. This is because the jet was directed towards the left ventricular cavity and was easily distinguished from the RSOV jet. As pandiastolic reversal of the aortic flow is seen in RSOV, it cannot be used to help grade the severity of the concomitant AR. At surgery, the AR was determined to be due to distortion of the leaflet anatomy by the aneurysm causing mal-coaptation in four patients, while in the other two, there was infective endocarditis of the leaflets with consequent structural damage.

Our data also shows that even though there has been 100% accuracy in diagnosis of this condition by echocardiography since 1990, a few pitfalls must be kept in mind. There were two patients who were misdiagnosed as having VSDs only. This was because the VSDs were subarterial and very close to the aortic cusps leading to confusion about whether the jet was above or below the valve. In this situation, the characteristic Doppler spectrum showing continuous high velocity flow as opposed to a high velocity systolic and a low velocity diastolic flow differentiates the two conditions. However, if both conditions co-exist, then the VSD jet may be hidden in the RSOV jet as described earlier. Both coronary arteriovenous fistula and patent ductus arteriosus present with continuous murmurs and the pattern of colour flow in the right ventricular outflow tract and pulmonary artery must be scrutinised carefully to avoid misdiagnosis. It is especially important to track the origin of the abnormal jet by paying attention to its proximal acceleration.

In conclusion, our data reveals that RSOV is a rare condition with a varied presentation that sometimes can be fatal if not diagnosed quickly. Right coronary sinus of valsalva to right ventricle ruptures are the commonest type of RSOV and there is an association with VSDs, aortic regurgitation and infective endocarditis. Echocardiography is an accurate and reliable non-invasive tool to diagnose the lesion and obviates the need for cardiac catheterisation in most cases.

REFERENCES

1. Malcolm I. Unruptured aneurysm of the sinus of valsalva. *Can J Cardiol* 1996; 12(9):783-5.
2. Kucukoglu S, Ural E, Mutlu H, Ural D, Sonmez B, Uner S. Ruptured aneurysm of the sinus of valsalva into the left ventricle: report and review of the literature. *J Am Soc Echocardiogr* 1997; 10(8):862-5.
3. Abad C. Congenital aneurysm of the sinus of valsalva dissecting into the interventricular septum. *Cardiovasc Surg* 1995; 3(5):563-4.

4. Brabram KR, Roberts WC. Fatal intrapericardial rupture of sinus of valsalva aneurysm. *Am Heart J* 1990; 120(6 Pt 1):1455-6.
5. Edwards JE, Burchell HB. The pathological anatomy of the deficiencies between the aortic root and the heart including aortic sinus aneurysms. *Thorax* 1957; 12:125-39.
6. Tesler UF, Fiorilli R, Lisanti P. Repair of a ruptured sinus of valsalva aneurysm associated with annulo-aortic ectasia and coarctation of the aorta in a patient with Marfan's syndrome. *Tex Heart Inst J* 1997; 24(2):134-8.
7. Koh KK, Lee KH, Kim SS, Lee SC, Jin SH, Cho SW. Ruptured aneurysm of the sinus of valsalva in a patient with Behcet's disease. *Int J Cardiol* 1994; 47(2):177-9.
8. Hurley J, McGovern E. Rupture of a sinus of valsalva aneurysm due to aspergillus endocarditis. *J Cardiovasc Surg (Torino)* 1994; 35(1):75-7.
9. Bansal RC, Wangsnes KM, Bailey L. Right aortic sinus of valsalva to right ventricle fistula complicating bacterial endocarditis of membranous ventricular septal defect. *J Am Soc Echocardiogr* 1993; 6(3 Pt 1):308-11.
10. Murrall EG, Minami K, Kortke H, Seggewiss H, Korfer R. Traumatic sinus of valsalva fistula and aortic valve rupture. *Ann Thorac Surg* 1993; 55(3):760-1.
11. Cooperberg P, Mercier EN, Mulder D, Winsberg GF. Rupture of a sinus of valsalva aneurysm. Report of a case diagnosed pre-operatively by echocardiography. *Radiology* 1974; 113:171-2.
12. Wang KY, St John Sutton M, Ho HY, Ting CT. Congenital sinus of valsalva aneurysm: a multiplane transoesophageal experience. *J Am Soc Echocardiogr* 1997; 10(9):956-63.
13. Kulan K, Kulan C, Tuncer C, Komsuoglu B, Zengin M. Echocardiography and magnetic resonance imaging of sinus of valsalva aneurysm with rupture into the ventricle. *J Cardiovasc Surg (Torino)* 1996; 37(6):639-41.
14. Sakakibara S, Konno S. Congenital aneurysm of the sinus of valsalva: anatomy and classification. *Am Heart J* 1962; 63:405-24.
15. Dev V, Goswami KC, Shrivastava S, Bahl VK, Saxena A. Echocardiographic diagnosis of aneurysm of the sinus of valsalva. *Am Heart J* 1993; 126(4):930-36.
16. Isomura T, Hisatomi K, Hirano A, Satho T, Kosuga K, Ohishi K. Ruptured aneurysms of the sinus of valsalva. *J Cardiovasc Surg (Torino)* 1994; 35(2):135-8.
17. Lukacs L, Bartek I, Haan A, Hankoczy J, Arvay A. Ruptured aneurysms of the sinus of valsalva. *Eur J Cardiothorac Surg* 1992; 6(1):15-7.
18. Van Son JA, Danielson GK, Schaff HV, Orszulak TA, Edwards WD, Seward JB. Long term outcome of surgical repair of ruptured sinus of valsalva. *Circulation* 1994; 90(5 Pt 2):II20-9.
19. Jeyamalar R, Kannan P. Ruptured aneurysms of the sinus of valsalva. *Med J Malaya* 1991; 46(4):371-5.