

Antero-Medial Orbital Masses Associated with Nasopharyngeal Carcinoma

S Amrith

ABSTRACT

Background: Nasopharyngeal carcinoma (NPC) involves the orbits through direct extension to the orbital apex via the cavernous sinus. Anterior orbital masses are very rare with only a few anecdotes in the literature about an anterior spread via nasal cavity or tumour arising de novo from the lacrimal sac. Reactive lymphoid hyperplasia in the orbit has never been reported in association with NPC.

Materials and Methods: Three cases that presented with antero-medial orbital mass in association with NPC are described. Two of the three cases including one with bilateral orbital mass, had biopsy proven NPC in the orbit and presented with tearing due to lacrimal sac involvement with a palpable mass in the antero-medial orbit. The third case presented with a left antero-medial orbital mass, which on biopsy proved to be a reactive lymphoid hyperplasia. He was detected to have NPC while investigating the orbital mass. All had raised serum levels of IgA against Epstein-Barr virus (EBV).

Discussion: The possible mode of spread in our case with bilateral involvement is most likely to be a metastasis, though a microscopic anterior spread through the nasal cavity and nasolacrimal duct could not be ruled out despite there being no evidence of tumour in the original site or nasal cavity. In the second case, the tumour spread from the nasal cavity into the orbit is clearly via the nasolacrimal duct. The third patient presents an interesting association of lymphoproliferative disorder and NPC with Epstein-Barr virus infection.

Conclusion: Anterior orbital masses involving nasolacrimal duct and lacrimal sac are rare in NPC, but can occur. A rare association of a reactive lymphoid hyperplasia in the orbit with NPC is described.

Keywords: Antero-medial orbital mass, Epstein-

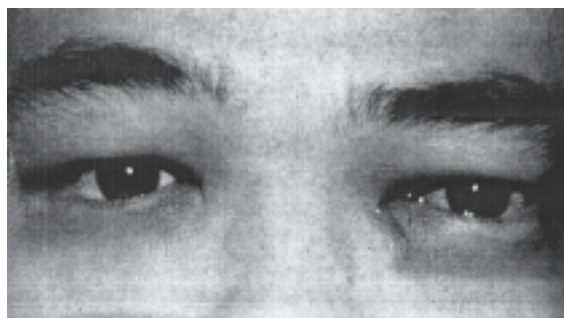

Fig. 1 Case 1: Clinical picture showing swelling in the lacrimal sac area with tearing.

Barr virus, Lymphoproliferative disorder, Nasopharyngeal carcinoma, Tearing

Singapore Med J 2002 Vol 43(2):097-099

INTRODUCTION

The incidence of nasopharyngeal carcinoma (NPC) is 30 times higher among the Chinese race compared to the North American and European Caucasians⁽¹⁾.

Orbital spread of NPC is typically via cavernous sinus involving the apex of the orbit causing proptosis and extra-ocular muscle palsies. An anterior orbital mass due to NPC is very rare.

Histologically, NPC is an undifferentiated carcinoma with a stroma of lymphocytes consisting mainly of T-lymphocytes and several other immunohaematologic cells. Apart from some genetic associations, a close relationship between Epstein-Barr virus (EBV) and NPC has been extensively documented. The high frequency and often, high titres of specific serum IgA antibodies to EBV appear to be a characteristic feature of this cancer.

Here, three unusual cases of antero-medial orbital masses are described all of whom had NPC and high titres of IgA against EBV antigens.

MATERIALS AND METHODS

Three cases of antero-medial orbital masses associated with NPC that presented to the ophthalmology clinic are reported for their unusual nature and way of presentation.

Singapore National
Eye Centre &
Department of
Ophthalmology
National University
Hospital
5, Lower Kent
Ridge Road
Singapore 119074

S Amrith, FRCS,
FRCO, FAMS
Consultant

Correspondence to:
Dr Shantha Amrith
Tel: (65) 772 5317/18
Fax: (65) 777 7161
Email: ophv14@
nus.edu.sg

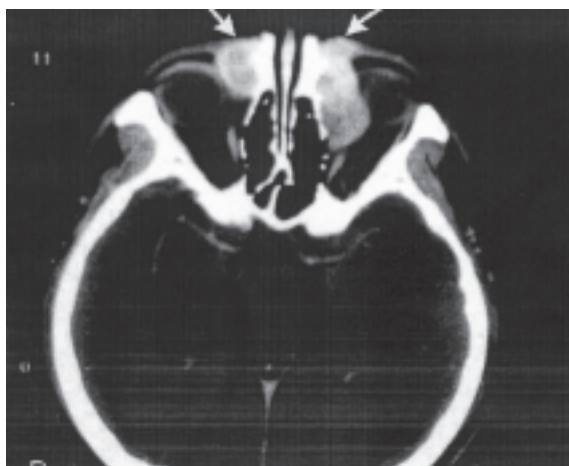

Fig. 2 Axial CT scan of Case 1 showing bilateral antero-medial orbital masses (arrows).

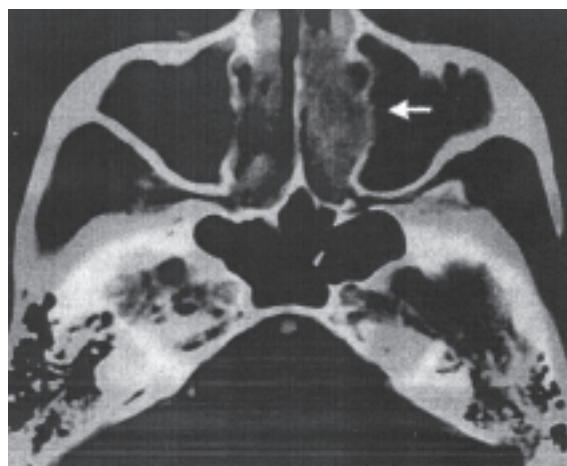


Fig. 3 Axial CT scan of Case 2 showing the mass in the nasal cavity (arrow).

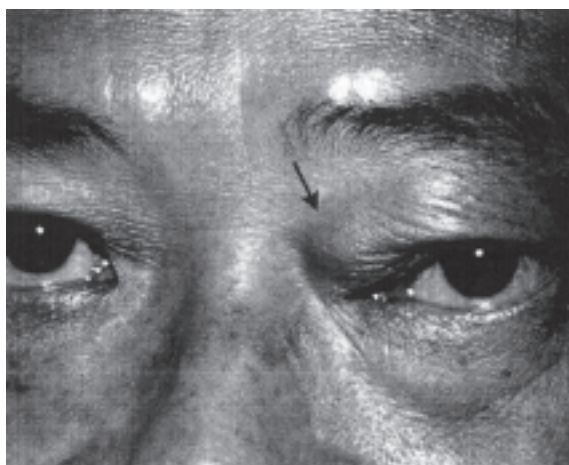

Fig. 4 Clinical picture of Case 3 showing a mass in the inner angle of the upper lid.

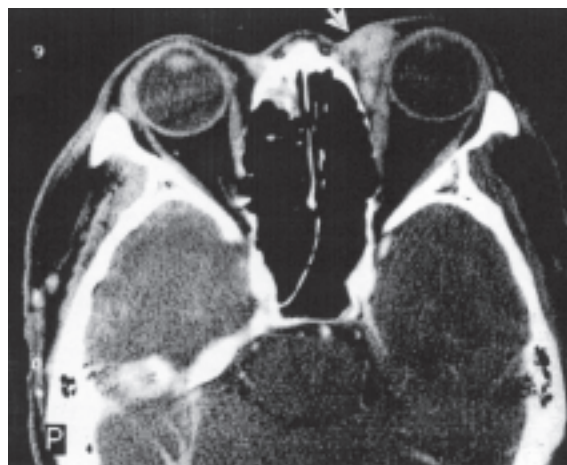


Fig. 5 Axial CT scan of Case 3 showing an antero-medial mass in the left orbit (arrow).

CASE 1

A 33-year-old Chinese male (Fig. 1) presented to the ophthalmology clinic with a history of tearing in both eyes for a few months. Four years prior to this episode, the patient was diagnosed to suffer from NPC with enlarged cervical lymph nodes bilaterally. A course of radiotherapy was instituted.

On examination, lacrimal mucoceles were noted on both sides. In addition to the mucoceles, hard lumps were felt in the medial sides of both orbits. Nasopharynx itself was normal with no tumour recurrence, as confirmed by a negative biopsy. The anterior nasal cavity was normal on gross examination.

CT scans of the orbits (Fig. 2) revealed bilateral extraconal soft tissue masses on the medial aspects of the orbits occupying the anterior part. The lacrimal sacs could not be seen separate from the mass. The tumour masses were seen extending into both the nasolacrimal ducts. The CT scan of the nasopharynx and the nasal cavity were normal. A biopsy of the orbital mass was carried out and the histology revealed an undifferentiated carcinoma consistent with NPC.

The patient had no evidence of any other metastatic spread. IgA levels against viral capsid antigen and early antigen of EBV were elevated.

CASE 2

A 59-year-old Chinese female presented to the clinic in April 97 with blood stained tears with swelling on the left lacrimal sac region. The patient was diagnosed to have NPC with lymph node spread and erosion of base of skull in October 95. She had undergone radiotherapy. In March 96, bilateral anterior nasal cavity masses (NPC) were noted, and treated by brachytherapy but did not completely regress with treatment.

CT scans at the time of presentation in April 97 showed infiltration in nasolacrimal ducts bilaterally that were continuous with the nasal masses (Fig. 3) and an antero-medial mass in the left orbit. Biopsy of the orbital mass confirmed the presence of NPC. High titres of IgA for both viral capsid and early EBV antigens were noted. The patient had multiple metastatic lesions and succumbed to the disease.

CASE 3

A 53-year-old Chinese male (Fig. 4) presented with a history of a painless mass in the inner corner of a left upper lid. The mass was gradually growing in size for one year.

A circumscribed mass was felt in the superior medial angle of the left orbit. CT scan of the orbits (Fig. 5) showed a slightly enhancing extraconal mass in the antero-medial aspect of the left orbit. Incidentally, some thickening of the right wall of the nasopharynx was noted in the CT scan.

An excision biopsy of the mass was carried out through an anterior orbitotomy. The histology revealed it to be reactive lymphoid hyperplasia. Immunostains showed T and B-lymphocytes with the former predominating. A biopsy of the nasopharynx revealed an undifferentiated carcinoma. The IgA for both viral capsid and early EBV antigens was elevated. The patient had evidence of tumour spread to neck ends and metastatic lesions in the ribs.

DISCUSSION

Presentation with antero-medial orbital masses in cases of NPC is extremely rare. Liaw et al⁽²⁾ described three cases of NPC where the tumor extended to apex of the orbit via cavernous sinus causing proptosis, blurred vision and pain. This is probably the most common way the orbits are involved in NPC.

Bilateral orbital metastasis is generally very rare; only 7% of all orbital metastasis are bilateral⁽³⁾. Case 1 appears to be a bilateral metastasis, with no connection to the primary site namely the nasopharynx. There have so far been no reports of unilateral or bilateral orbital metastases from NPC. However, a report by Shu et al⁽⁴⁾ described the possibility of microscopic anterior extension of the tumour through the nasal cavity to the lacrimal sac and hard palate. As we do not have a biopsy from the nasal mucous membrane at the inferior meatus or floor of the nasal cavity, this possibility cannot be ruled out in our case. Leung et al⁽⁵⁾ described a case of NPC arising primarily from the lacrimal sac with positive signal for EBV encoded small nuclear early region (EBER) RNA in malignant cells. The nasopharynx in their case was free of any tumour involvement. They suggested the possibility that EBV related tumours could arise from sites such as lacrimal sac, sinuses and nasal cavity other than nasopharynx. If this were true, our first case may represent a multicentric origin of NPC.

The second case seems to be a direct spread to the medial orbit from an anterior nasal mass (NPC) via nasolacrimal duct, which again is an unusual way of orbital spread in cases of NPC.

Both case 1 and 2 presented with tearing as the main symptom due to the involvement of nasolacrimal ducts and lacrimal sac.

The third case is interesting in more than one aspect. Firstly, it was while investigating for the orbital mass that the NPC was discovered. Secondly, though there is no causal relationship between the orbital mass and the NPC, both could be related to EBV.

The two best-known malignancies in EBV infection are Burkitt's lymphoma and undifferentiated NPC⁽⁶⁾. The bulk of evidence supports B cells to be the primary EBV reservoir. The rich lymphoid stroma in NPC is thought to represent an immune response against viral antigen. It has been suggested⁽⁷⁾ that the presence of lymphoid stroma may be a requirement for NPC growth at least in certain stages of the tumour development. It is also known that a small percentage of benign lymphoproliferative disorders may be capable of malignant transformation with time⁽⁸⁾.

With the evidence presented above, it appears that the presence of lymphoproliferative disorder and NPC in Case 3 may be more than a mere coincidence and that they are probably related to EBV.

Ho et al⁽⁹⁾ pointed out that the percentage of patients with IgA titre for viral capsid antigen equal to or >320 increased steadily in advancing stages of the disease. Only the third case had a titre of 640, the other two cases had a titre of 160. Clinically, Case 2 was in an advanced state of the disease, yet the titres were higher in Case 3.

REFERENCES

1. Witte MC, Neel HB III. Nasopharyngeal cancer. In: Byron J Bailey ed. Head & Neck Surgery-Otolaryngology. Philadelphia, New York: Lippincott-Raven, 1998; 1637-52.
2. Liaw CC, Ho YS, Ng KK. Nasopharyngeal carcinoma presenting as a retro-orbital mass - Report of three cases. Otolaryngol Head Neck Surg 1990; 103(5):825-8.
3. Goldberg RA, Rootman J, Cline RA. Tumours metastatic to the orbit: A changing picture. Surv Ophthalmol 1990; 35(1):1-24.
4. Shu CH, Shiau CY, Chi KH, Li WY. Salvage surgery for recurrent nasopharyngeal carcinoma in the anterior marginal miss after radio-therapy. Otolaryngol Head Neck Surg 1999; 121(5):622-6.
5. Leung SY, Chung LP, Ho CM, Yuen ST, Wong MP, Kwong WK. An Epstein-Barr virus positive undifferentiated carcinoma of the lacrimal sac. Histopathology 1996; 28(1):71-5.
6. Griffin BE, Xue SA. Epstein-Barr virus infections and their association with human malignancies. Annals of Medicine 1998; 30(3):249-59.
7. Agathangelou A, Niedobitek G, Chen R, Nicholls J, Yin W, Young LS. Expression of immune regulatory molecules in Epstein-Barr virus-associated nasopharyngeal carcinomas with prominent lymphoid stroma. Evidence of interaction between epithelial tumor cells and infiltrating lymphoid cells. 1995; Am J Pathol 147(4):1152-60.
8. Rootman J, Robertson W, Lapointe JS, and White V. Lymphoproliferative and leukaemic lesions. In: Jack Rootman ed. Diseases of the Orbit. Philadelphia: JB Lippincott Co 1988; 205-40.
9. Ho S, Teo P, Kwan WH, Choi P, Tjong J, Johnson PJ. Staging of IGA VCA titre in patients with nasopharyngeal carcinoma: changes over a 12-year period. Oral Oncology 1998; 34 (6):491-5.