

Clinics in Diagnostic Imaging (72)

J W Kwek, S T Quek, W C G Peh

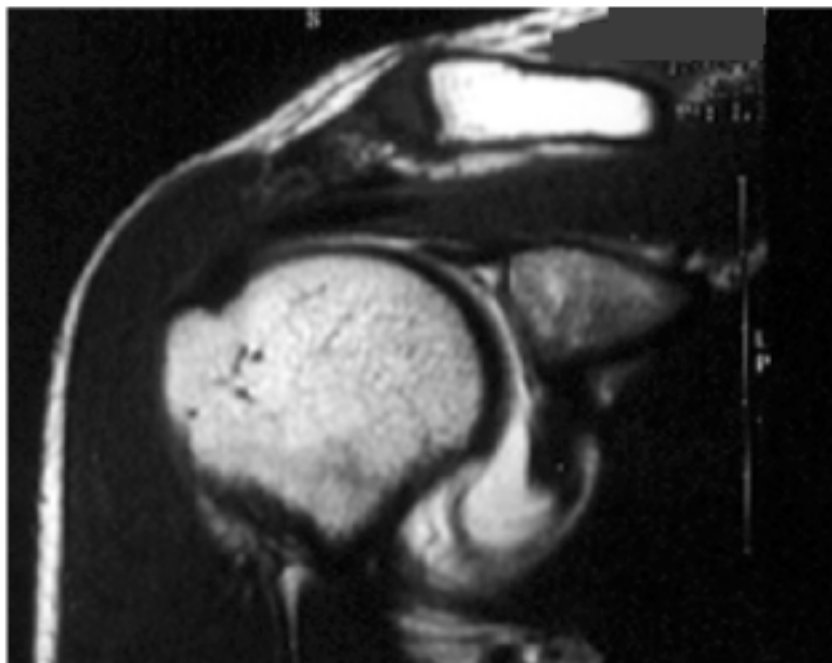


Fig. 1 Oblique coronal T1-W MR arthrogram image of the right shoulder.

CASE PRESENTATION

A 31-year-old Chinese woman who is an active sportsperson presented with pain and associated “clicking” in her right shoulder. On clinical examination, there was a full range of active and passive movement in both shoulders with no

signs of impingement. There was no wasting of the shoulder muscles. Stress manoeuvres did not reveal glenohumeral instability. Magnetic resonance (MR) arthrogram of the right shoulder was performed (Fig. 1). What does the MR arthrogram show? What is the diagnosis?

Department of
Diagnostic
Radiology
Singapore General
Hospital
Singapore 169608

J W Kwek, MBBS,
FRCP,
Registrar

W C G Peh, MD,
FRCP, FRCP,
Clinical Professor and
Senior Consultant

Department of
Diagnostic Imaging
National Cancer
Centre
Singapore 169610

S T Quek, MBBS,
FRCP,
Consultant

Correspondence to:
Prof Wilfred C G Peh
Tel: (65) 6326 6908
Fax: (65) 6326 5161
Email: gdrpeg@sgh.com.sg