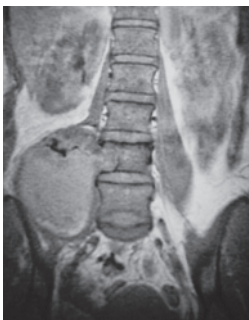

Editor

A/Prof C Rajasoorya

Deputy EditorsProf Wilfred C G Peh
A/Prof Sonny Wang Yee TangCorresponding EditorsProf Azrul Azwar (Indonesia)
Prof Myo Myint (Myanmar)
Prof Neil Pride (UK)
Prof Tan Chong Tin (Malaysia)
Prof Teh Bin Tean (USA)
Prof Victor Yu (Australia)Editorial BoardDr Chin Jing Jih
Dr Chow Wan Cheng
Dr Chuah Khoon Leong
A/Prof Ho Nai Kiong
Prof Kua Ee Heok
Dr Kenneth Lyen
Dr Denis Nyam
A/Prof Paul Ananth Tambyah
A/Prof Luke Tan Kim Siang
Dr Kelvin Tan Kok Hian
Dr Jackie Tan Yu LingEx-OfficioProf Low Cheng Hock
Dr Tham Tat YeanEditorial AssistantsChua Gek Eng
Dr Tham Wai Fong, EileenEditorial AddressA/Prof C Rajasoorya, Editor
Singapore Medical Journal
Singapore Medical Association
2 College Road
Singapore 169850Cover Picture:

More anterior image shows the large extradural component of the dumbbell tumour which has extended into the right paravertebral and retroperitoneal area.
(Refer to page 433-438)

Modern Imaging of the Musculoskeletal System: Is There Still a Role for Radiography?

W C G Peh

Musculoskeletal imaging has experienced a marked resurgence over the past decade or so, due in no small way to the introduction of modern imaging and interventional techniques. These modern imaging techniques include magnetic resonance (MR) imaging, computed tomography (CT), ultrasonography, and nuclear medicine imaging. The applications of MR imaging in the assessment of a full range of musculoskeletal diseases that affect both the bony skeleton and soft tissues, in particular, have resulted in an enormous demand for trained musculoskeletal radiologists possessing highly specific detailed knowledge of musculoskeletal anatomy and disease processes⁽¹⁾. MR imaging is now the imaging method of choice for the depiction of muscles, tendons, ligaments, cartilage, and knee menisci. MR imaging is exquisitely sensitive to changes in the bone marrow, and is superior to CT in demonstrating soft tissue anatomical detail, providing superior soft tissue contrast and resolution in a multiplanar fashion⁽²⁾.

Although replaced by MR imaging for many of its previous indications, CT still has an important role in imaging the musculoskeletal system. Recent advances in CT technology, particularly spiral CT, have enabled decreased scan times, and optimized manipulation and reformation of imaging data to provide multiplanar and three-dimensional images⁽³⁾. The strength of CT lies in its ability to accurately depict subtle bony abnormalities and calcifications, and cross-sectional display of complex-shaped bony structures and their relationships to adjacent organs⁽³⁾. Musculoskeletal ultrasonography has recently increased in popularity due to the advent of high-frequency transducers allowing markedly improved image resolution, relatively low cost, wide availability, portability, and real-time imaging capability. Indications for ultrasonography include evaluating tendon abnormalities, the carpal tunnel syndrome, joint effusion, developmental hip dysplasia, and suspected foreign bodies, infections and masses of the soft tissues⁽⁴⁾. Bone scintigraphy is still one of the most frequently-performed nuclear medicine procedures, and is highly sensitive in providing information about the physiological response of bone to lesions such as tumour, infection, mechanical stress and trauma.

Given all these fine qualities of modern techniques in imaging of the musculoskeletal system, what then is the role of the humble radiograph? There is near-universal agreement among musculoskeletal radiologists that the initial imaging evaluation of the majority of suspected musculoskeletal abnormalities should begin with routine radiography. Radiographs as the initial imaging method is most appropriately performed when there is a history of trauma, suspected infection, suspected bone and soft tissue tumours, progressive disability, monoarticular joint involvement, for baseline assessment of chronic processes, and in the evaluation of bony lesions following therapy. Radiographs are widely available, cheap, technically easy to perform, acceptable as a screening tool, and are able to provide sufficient

Department of
Diagnostic Radiology
Singapore General
Hospital
Outram Road
Singapore 169608


W C G Peh, MD,
FRCP (Edin & Glasg),
FRCR
Clinical Professor and
Academic Head

Correspondence to:
Prof W C G Peh
Tel: (65) 6326 6908
Fax: (65) 6326 5161
Email: gdrpcg@
sgh.com.sg

information for diagnosis in most bone abnormalities. In the diagnosis of fractures of long bones, for example, radiographs suffice in the vast majority of cases, without the need for more sophisticated imaging methods. Radiographs alone are also often sufficient for classification, monitoring treatment, healing, and assessment of potential complications of these fractures.

Radiography has an essential role in complementing the inherent weaknesses of modern imaging techniques. Radiographs provide a global picture of suspected lesions. For example, the diagnosis of established rheumatoid arthritis is made by the radiographical findings of the symmetrical and bilateral distribution of periarticular erosions at specific joints in the hands and feet; and Paget's disease can be diagnosed by the radiographical presence of bony sclerosis, expansion, and cortical thickening in typically-affected bones. The distribution and multifaceted appearance of skeletal dysplasias in infancy are best evaluated using radiography. It may be difficult or impossible to confidently arrive at these diagnoses on either MR imaging or bone scintigraphy alone. Radiographs remain the single most reliable single imaging technique for assessing the biological activity, grade, and probable histological diagnosis of bone tumours and tumour-like conditions of bone. Changes in the tumour matrix, periosteum and cortex, and the presence of calcifications are well-demonstrated on radiographs. Radiographs are the best imaging modality for determining the degree of the aggressiveness or non-aggressiveness of a suspected bony tumour, providing a firm diagnosis or shortlist of differential diagnosis, and guidance of subsequent clinical management⁽⁵⁾.

The radiological evaluation of a suspected soft tissue mass also begins with radiography. Besides diagnosing an underlying bony lesion masquerading as a palpable soft tissue mass, radiographs may reveal soft tissue calcification or ossification that may be characteristic of a specific diagnosis. For example, radiographs may show the phleboliths within a haemangioma, juxta-articular osteocartilaginous masses of synovial osteochondromatosis, and peripherally-mature ossification of myositis ossificans^(6,7). These soft tissue calcifications and ossifications may be difficult to demonstrate with certainty on either MR imaging or bone scintigraphy. For suspected musculoskeletal and spine infections, radiographs should be performed first and may by itself be sufficient. They complement and serve to guide and direct further imaging⁽⁸⁾.

In summary, radiography currently has a definite and important role in imaging of the musculoskeletal system. Radiographs are complementary to the various modern imaging techniques used to assess musculoskeletal disorders. One however needs to be aware of the strengths and weaknesses of all these imaging techniques, in order to optimize investigation of the patient's presenting problems. 

REFERENCES

1. Rogers LF. From the editor's notebook. Yin and yang: the paradox of advances in imaging. *Am J Roentgenol* 2001; 176:841.
2. Ehman RL, Berquist TH, McLeod RA. MR imaging of the musculoskeletal system: a 5-year appraisal. *Radiology* 1988; 166:313-20.
3. Pretorius ES, Fishman EK. Helical (spiral) CT of the musculoskeletal system. *Radiol Clin North Am* 1995; 33:949-79.
4. Wang SC, Chhem RK, Cardinal E, Cho KH. Joint sonography. *Radiol Clin North Am* 1999; 37:653-68.
5. Peh WCG, Gilula LA. Plain film approach to tumours and tumour-like conditions of bone. *Br J Hosp Med* 1995; 54:549-57.
6. Kransdorf MJ, Murphey MD. Radiologic evaluation of soft-tissue masses: a current perspective. *Am J Roentgenol* 2000; 175:575-87.
7. Bianchi S, Martinoli C. Detection of loose bodies in joints. *Radiol Clin North Am* 1999; 37:679-90.
8. Turpin S, Lambert R. Role of scintigraphy in musculoskeletal and spinal infections. *Radiol Clin North Am* 2001; 39:169-89.

Publisher

Singapore Medical Journal
Level 2, Alumni Medical Centre
2 College Road
Singapore 169850
Tel: 6223 1264
Fax: 6224 7827
URL <http://www.sma.org.sg>

Design and Advertising

Lancer Communications Pte Ltd
69 Spottiswoode Park Road
Singapore 088659
Tel: 6324 4337
Fax: 6324 4661
Email: studio@lancer.com.sg

For advertising placement,
call or email

- Charlie Teo at
Tel: 6324 4337
Email: charlie@lancer.com.sg

Printed by Entraco Printing Pte Ltd

The Singapore Medical Journal is published monthly by the Singapore Medical Association. All articles published, including editorials, letters and book reviews represent the opinion of the authors and do not reflect the official policy of the SMA or Institution with which the authors are affiliated unless this is clearly specified. The Publisher cannot accept responsibility for the correctness or accuracy of the advertisers' text and/or claim or any opinion expressed. The appearance of advertisements in the Journal does not necessarily constitute an approval or endorsement by the SMA of the product or service advertised. The contents of this publication are not to be quoted in the press without permission of the Editor.