

## Clinics in Diagnostic Imaging (85)

ST Quek, S Poddar, J B K Khoo

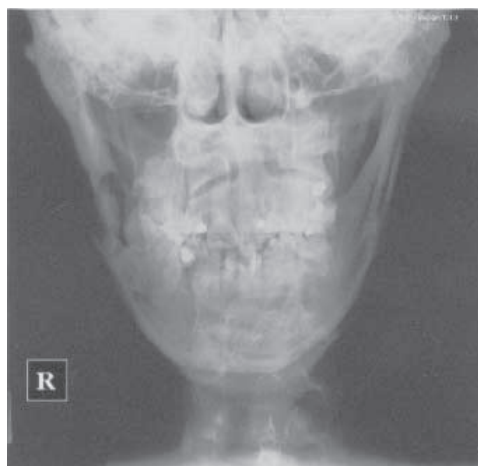


Fig. 1 Frontal radiograph of the mandible.

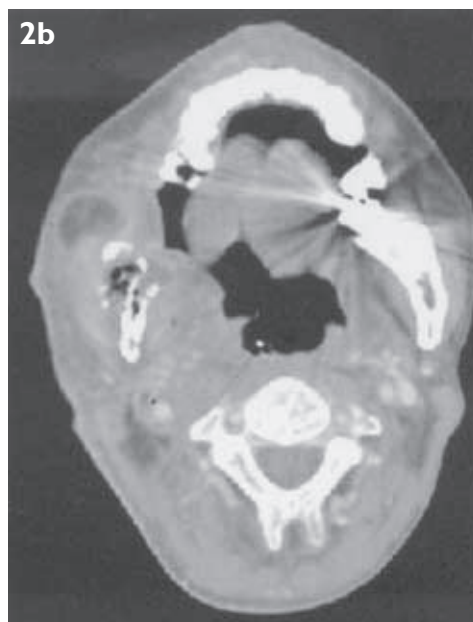
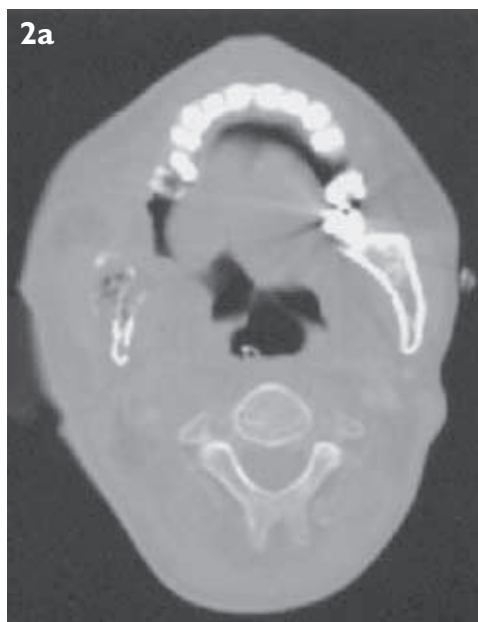

Fig. 2 Enhanced axial CT scans of the mandible taken with (a) bone and (b) soft tissue settings.

### CASE PRESENTATION

A 42-year-old man presented with a painful jaw. He had a past history of nasopharyngeal carcinoma (NPC), and had been treated by irradiation two and a half years ago. On physical examination, there was swelling and a discharging sinus over the right side of the mandible. Radiographs of the mandible were

obtained (Fig. 1). This was followed by computed tomography (CT) of the mandible (Figs. 2a and b). Technetium {Tc}-99m methylene diphosphonate (MDP) bone scintiscans were unremarkable apart from a solitary area of increased uptake in the right mandible. What do the radiograph and CT show? What is your diagnosis?

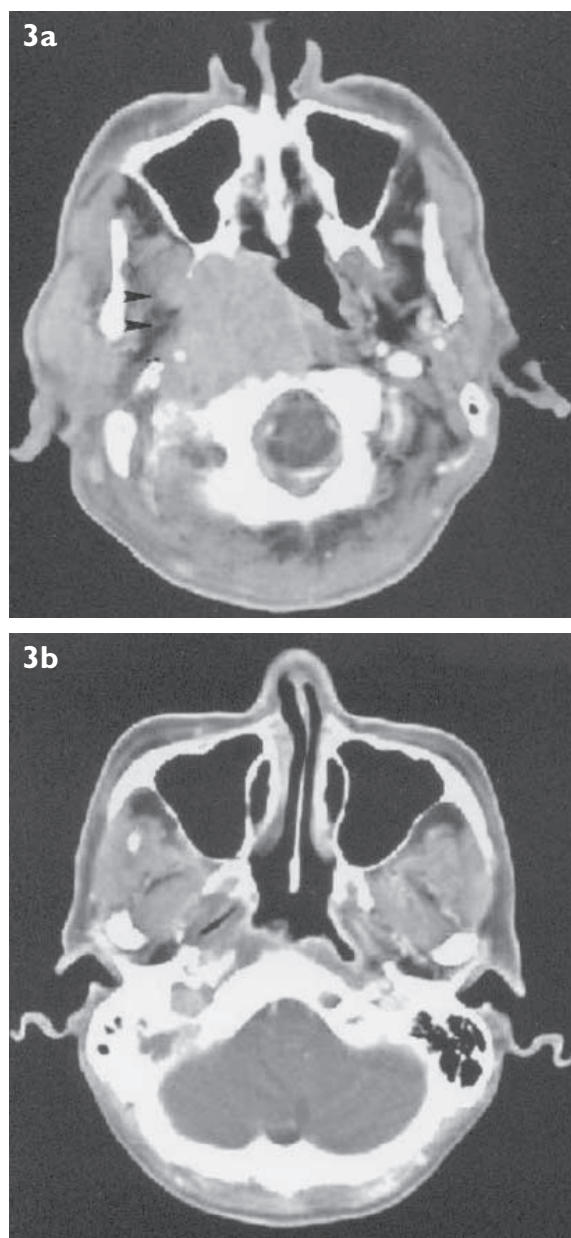
Department of  
Diagnostic Imaging  
National Cancer  
Centre  
11 Hospital Drive  
Singapore 169610

S T Quek,  
MBBS, FRCR  
Consultant

S Poddar,  
MBBS, MMed  
Fellow

K B K Khoo, MBBS,  
FRCR, FAMS  
Senior Consultant

Correspondence to:  
Dr S T Quek  
Tel: (65) 6436 8367  
Fax: (65) 6226 5660  
Email: ddiqst@  
nccs.com.sg



**Fig. 3** Enhanced axial CT scans taken (a) pre- and (b) post-treatment show the bulky tumour mass with extension into the right parapharyngeal space (arrowheads) at the time of initial presentation and its subsequent resolution post-radiation therapy.

#### IMAGE INTERPRETATION

The frontal radiograph (Fig. 1) shows osteolytic destruction of the right angle of the mandible. There is a wide zone of transition with breach of the overlying cortex. The clinically-visible soft tissue swelling is not well appreciated radiographically. Radiographical findings alone are suggestive of an aggressive bony lesion, possibly due to metastasis, infection or osteonecrosis. CT (Fig. 2a) confirms bony destruction and fragmentation. The soft tissue swelling is better appreciated, on the enhanced CT image (Fig. 2b) obtained with soft tissue settings. There is heterogeneous enhancement with a large rim-enhancing lesion in the adjacent soft tissues,

with several small pockets of gas at the site of bony destruction, consistent with infective changes.

The unusual location and absence of other bony lesions elsewhere in the skeleton makes metastasis unlikely. Given the history of previously-treated NPC (Fig. 3), site of the lesion and CT features of bony destruction and fragmentation, the likely diagnosis is mandibular osteoradionecrosis. Imaging findings of pockets of gas, soft tissue swelling and abscess are consistent with those of secondary soft tissue infection and osteomyelitis.

#### DIAGNOSIS

Mandible osteoradionecrosis complicated by infection.

#### CLINICAL COURSE

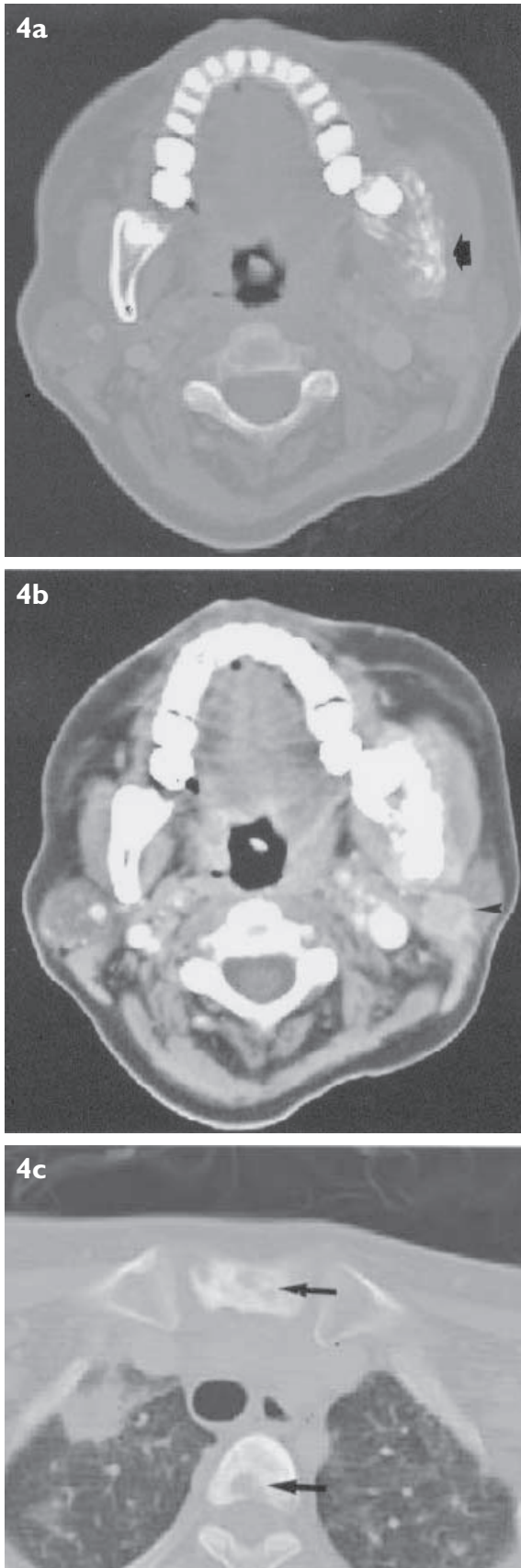
These imaging findings were confirmed on biopsy. The patient was started on a course of antibiotics and surgical debridement was also performed. Clinically, he responded well to treatment, with improvement of his presenting symptoms.

#### DISCUSSION

Although rare in most parts of the world with an age-adjusted incidence of less than 1 per 100,000, NPC is not uncommon among Chinese, in particular the Cantonese-speaking residents of southern China. Given the large Chinese population in Singapore, there is a correspondingly high incidence of NPC locally. In the period from 1993 to 1997, NPC ranked as the fifth most common cancer among men and tenth most common among women in Singapore, with 1,121 and 395 new cases reported, respectively<sup>(1)</sup>. The incidence rises in the second decade to reach a peak in the fourth decade, with a male preponderance of 2.5:1.

Due to the highly radiosensitive nature of the tumour, radiation therapy is the treatment modality of choice. A rare but well-known complication of this modality of treatment is the development of mandibular osteoradionecrosis (ORN). This may or may not be associated with secondary osteomyelitis. ORN of the mandible is diagnosed when there is radiological evidence of bone necrosis within the radiation field and when tumour recurrence has been excluded<sup>(2)</sup>. In NPC patients following radiation therapy, the usual site of involvement is at the angle of the mandible that is usually included in the radiation portal.

The pathophysiology of ORN is complex and not fully understood to date. It is however believed to be related to the metabolic and homeostatic deficiencies that result from radiation-induced



**Fig. 4** Example of mandibular metastases in NPC. Enhanced axial CT scans of the mandible taken with (a) bone and (b) soft tissue settings show bony destruction (arrow). There is however also an associated enlarged intra-parotid node (arrowhead) due to nodal metastasis. (c) Axial CT scan of the upper thorax shows mixed lytic-sclerotic bony metastases in the vertebra and sternum (long arrows). There is also a right apical pulmonary metastasis.

cellular injury and fibrosis<sup>(3)</sup>. The irradiated bone is hypoxic, hypovascular and hypocellular. There is consequent reduction of its nutrient supply rendering it incapable of meeting its normal metabolic requirements. It is therefore unable to adequately replace the collagen and cellular components that are lost through routine wear and tear resulting in tissue breakdown, infection, and formation of a chronic non-healing wound.

A number of factors influence the development of ORN. The more important of these include the size and anatomical location of the tumour, amount of radiation received, mode of radiation delivery, time interval after treatment, prior surgery and dental status<sup>(4)</sup>. In our patient, the predisposing factor was probably the large size of the primary tumour with extension into the paranasopharyngeal space (Figs. 3a-b) requiring him to have an extra radiation dose of 10 Grays (Gy)/week (parapharyngeal boost) in addition to the standard dose of 70 Gy over five weeks.

The usual clinical presentation of mandibular ORN is pain and swelling, similar to features in our patient. Other manifestations include oro-cutaneous fistula, suppuration, exposed necrotic bone and pathological fracture. Radiographs may show bone destruction with or without associated soft tissue swelling but early changes are often subtle and may be difficult to appreciate. Lack of lesion progression in serial radiographs favours ORN. CT is a more sensitive imaging modality compared to radiographs. It is able to demonstrate cortical disruption and loss of trabeculation in the affected bone, as well as any associated soft tissue swelling<sup>(5,6)</sup>. A pathological fracture may also be present. These changes are typically seen at the angle of the mandible although involvement of the mandibular body (premolar or molar) and retromolar triangle has also been reported. ORN may also occur in the maxilla although it is much less common<sup>(6)</sup>. This is believed to be due to the relative decreased vascularity and increased bone density of the mandible, as well as the fact that it often receives a greater radiation dose than the maxilla.

Bone scintigraphy shows increased isotope uptake in the affected portion of the mandible, with a high sensitivity of close to 100%. Use of single photon emission computed tomography (SPECT) also enables imaging in different planes, allowing better evaluation of the site and extent of involvement. The reported specificity of 57% is however low<sup>(7)</sup>, as metastasis or more commonly, periodontitis, may also result in increased isotope



uptake. Nonetheless, it may be useful in excluding the presence of lesions elsewhere in the skeleton, particularly metastases.

Magnetic resonance (MR) imaging has also been shown to be useful in the early diagnosis of radiation osteomyelitis, but false positives have been reported<sup>(7)</sup>. MR imaging changes that reflect bone oedema and co-existing soft tissue inflammatory reaction are also better seen than on scintigraphy or CT<sup>(8)</sup>. Positron emission tomography (PET) is useful in distinguishing tumour recurrence from conditions such as post-irradiation fibrosis. Intense uptake of 18-fluoro deoxyglucose (FDG) is seen in tumour recurrence<sup>(9)</sup> but there is little reported experience of its application in mandibular ORN.

While the imaging findings may be suggestive of the diagnosis, they are by no means pathognomonic. Other considerations include metastasis or more rarely, local invasion or radiation-induced sarcoma. Because of the similarity in clinical presentation of these different entities and the differences in their management and prognosis, careful imaging application and interpretation is necessary in order to exclude metastasis or tumour recurrence.

Although the skeletal system is the most common site of distant metastases in NPC<sup>(10,11)</sup>, spread is usually to the axial skeleton and long bones. Thus, mandibular metastasis, when present, is usually seen in association with metastasis to other parts of the skeleton. There may also be metastases to other areas in the body e.g. cervical nodes (Figs. 4a-c). Localised metastasis to the mandible is extremely rare. Hence, if a bone scintiscan shows the mandible to be the only site of involvement, it strongly favours the diagnosis of mandibular ORN.

Absence of recurrence at the primary site, i.e. the nasopharynx, as well as lack of an associated soft tissue mass in the mandible and no cervical lymphadenopathy are key factors that help exclude local invasion. It should also be remembered that cervical adenopathy may be encountered in cases of ORN complicated by osteomyelitis and is by itself not a feature against the diagnosis of ORN. Radiation-induced sarcoma is rarely seen with doses of less than 50 – 60 Gy. In the treatment of NPC, where the average radiation dose is in the region of 70 Gy and is high enough to cause radiation-induced sarcomas, ORN rarely occurs within 10 years post-treatment. Knowledge of the time course of events is thus useful. Where doubt still exists, a biopsy may be necessary.

Treatment of ORN is often instituted only when the patient is symptomatic. When it is complicated

by infection, with or without a discharging sinus, antibiotics and surgery are usually required. Hyperbaric oxygen therapy is also recognised as an adjuvant treatment and has been used prophylactically in patients at risk of mandibular ORN and who require dental extraction.

## CONCLUSION

Mandibular osteoradionecrosis is a rare but well-established complication in patients with head and neck tumours following radiation therapy. It is usually seen 1.5 to 3 years post-treatment and often occurs at the angle of the mandible. Osteomyelitis is a recognised associated complication. CT and radiographs of the mandible are useful tools to corroborate the clinical findings, and in differentiating this entity from tumour recurrence and metastasis.

## ABSTRACT

**Mandibular osteoradionecrosis is a rare but well-known complication that may be seen in patients with head and neck tumours following radiation therapy. A 42-year-old man presented with painful soft tissue swelling and a discharging sinus over the right mandible. Radiographs showed osteolytic destruction. Computed tomography confirmed bony destruction and fragmentation, as well as signs of soft tissue infection. The diagnosis of mandible osteoradionecrosis complicated by infection was confirmed by biopsy and surgically. The clinical and imaging features of osteoradionecrosis are highlighted.**

**Keywords:** nasopharyngeal carcinoma, osteoradionecrosis, mandible, radiation therapy, osteomyelitis

*Singapore Med J 2003 Vol 44(5):269-273*

## REFERENCES

1. Chia KS, Seow A, Lee HP, Shanmugaratnam K. Cancer incidence in Singapore 1993-1997. Singapore Cancer Registry 2000; 12-4.
2. Store G, Boysen M. Mandibular osteoradionecrosis: clinical behaviour and diagnostic aspects. Clin Otolaryngol 2000; 25:378-84.
3. Lim AA, Karakla DW, Watkins DV. Osteoradionecrosis of the cervical vertebrae and occipital bone: a case report and brief review of the literature. Am J Otolaryngol 1999; 20:408-11.
4. Curi MM, Dib LL. Osteoradionecrosis of the jaws: a retrospective study of the background factors and treatment in 104 cases. J Oral Maxillofacial Surg 1997; 55:540-4.
5. Hermans R, Fossion E, Ioannides C, Van den Bogaert W, Ghekiere J, Baert AL. CT findings in osteoradionecrosis of the mandible. Skeletal Radiol 1996; 25:31-6.
6. Peh WCG, Sham JST. Imaging of maxillary osteoradionecrosis. Australas Radiol 1997; 41:132-6.
7. Bachmann G, Rossler R, Klett R, Rau WS, Bauer R. The role of magnetic resonance imaging and scintigraphy in the diagnosis of pathologic changes of the mandible after radiation therapy. Int J Oral Maxillofac Surg 1996; 25:189-95.

8. Reinert S, Widlitzek H, Venderink DJ. The value of magnetic resonance imaging in the diagnosis of mandibular osteomyelitis. *Br J Oral Maxillofac Surg* 1999; 37:459-63.
9. Minn H, Aitasalo K, Happonen RP. Detection of cancer recurrence in irradiated mandible using positron emission tomography. *Eur Arch Otorhinolaryngol* 1993; 250:312-5.
10. Merino OR, Lindberg RD, Fletcher GH. An analysis of distant metastasis from squamous cell carcinoma of the upper respiratory and digestive tracts. *Cancer* 1977; 40:145-51.
11. Sham JST, Cheung YK, Chan FL, Choy D. Nasopharyngeal carcinoma: pattern of skeletal metastases. *Br J Radiol* 1990; 63:202-5.

#### **ERRATUM**

In the article "Audit of Transthoracic Fine Needle Aspiration of the Lung: Cytological Subclassification of Bronchogenic Carcinomas and Diagnosis of Tuberculosis" in the November 2002 SMJ, S C Wang's place of work should be "Department of Diagnostic Radiology".