

# Isolated tricuspid valve vegetations and steno-insufficiency in primary antiphospholipid syndrome

J K C Yoong, F R Jaufeerally

## ABSTRACT

**Although cardiac valve disease is frequent in the antiphospholipid syndrome, isolated tricuspid valve pathology is uncommon and tricuspid valve steno-insufficiency with concomitant vegetations in association with primary antiphospholipid syndrome has very rarely been mentioned in the literature. We describe a 54-year-old Indian woman with newly-diagnosed antiphospholipid syndrome and isolated tricuspid valve disease, the nature of which was only discernible by transoesophageal echocardiography. This case report highlights the importance of being aware of antiphospholipid syndrome as the possible underlying diagnosis in isolated organic tricuspid valve disease and the need for transoesophageal echocardiography in such cases.**

**Keywords:** antiphospholipid syndrome, cardiac valve, systemic lupus erythematosus, tricuspid valve

*Singapore Med J 2004 Vol 45(3):127-129*

## INTRODUCTION

Antiphospholipid syndrome (APS) is characterised by the presence of antiphospholipid (aPL) antibodies and one of the following: venous and/or arterial thromboses, recurrent foetal loss, or thrombocytopenia<sup>(1)</sup>. Other features include the development of livedo reticularis, and neurological and cardiac sequelae. APS occurs as a primary syndrome, primary antiphospholipid syndrome (PAPS), or secondary to an underlying disorder such as systemic lupus erythematosus (SLE). Cardiac lesions which are usually associated with APS are mitral and aortic valve disease when non-infective vegetations are also sometimes present. Tricuspid valve lesions in PAPS are rare and have only recently been reported<sup>(2)</sup>. Other cardiac sequelae of APS include atrial/ventricular thrombus, pericardial effusion and myocardial infarction despite normal coronary arteries. This suggests disease at microvascular level. The mechanism of development of cardiac valve lesions in APS is unknown but there is evidence in the literature to suggest that the presence

of aPL is associated with a higher prevalence of valvular abnormalities<sup>(3-5)</sup>.

## CASE REPORT

A 54-year-old Indian woman was admitted with a three-month history of increasing dyspnoea, orthopnoea, and painless swelling of both legs. She had intermittent right-sided pleuritic chest pains which were increasing in frequency and intensity. Effort tolerance was reduced from being able to walk up two flights of stairs previously, to being dyspnoeic at rest on admission. She did not complain of any cough, fever, night sweats or weight loss, and her appetite was normal. She had six healthy adult children but had one miscarriage during her second pregnancy. Past medical history included hypertension which was diagnosed a few years earlier. There was no family history of note.

On physical examination, she was well nourished, afebrile but tachypnoeic with a respiratory rate of 24/minute. Her pulse rate was 84/minute, and blood pressure was 140/90 mmHg. Pulse oximetry showed an oxygen saturation of 85% on room air. The apex beat was not displaced, and the first and second heart sounds were normal with a soft systolic murmur heard along the left sternal border. There were reduced breath sounds and basal crepitations over both lungs. Jugular venous pressure was pulsatile and raised at 6 cm. She had bilateral pitting ankle oedema with no calf or leg tenderness or warmth. The physical examination was otherwise unremarkable. She had no rash or any needle puncture marks, and there was no stigmata of infective endocarditis.

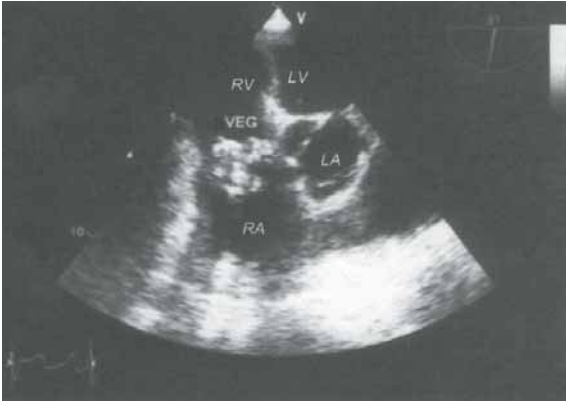
ECG showed a sinus rhythm with a P wave of 0.25mV in lead II. Chest radiograph revealed a mildly-enlarged heart, pulmonary congestion and minimal bilateral pleural effusions. Laboratory tests showed thrombocytopenia ( $72 \times 10^9/L$ ), total white blood cell count of  $7.10 \times 10^9/L$  with a normal differential count, and haemoglobin of 14.7 g/dL. The activated partial thromboplastin time (aPTT) was prolonged at 67.4 seconds, which remained elevated despite addition of normal plasma. Prothrombin time was within normal limits, erythrocyte sedimentation rate

Department of  
Internal Medicine  
Singapore General  
Hospital  
Outram Road  
Singapore 169608

J K C Yoong,  
MBChB, MRCP  
Registrar

F R Jaufeerally,  
BSc, Dip Neurosci,  
FRCP  
Consultant

Correspondence to:  
Dr Jon K C Yoong  
Tel: (65) 6321 4976  
Fax: (65) 6225 3931  
Email: jonyoong@  
yahoo.com



**Fig. 1** Transoesophageal echocardiogram shows tricuspid valve vegetations (Key: VEG: vegetations, RV: right ventricle, RA: right atrium, LV: left ventricle, LA: left atrium).

was 40 mm/hr, C-reactive protein was 1.5 mg/L, anticardiolipin antibody of IgG subtype was strongly positive with a titre of more than 150 GPL, while IgM subtype was medium positive at 24.3 MPL. Lupus anticoagulant was demonstrated, antinuclear and dsDNA antibodies were positive, extractable nuclear antigen screen was negative, and antistreptolysin O test was negative. Four sets of blood cultures obtained from different sites taken at least one hour apart on two consecutive days were sterile. Urine microscopy showed no red cells, urinary 5-hydroxy-indole-acetic acid was normal, and myeloma screen and tumour markers panel were negative. She remained afebrile throughout her stay in hospital.

Duplex ultrasonography of the lower limb veins revealed extensive bilateral chronic deep venous thromboses. Ventilation-perfusion scintiscans of the lungs showed multiple moderate to large-sized ventilation-perfusion mismatched defects involving the left upper and lower lobes and the right lower lobe, consistent with a high probability of pulmonary emboli affecting both lungs. Transthoracic echocardiography showed an echogenic mass attached to the septal tricuspid valve leaflet. The leaflets were thickened. There was reduced opening with a gradient of 5 mmHg across the tricuspid valve and moderate regurgitation. With this modality, it was not possible to determine whether the mass was a myxoma or vegetations. There was also mild right atrium and ventricle dilatation. The left ventricle was hypertrophied but ejection fraction was satisfactory at 75%.

Transoesophageal echocardiography showed a 1 x 1.5 cm mass of variegated consistency, with well-shaped borders and areas of calcification, attached to the septal tricuspid valve leaflet (Fig. 1). Using this approach, a confident diagnosis that this was a chronic vegetation, as opposed to a myxoma, could be made. The other heart valves were entirely normal, and

the interatrial and interventricular septa were intact. There was no pericardial effusion.

Our patient was commenced on intravenous frusemide on admission, and subcutaneous low molecular weight heparin and prednisolone when APS was suspected, prior to starting warfarin. She was discharged after a two-week stay in hospital as she felt remarkably better. Her exercise tolerance improved back to normal, with an oxygen saturation of 98%. She has been reviewed in the outpatient clinic where she remained well and INR maintained at a level between 3.0 and 3.5.

## DISCUSSION

In the case described, there was evidence of deep venous thromboses in both lower limbs with multiple pulmonary emboli, thrombocytopenia and a high titre of anticardiolipin (ACL) antibodies. Our patient fulfilled the APS criteria proposed by Asherson and Cervera<sup>(6)</sup>. A firm diagnosis of SLE was not made by the rheumatologists as she did not fulfil the American College of Rheumatology criteria. The transthoracic echocardiogram revealed tricuspid valve stenosis and insufficiency and vegetations which was confirmed and more clearly defined by transoesophageal echocardiography. There was no involvement of the other cardiac valves, which was unusual as isolated tricuspid valve lesions are rare. In this case, the tricuspid valve disease was significant enough to manifest clinically with a raised jugular venous pressure and dependent bilateral lower limb oedema which subsided with diuretic therapy. It is most likely that the tricuspid valve insufficiency was organic and not secondary to pulmonary hypertension as the pulmonary artery pressure was not raised.

The aetiological factors usually considered in isolated organic tricuspid valve lesions include infective endocarditis associated with intravenous drug abuse, carcinoid syndrome and rheumatic heart disease. However, these diagnoses were very unlikely as the clinical assessment and laboratory test results were not consistent. Antiphospholipid antibodies are a heterogeneous group of antibodies that have an affinity for phospholipid surfaces. These include anticardiolipin (ACL) antibodies, lupus anticoagulant (LA) and  $\beta$ 2-glycoprotein I. These bind to many antigens which are involved in blood coagulation.

The actual prevalence of APS in the population is unknown. It is an autoimmune disorder of unknown cause and can be divided into two groups: primary APS or secondary APS. The latter is APS secondary to an underlying disorder, including vasculitic disorders, HIV infection and commonly, systemic lupus erythematosus (SLE). aPL can be detected in as many

as 50% of patients with SLE but recent literature suggests that the occurrence rate of actual APS in patients with SLE is 34%-42%. Cardiac pathology is common in APS and up to 35% prevalence of valvular lesions involving the aortic and mitral valves has been reported by transthoracic echocardiography<sup>(7)</sup>. In a study by Turiel et al, up to 82% detection rate of cardiac valve lesions was achievable utilising transoesophageal echocardiography<sup>(8)</sup>. The data from this study also showed a significant correlation between the ACL titre, thromboembolic events and mitral valve thickening but not with tricuspid valve pathology as the numbers involving the tricuspid valve were too few to draw any statistically significant conclusions. However, data from a study by Metz et al did suggest that APS was significantly associated with increased relative risk for tricuspid valve disease<sup>(4)</sup>.

A prospective study by Bulckaen et al investigating the role of aPL in subsequent thromboembolic events suggested that patients with severe valvular heart disease and aPL have a significantly increased risk for developing thromboembolic events<sup>(9)</sup>. Interestingly, despite a large proportion of patients with APS having detectable cardiac valve lesions by either transthoracic or transoesophageal echocardiography, only up to 20% manifested clinically<sup>(10)</sup>.

Management of cardiac disease in APS remains controversial. A committee consensus report by Lockshin et al recommended guidelines for the treatment of cardiac disease in APS<sup>(11)</sup>. Anticoagulation with warfarin titrated to an INR of 3.0-3.5 and consultation with the cardiac surgeons was recommended for symptomatic patients with valvulopathy and/or intracardiac thrombus. In asymptomatic patients, prophylactic antiplatelet therapy such as aspirin and clopidogrel may be used but this is not evidence-based. The committee also recommended aggressive treatment of all risk factors for atherosclerosis (i.e. hypertension, hypercholesterolaemia, diabetes mellitus and smoking cessation). There was no recommendation made for the treatment of ventricular dysfunction in APS.

There is no evidence to support the use of prednisolone in cardiac disease unless an underlying vasculitic disorder is proven to be the cause of APS, although it can be used to treat thrombocytopenia in

this condition. Hydroxychloroquine may be considered in APS secondary to SLE but again, this is not evidence-based. Our patient will be followed up for anticoagulation control and possible development of the other signs and symptoms that may point towards SLE or any other underlying disorder.

In conclusion, the patient presented with overt clinical signs of tricuspid valve disease with pulmonary emboli attributed to APS. This case report serves to remind clinicians to consider APS as an underlying diagnosis in cases of isolated organic tricuspid valve lesions, which do not often manifest clinically, or indeed any cardiac disease unaccounted for in the setting of thromboses and thrombocytopenia. In addition, this case illustrates the value of transoesophageal echocardiography in defining the exact nature of cardiac valve and chamber pathology in APS. Cases of PAPS may evolve to reveal an underlying disorder, and will therefore require long term follow-up.

## REFERENCES

1. Hughes GR. The antiphospholipid syndrome: ten years on. *Lancet* 1993; 342:341-4.
2. Turjanski AA, Finkelman JD, Vasquez-Blanco M. Isolated tricuspid valve disease in antiphospholipid syndrome. *Lupus* 1999; 8:474-6.
3. Khamashta MA, Cervera R, Asherson RA, Font J, Gil A, Coltart DJ, et al. Association of antibodies against phospholipids with heart valve disease in systemic lupus erythematosus. *Lupus* 1990; 6:1541-4.
4. Metz D, Jolly D, Graciet-Richard J, Nazeyrollas P, Chabert JP, Maillier B, et al. Prevalence of valvular involvement in systemic lupus erythematosus and association with antiphospholipid syndrome: a matched echocardiographic study. *Cardiology* 1994; 85:129-36.
5. Gentile R, Lagana B, Tubani L, Casato M, Ferri GM, Fedele F. Assessment of echocardiographic abnormalities in patients with systemic lupus erythematosus: correlation with levels of antiphospholipid antibodies. *Ital Heart J* 2000; 1:487-92.
6. Asherson RA, Cervera R. 'Primary', 'secondary' and other variants of the antiphospholipid syndrome. *Lupus* 1995; 4:3318-20.
7. Hojnik M, George J, Ziporen L, Shoenfeld Y. Heart valve involvement (Libman-Sacks endocarditis) in the antiphospholipid syndrome. *Circulation* 1996; 93:1579-87.
8. Turiel M, Muzzupappa S, Gottardi B, Crema C, Sarzi-Puttini P, Rossi E. Evaluation of cardiac abnormalities and embolic sources in primary antiphospholipid syndrome by transesophageal echocardiography. *Lupus* 2000; 9:406-12.
9. Bulckaen HG, Puisieux FL, Bulckaen ED, Di Pompeo C, Bouillanne OM, Watel AA, et al. Antiphospholipid antibodies and the risk of thromboembolic events in valvular heart disease. *Mayo Clin Prac* 2003; 78:294-8.
10. NM Shah, MA Khamashta, T Atsumi, GRV Hughes. Outcome of patients with anticardiolipin antibodies: a 10 year follow-up of 52 patients. *Lupus* 1998; 7:3-6.
11. Lockshin M, Tenedios F, Petri M, McCarty G, Forastiero, Krillis S, et al. Cardiac disease in the antiphospholipid syndrome: recommendations for treatment. Committee consensus report. *Lupus* 2003; 12:518-23.