

# C7 fracture treated with a pedicle screw system under navigation guidance

T Mahadewa, J Mizuno, T Inoue, H Nakagawa

## ABSTRACT

**A 51-year-old woman with traumatic fracture-subluxation of C6-C7 vertebrae was treated by pedicle screw fixation. Among several methods for surgical treatment of the cervical spine, this technique provides a more rigid anchor to prevent collapsing or instability of the spinal column, particularly at the cervicothoracic junction. However, the risk of injuring the adjacent neurovascular structures cannot be completely eliminated. The characteristics of the cervicothoracic junction, surgical approaches and pedicle screw fixation techniques are emphasised.**

**Keywords: C7 vertebral fracture, neuronavigation, pedicle screw, spinal instability, trauma**

*Singapore Med J 2004 Vol 45(10):489-493*

## INTRODUCTION

Surgical stabilisation of the unstable cervical spine can be achieved by using many techniques of spinal fixation. The procedures are indicated when disruption of the normal elements compromises the protective function of the spine and threatens neurological function<sup>(1,2)</sup>. There is no consensus regarding the use of anterior, posterior or combined approaches of the surgical procedure, especially in cases of fracture-subluxation of the cervicothoracic junction (CTJ). The transpedicular screw fixation has been reported for the treatment of cervical spine instability caused by trauma<sup>(3,4)</sup>. Although this technique has been reported by some authors for its superiority for fixation in cases of three-column instability, there is an increased possibility of injuring the vertebral arteries or the spinal nerve roots<sup>(5-8)</sup>. A case of cervical spinal instability secondary to a C6-C7 traumatic fracture-subluxation is reported, with pedicle screw fixation assisted by a neuronavigation system.

## CASE REPORT

A 51-year-old woman was admitted to our emergency room because of multiple organ injuries caused

by an automobile accident. Her injuries included traumatic brain subarachnoid haemorrhage, haemothorax, and multiple laceration wounds on the scalp and face. Neurological examination revealed a stuporous conscious state with paraparesis and positive Babinski reflex on the left side. Cervical radiographs showed swelling of the retrotracheal soft tissue and a superior C7 vertebral body fracture (Fig. 1a). Axial and three-dimensional computed tomography (CT) confirmed a C7 fracture involving the lateral mass and vertebral body on the right side and C6-7 subluxation (Figs. 1b-c). Magnetic resonance (MR) imaging revealed the presence of intramedullary high signal intensity on the T2-weighted image and rupture of the C6-7 interspinous ligament (Figs. 1d-e). Vertebral angiography showed no occlusion or displacement.

The patient underwent pedicle screw fixation from C6 to T1 levels. The neuronavigation system, Medtronic Stealth-Station (Sofamor Danek, Tennessee, USA), was used in addition to fluoroscopy, to avoid damaging the vertebral artery during screwing. Under general anaesthesia, the patient was placed in prone position. After midline bilateral subperiosteal dissection, the spinous processes, laminae, facet joints and transverse processes of C6 to T1 vertebrae were exposed. The fractured lateral mass of the right side of C7 vertebra was identified. After introducing a neuronavigator, registration for pedicle screw of Steffee VSP (AcroMed Inc., Ohio, USA) was made at C7 vertebral level (Fig. 2).

The preplanned entry points for the pedicle screw at the left side of C7 vertebra were identified. Under fluoroscopy, the cancellous bone in the pedicle was pierced with a probe. The hole of the probe was then inducted with a depth gauge, which showed a depth of 35mm. At the right side of C7 vertebra, this procedure was not performed because of the presence of a fractured lateral mass. The same procedure was repeated on both C6 and T1 pedicles. Marking pins were then inserted to these five pedicles and their positions were confirmed with fluoroscopy. After good positioning

Department of  
Neurosurgery  
Padjadjaran  
University  
Hasan Sadikin  
General Hospital  
Jalan Pasteur 38  
Bandung 40161  
Indonesia

T Mahadewa,  
MD, FSNS  
Research and  
Spine Fellow

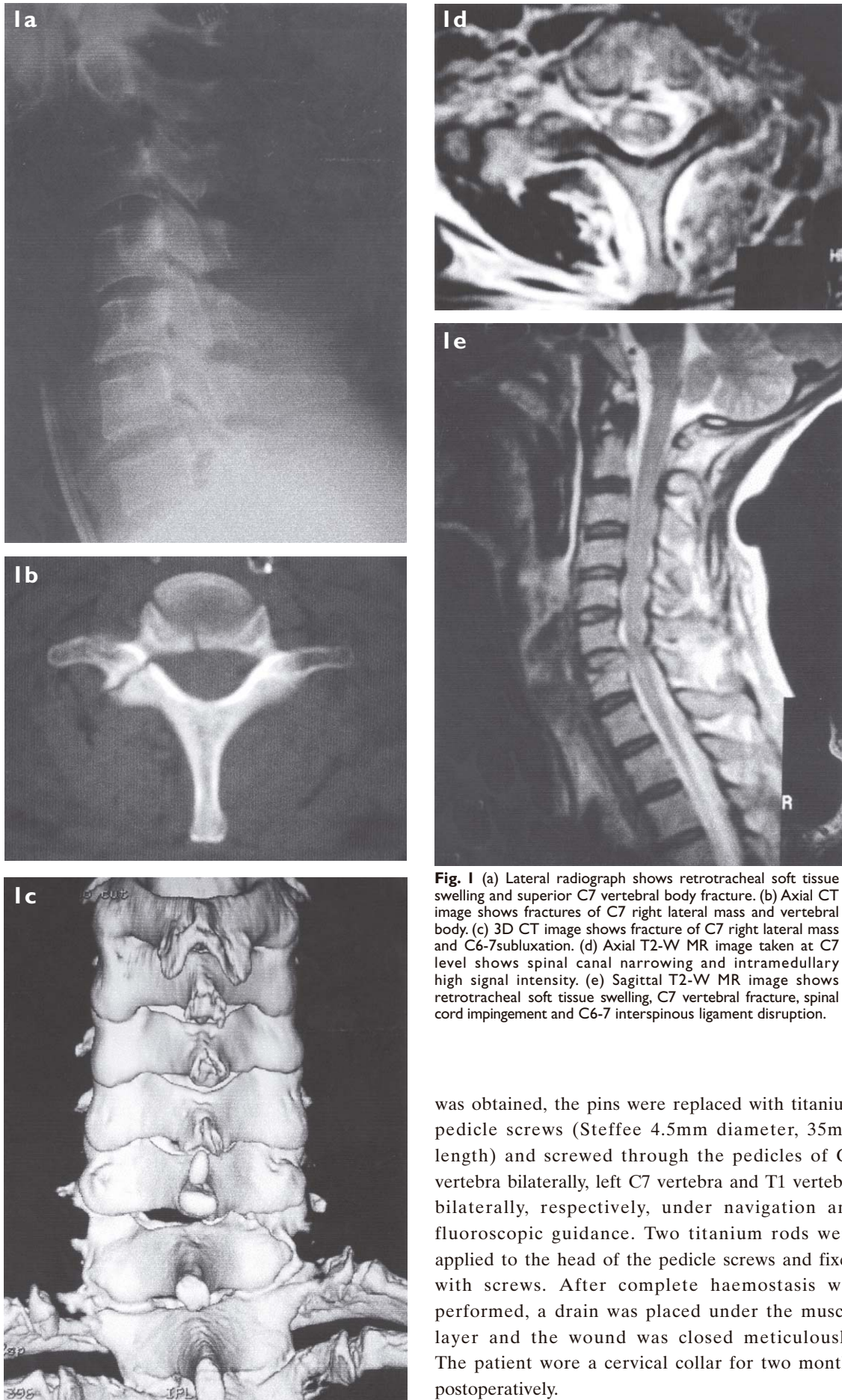
Department of  
Neurological  
Surgery  
Aichi Medical  
University  
Aichi, Japan

J Mizuno, MD, PhD  
Associate Professor

T Inoue, MD, PhD  
Assistant Professor

H Nakagawa,  
MD, PhD  
Professor and Head

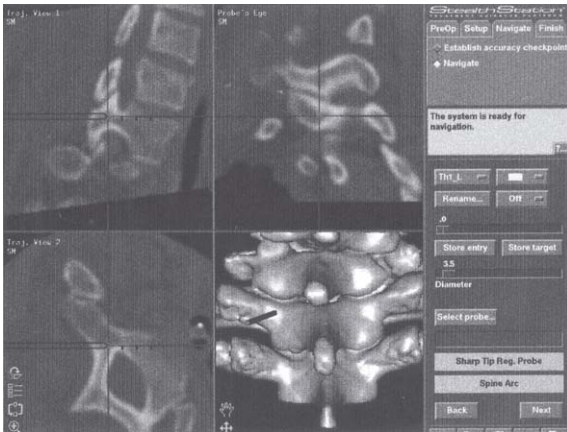
Correspondence to:  
Dr Tjokorda  
GB Mahadewa  
Tel: (62) 22 2035836  
Fax: (62) 22 2515416  
Email: tjokmahadewa  
@yahoo.com



**Fig. 1** (a) Lateral radiograph shows retrotracheal soft tissue swelling and superior C7 vertebral body fracture. (b) Axial CT image shows fractures of C7 right lateral mass and vertebral body. (c) 3D CT image shows fracture of C7 right lateral mass and C6-7 subluxation. (d) Axial T2-W MR image taken at C7 level shows spinal canal narrowing and intramedullary high signal intensity. (e) Sagittal T2-W MR image shows retrotracheal soft tissue swelling, C7 vertebral fracture, spinal cord impingement and C6-7 interspinous ligament disruption.

was obtained, the pins were replaced with titanium pedicle screws (Steffee 4.5mm diameter, 35mm length) and screwed through the pedicles of C6 vertebra bilaterally, left C7 vertebra and T1 vertebra bilaterally, respectively, under navigation and fluoroscopic guidance. Two titanium rods were applied to the head of the pedicle screws and fixed with screws. After complete haemostasis was performed, a drain was placed under the muscle layer and the wound was closed meticulously. The patient wore a cervical collar for two months postoperatively.





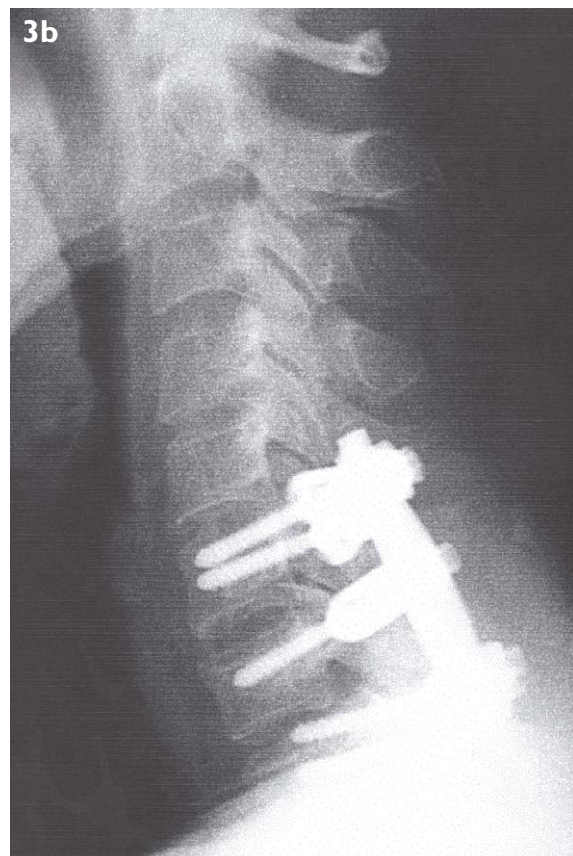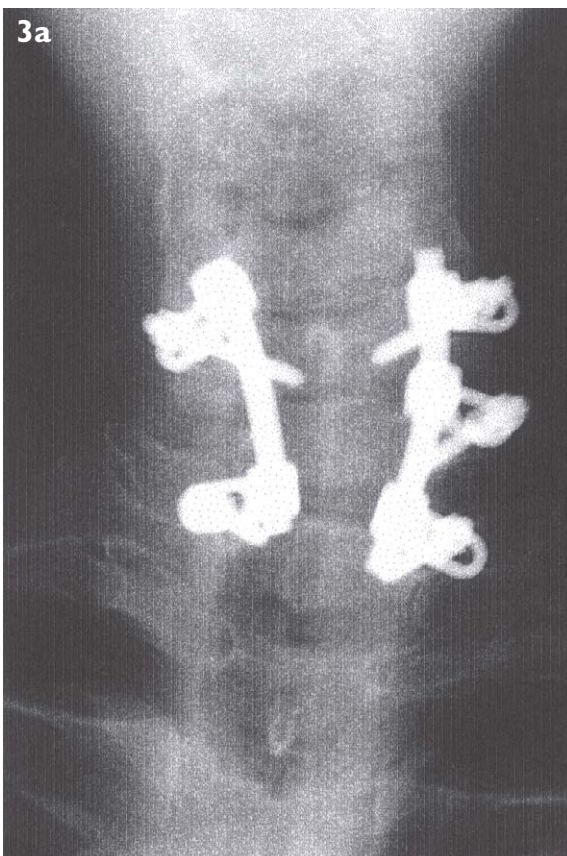
**Fig. 2** 3D CT images of the cervical spine on neuronavigator indicates the pedicle screw trajectory site at the left side of T1 vertebra.

The patient was referred to the rehabilitation centre, and underwent physical training for six months until she was able to walk unaided. Two weeks after surgery, cervical radiographs showed a reasonable restoration of the vertebral column without a further kyphotic deformity (Figs. 3a-b). Axial CT confirmed the placement of the pedicle screws into the C6-T1 vertebral bodies.

## DISCUSSION

The cervicothoracic junction (CTJ) is subjected to unique biomechanics in the spinal column, because it is in a transitional zone between the lordotic, mobile cervical spine and the kyphotic, more rigid thoracic spine<sup>(14)</sup>. Lesions occurring in this area, including traumatic injury, have a high propensity for causing instability and pose unique challenges in the surgical treatment<sup>(3,10,11)</sup>. The anterior approach to the CTJ is generally regarded as difficult<sup>(12)</sup>. This reputation is warranted because of the depth of the vertebral bodies (VBs) from the skin and the thoracic kyphosis which angles the VBs away from the surgeon<sup>(12)</sup>. Further complicating the approach are the nerves, lymphatic and vascular structures that cross the operative exposure in the upper mediastinum<sup>(9,12)</sup>.

Some form of extension should be performed to reach the thoracic VBs, including median sternotomy, manubrial resection, clavicular osteotomy or combination with thoracotomy<sup>(9,12)</sup>. This allows for adequate exposure of the ventral VBs as far caudal as T2 level. Gieger et al<sup>(12)</sup> also reported recurrent laryngeal nerve (RLN) palsies in their series. RLN has three portions. The descending portion may



**Fig. 3** (a) Frontal and (b) lateral cervical radiographs show reasonable alignment of the cervical spine after placement of pedicle screws and rods.

be injured if the dissection is not kept medially to the carotid sheath or by overvigorous carotid retraction, while the transverse and descending portions may be injured by retraction on the trachea and oesophagus.

The posterior approach could avoid those pitfalls described above. Posterior fixation devices have advantages over anterior devices for fixation of three-column instability<sup>(11,13)</sup>. Many surgical options are available for posterior spinal fixation, such as interspinous wiring, sublaminar wiring, laminar hooks, lateral mass and pedicle screw fixations<sup>(14-16)</sup>. For fixation of three-column instability, lateral mass and pedicle screw fixations could provide greater stabilisation than any other fixation procedures<sup>(13)</sup>.

Bueff et al<sup>(17)</sup> demonstrated, in an experimental study, that cervical pedicle screws provided more rigid stability than cervical lateral mass screws in fixation of the CTJ. The results of a recent comparative biomechanical study on the cervical spine by Jones et al<sup>(5)</sup> provided evidence of greater pullout strength of cervical pedicle screws than of lateral mass screws. Todd et al<sup>(16)</sup> reported that the lateral mass thickness decreases as the vertebrae descend the lower cervical spine. At C7 vertebral level, the lateral masses are small, so they often provide unsatisfactory fixation quality.

Conversely, its pedicles have relative bigger dimensions, allowing for bigger screw length insertion to improve pullout strength<sup>(14)</sup>. This increased rigidity allows for shorter construction length and decreased time in external orthoses<sup>(5-7,18-20)</sup>. This, therefore, led the authors to use pedicle screw fixation for this patient. However, it is technically demanding because of possible injuries of the vertebral arteries or the spinal nerve roots<sup>(13,21)</sup>. There has been considerable debate about the safety of pedicle screw placement in the lower cervical spine and upper thoracic spine, including the CTJ<sup>(4,22-26)</sup>. Lateral perforation of the pedicular cortex is a potential threat to the vertebral arteries at the cervical level, and to the pleural cavity at the thoracic level<sup>(16,21,22)</sup>.

The neuronavigation system together with an intraoperative fluoroscopy can minimise the risk of these complications<sup>(13,27,28)</sup>, particularly in cases of distorted cervical spine. The neuronavigator provides axial, coronal and sagittal views at the same time, something that could not be provided by fluoroscopy alone. Confirming the exact point of the screw penetration is critical, and the surgeons must pay great care because of the difficult orientation of the screw when advancing into the pedicle.

## REFERENCES

1. Abumi K, Itoh H, Taneichi H, Kaneda K. Transpedicular screw fixation for traumatic lesions of the middle and lower cervical spine: description of the techniques and preliminary report. *J Spinal Disord* 1994; 7:19-28.
2. Abumi K, Kaneda K. Transpedicular screw fixation for reconstruction of the cervical spine. Presented at the 62nd Meeting of the American Academy of Orthopedic Surgeons, Orlando, Florida, USA, February 18, 1995.
3. Cooper PR. Operative management of cervical spine injuries. *Clin Neurosurg* 1988; 34:650-74.
4. Hasan CU, Ayhan A, Aysun U, Ibrahim T, Nihat E, Sukru C, Yasemin G. Surgical anatomic evaluation of the cervical pedicle and adjacent neural structures. *Neurosurgery* 2000; 47:1162-9.
5. Jones EL, Heller JG, Silcox DH, Hutton WC. Cervical pedicle screw versus lateral mass screws: anatomic feasibility and biomechanical comparison. *Spine* 1997; 22:977-82.
6. Joseph MK, Steven CL, William CH, John GH. Cervical spine pedicle screws: a biomechanical comparison of two insertion techniques. *Spine* 2000; 25:2865-7.
7. Ladd JE, John GH, Hal SD, William CH. Cervical pedicle screws versus lateral mass screws: anatomic feasibility and biomechanical comparison. *Spine* 1997; 22:977-82.
8. Steven CL, David LK, Richard AB, Alexander RV, Kevin FF, Todd JA. Placement of pedicle screws in the human cadaveric cervical spine: comparative accuracy of three techniques. *Spine* 2000; 25:1655-67.
9. John AB, Matthew FP, Albert ET, Donald MO, Paul JM. Results and risk factors for anterior cervicothoracic junction surgery. *J Neurosurg* 2001; 94:12-17.
10. An HS, Vaccaro A, Cotler JM. Spinal disorders at the cervicothoracic junction. *Spine* 1994; 19:2557-64.
11. Chapman JR, Anderson PA, Pepin C. Posterior instrumentation of the unstable cervicothoracic spine. *J Neurosurg* 1996; 84:552-8.
12. Gieger M, Roth PA, Wu JK. The anterior cervical approach to the cervicothoracic junction: technique assessment. *Neurosurgery* 1995; 37:704-10.
13. Mizuno J, Hiroshi N, Takeya W. Combined anterior and posterior instrumentation in severe fracture-dislocation of the lower cervical spine with help of navigation: a case report. *J Clin Neurosci* 2000; 8:446-50.
14. Geoffrey MM, Steven RG. *Spine Update*. Cervical spine internal fixation using screw and screw-plate constructs. *Spine* 2000; 25:643-52.
15. Hisanori M, Boyle CC, Stephen MD, Katsuhiko Ohnari, Thomas AZ. Biomechanical comparison of posterior cervical fixation. *Spine* 2001; 26:1662-7.
16. Todd JA, Gregg RK, Denise J, Alexander RV. Use of cervicothoracic junction pedicle screws for reconstruction of complex cervical spine pathology. *Spine* 1998; 23:1596-9.
17. Bueff HU, Lotz JC, Colliou OK. Instrumentation of the cervicothoracic junction after destabilization. *Spine* 1995; 20:1789-92.
18. Abumi K, Panjabi MM, Duranceau J. Biomechanical evaluation of spinal fixation device. Part III. Stability provided by six spinal fixation devices and interbody bone graft. *Spine* 1989; 14:1249-55.
19. Coe JD, Warden KE, Sutterlin III CE, McAfee PC. Biomechanical evaluation of cervical stabilization methods in a human cadaveric model. *Spine* 1989; 14:1121-31.
20. Kotani Y, Cunningham BW, Abumi K, McAfee PC. Biomechanical analysis of cervical stabilization systems: an assessment of transpedicular screw fixation in the cervical spine. *Spine* 1994; 19:2529-39.
21. Kuniyoshi A, Yasuhiro S, Hiroshi T, Manabu I, Kiyoshi K. Complication of pedicle screw fixation in reconstructive surgery of the cervical spine. *Spine* 2000; 25:962-9.
22. Andrew SY, Douglas JQ, John EM, Stephen MP. Stereotactic navigation for placement of pedicle screws in the thoracic spine. *Neurosurgery* 2001; 48:771-9.

23. Manohar MP, Toyohiko O, Jaw LW. The effects of pedicle screw adjustments on neural spaces in burst fracture surgery. Spine 2000; 25:1637-43.
24. Neil DG, Richard WH, John AR. Computer-aided pedicle screw placement using frameless stereotaxis. Spine 1996; 21:2026-34.
25. Timo L, Dietrich S, Kirsti M, Kaj T, Lutz P, Heiko V. Improved accuracy of pedicle screw insertion with computer assisted surgery: a prospective clinical trial of 30 patients. Spine 1997; 22:1254-8.
26. William WC, Barth AG, Allan DOL. Computer assisted fluoroscopic targeting system for pedicle screw insertion. Neurosurgery 2001; 47:872-8.
27. Kuniyoshi A, Yasuhiro S, Hiroshi T, Manabu I, Kiyoshi K. Correction of cervical kyphosis using pedicle screw fixation systems. Spine 1999; 24:2389-96.
28. Raja RY, David AS, Kevin TF. Accuracy requirements for image-guided spinal pedicle screw placement. Spine 2001; 26:352-9.

## 2004 SMA ANNUAL GOLF CHAMPIONSHIP

The 2004 SMA ANNUAL GOLF CHAMPIONSHIP will be held on **27 October 2004 (Wednesday)** at **Laguna National Golf and Country Club (LNGCC), Classic Course.**

As usual, players can look forward to excellent prizes. There will also be a buffet dinner at 7.30pm, Eagle room, after the golf competition.

The entrance fee is \$160 for non-LNGCC members and \$100 for LNGCC members.

Kindly send your participation reply-slip by **13 October 2004.**

To: Ms Karen Teo  
 Singapore Medical Association  
 2 College Road, Level 2  
 Alumni Medical Centre  
 Singapore 169850

Fax: 6224 7827                      Email: karen@sma.org.sg

I wish to participate in the 2004 SMA Annual Golf Championship.

I am / am not \* a member of LNGCC                      My membership no. is \_\_\_\_\_

I am / am not \* a senior Golfer (above 55 years old). My handicap is \_\_\_\_\_

12:30pm - 1:00pm                       1:00 pm - 1:30pm

I enclose a cheque no. \_\_\_\_\_ made payable to "Singapore Medical Association" of \$160 (non-LNGCC member) / \$100 (LNGCC member) \*.

Name: \_\_\_\_\_                      Signature: \_\_\_\_\_

Address: \_\_\_\_\_

Tel: \_\_\_\_\_                      Fax / Email: \_\_\_\_\_

\* Delete where applicable.