

Successful management of a bleeding duodenal varix by endoscopic banding

N C Tan, S Ibrahim, K H Tay

ABSTRACT

Endoscopic treatment of bleeding duodenal varices is less invasive than the usual surgical options. However, there is limited experience with endoscopic treatment of bleeding duodenal varices, especially with that of endoscopic ligation. We report a 55-year-old man with a bleeding duodenal varix that was successfully ligated endoscopically. He has been followed up for nine months with no recurrence of bleeding. Endoscopic ligation may offer a new and effective treatment modality for bleeding duodenal varix.

Keywords: duodenal varix, endoscopic banding, endoscopy, gastrointestinal bleeding

Singapore Med J 2005; 46(12):723-725

INTRODUCTION

Haematemesis and melaena are common presentations among patients in the surgical department. Common causes include gastritis, peptic ulcer disease, oesophageal varices, Mallory-Weiss disease and gastric tumours. However, bleeding from a duodenal varix is rarely encountered and there is limited experience in treating it endoscopically. Endoscopic band ligation offers a fast and effective way to secure haemostasis and can be the treatment of choice in the future for bleeding duodenal varices.

CASE REPORT

A 55-year-old Malay man had a known history of Child's A liver cirrhosis secondary to chronic hepatitis B infection and alcoholism since the age of 16 years. Subsequently, he suffered from multiple episodes of gastrointestinal bleeding from his oesophageal varices and underwent a portal shunt and splenectomy in 1965. Post-surgery, his bleeding oesophageal varices recurred in 1999 and he underwent multiple episodes of band ligation and sclerotherapy.

On this admission, he presented initially at the emergency department with melaena for the past three days, together with haematemesis on two separate occasions. He was hypotensive (blood

pressure 76/54 mmHg) and tachycardic (pulse rate of 117 beats/minute) at the emergency room. His haemoglobin level had dropped from 14.8g% two weeks ago to 11.2g%. Fluid resuscitation, which included 2.0 L of crystalloids, 0.5 L of colloids and 1.0 L of blood, was quickly administered to stabilise the patient haemodynamically. An immediate gastroscopy was performed.

At gastroscopy, no bleeding oesophageal varices were seen. However, a spurting duodenal varix, approximately 1.5 cm in diameter, was found (Fig. 1). This bleeding duodenal varix was successfully band-ligated (Figs. 2 & 3). Technically, there was no difficulty in banding the duodenal varix after the blood clots were flushed away, though the varix was still spurting away. The transparent cap from the ligation device which was attached to the gastroscopy (Fig. 2) prevented blood and mucosa from obscuring the operator's view. Continuous insufflation of air into the duodenal lumen also gave ample space to ligate the varix easily.

Intravenous somatostatin was started from admission for a duration of five days but oral propranolol (β -blocker) was only commenced three days after the gastroscopy, when the patient started feeding. Subsequently, the patient remained haemodynamically stable and no repeat gastroscopy and banding was needed. He was finally discharged one week later with a stable haemoglobin level of about 10g%. The patient has been followed-up for the last one year with no signs and symptoms to suggest any recurrence of bleeding. However, no repeat gastroscopy was done due to patient's refusal until only recently (one year post-banding). The previous duodenal varix has totally regressed and only a duodenal scar was seen (Fig. 4).

DISCUSSION

Duodenal varices are rare, compared to oesophageal or gastric varices. Portal hypertension due to liver cirrhosis remains the most common cause, as in this patient. Duodenal varices resulting from retroperitoneal porto-systemic shunts are caused by increased

Department of
Surgery
Changi General
Hospital
2 Simei Street 3
Singapore 529889

N C Tan, MBBS,
MMed, MRCSE
Registrar

S Ibrahim, MBBS,
FRCS, FAMS
Consultant

K H Tay, FRCSE,
FRCS, FAMS
Senior Consultant
and Chief

Correspondence to:
Dr Tan Ngian Chye
Tel: (65) 6850 3551
Fax: (65) 6260 1709
Email: ngian79@
singnet.com.sg

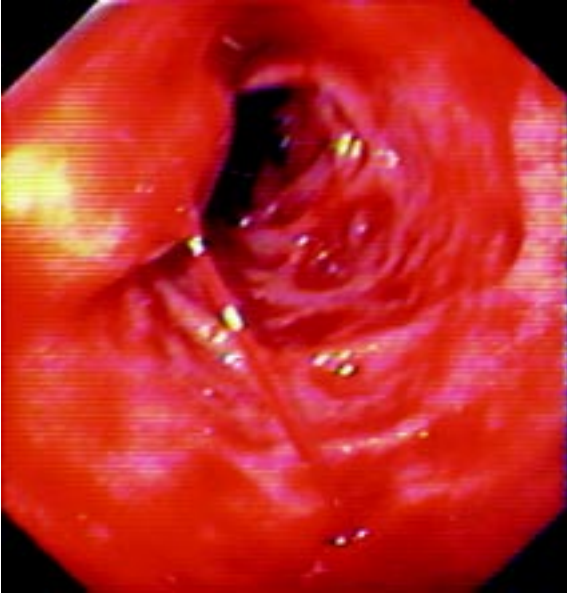


Fig. 1 Endoscopy photograph shows a spurting duodenal varix.

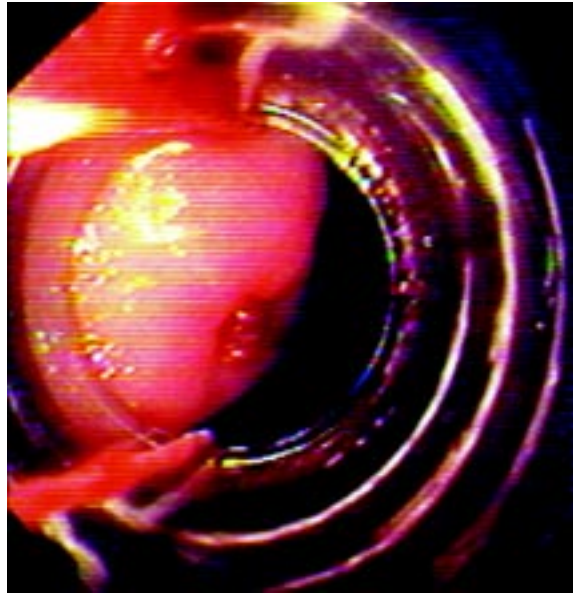


Fig. 2 Endoscopy photograph shows banding of the duodenal varix.

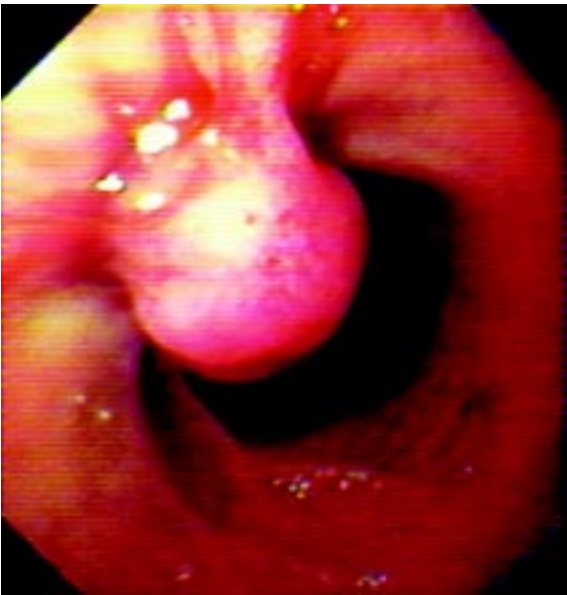

Fig. 3 Endoscopy photograph shows the successfully-banded duodenal varix.

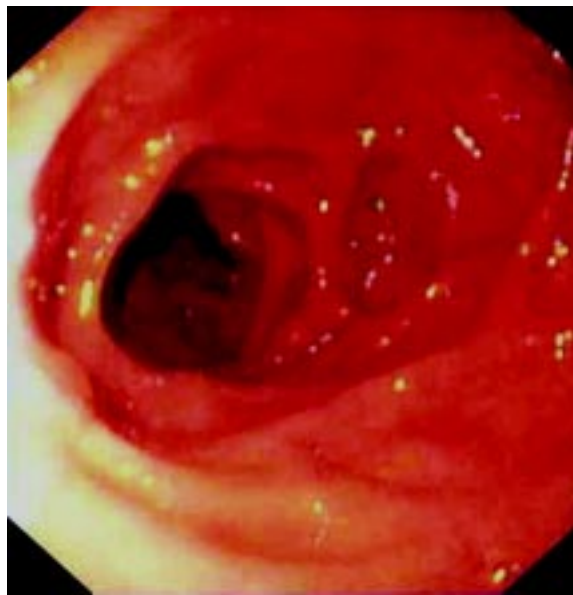

Fig. 2 Follow-up endoscopy done one year post-banding. Photograph shows complete regression of the duodenal varix.

hepatofugal blood flow through the cystic branch of the superior mesenteric vein, superior and inferior pancreaticoduodenal veins, and gastroduodenal and pyloric veins⁽¹⁾. Such varices are less effective in lowering the portal pressure, compared with oesophageal and gastric varices.

Duodenal varices were first recognised radiologically by Alberti in 1931⁽²⁾, while Kunisaki et al⁽³⁾ reported the first case of duodenal varices visualised by endoscopic examination in 1973. Duodenal varices can result in massive upper gastrointestinal bleeding and the treatment is still controversial because experience is limited. So far, bleeding duodenal varices have been mostly treated with

surgical procedures including varices suture ligation, varices resection with or without duodenal resection, porto-systemic shunts, and splenorenal anastomosis.

Interventional radiological treatment methods such as percutaneous transcatheter embolisation and transjugular porto-systemic shunt have also been used to treat duodenal varices⁽⁴⁾. These operations and procedures usually carry high morbidity and mortality⁽⁵⁾. There is no definitive conservative therapy for duodenal varices as yet. However, endoscopic treatment seems more promising for emergency bleeding duodenal varices as it is easier and faster to perform.

Most forms of endoscopic treatment reported have employed injection sclerotherapy as a means to achieve haemostasis for bleeding duodenal varices. However, there has not been consistent successful results with injection sclerotherapy. Sclerosing agents have a damaging effect on the surrounding tissue such that complications such as perforation can occur. In recent years, the tissue adhesive n-butyl-2-cyanoacrylate (Histoacryl) has been successfully used for endoscopical haemostasis of oesophageal and fundal varices. Endoscopic embolisation by Histoacryl has also been tried successfully in securing haemostasis for bleeding duodenal varices^(6,7), but one of them was complicated by right pulmonary artery embolism⁽⁶⁾. The rate of re-bleeding with Histoacryl sclerotherapy is also high⁽⁸⁾.

To date, there has been limited experience with endoscopic banding for bleeding duodenal varices. Tazawa et al reported a case of duodenal variceal bleeding that was successfully controlled with endoscopic ligation, but the patient died of liver failure two days later⁽⁹⁾. In another case, temporary haemostasis was achieved with endoscopic ligation, and this was followed by balloon-occluded retrograde transvenous obliteration a month later⁽¹⁰⁾. Only two cases of bleeding duodenal varices successfully treated with variceal banding alone have been reported^(11,12). In our patient, the relatively small bleeding varix (1.5 cm) was successfully ligated with two bands and the patient recovered uneventfully. The size of a duodenal varix may determine if it is possible to be band ligated endoscopically. However, there is limited experience in determining the maximum size of such a varix that can be treated successfully by endoscopic banding due to its rarity.

He has been followed-up for one year post-ligation and has not suffered any further bleeds.

In conclusion, we reported a case of a patient with a bleeding duodenal varix that was successfully treated with endoscopic variceal banding. This technique may be promising for achieving haemostasis in bleeding duodenal varices, especially in an emergency situation.

REFERENCES

1. Itzchak Y, Glickman MG. Duodenal varices in extrahepatic portal obstruction. *Radiology* 1977; 124:619-24.
2. Alberti W. Über den röntgenologischen nachweise von varizen im bulbus duodeni. *Fortschr Geb Rontgenstr.* 1931; 43:60-5.
3. Kunisaki T, Someya N, Shimokawa Y, et al. Varices in the distal duodenum seen with a fiberduodenoscope. *Endoscopy.* 1973; 5:101-4.
4. Jonnalagadda SS, Quiason S, Smith OJ. Successful therapy of bleeding duodenal varices by TIPS after failure of sclerotherapy. *Am J Gastroenterol.* 1998; 93:272-4.
5. Ponc R, Kowdley KV. Paradoxical cerebral emboli after transjugular intrahepatic portosystemic shunt and coil embolization for treatment of duodenal varices. *Am J Gastroenterol.* 1997; 92:1372-3.
6. Benedetti G, Sablich R, Lacchin T, et al. Endoscopic treatment of bleeding duodenal varices by bucrylate injection. *Endoscopy.* 1993; 25:432-3.
7. Yoshida Y, Imai Y, Nishikawa M, et al. Successful endoscopic injection sclerotherapy with N-butyl-2-cyanoacrylate following the recurrence of bleeding soon after endoscopic ligation for ruptured duodenal varices. *Am J Gastroenterol.* 1997; 92:1227-9.
8. Akahoshi T, Hashizume M, Shimabukuro R, et al. Long-term results of endoscopic Histoacryl injection sclerotherapy for gastric variceal bleeding: a 10-year experience. *Surgery* 2002; 131 (1 suppl):S176-81.
9. Tazawa J, Sakai Y, Koizumi K, et al. Endoscopic ligation for ruptured duodenal varices. *Am J Gastroenterol.* 1995; 90:677-8.
10. Haruta I, Isobe Y, Ueno E, et al. Balloon-occluded retrograde transvenous obliteration (BRTO), a promising nonsurgical therapy for ectopic varices: a case report of successful treatment of duodenal varices by BRTO. *Am J Gastroenterol.* 1996; 91:2594-7.
11. Yeh YY, Hou MC, Lin HC, et al. Case report: successful obliteration of a bleeding duodenal varix using endoscopic ligation. *J Gastroenterol Hepatol.* 1998; 13:591-3.
12. Shiraishi M, Hiroyasu S, Higa T, et al. Successful management of ruptured duodenal varices by means of endoscopic variceal ligation: report of a case. *Gastrointest Endosc.* 1999; 49:255-7.