

Isolated massive thyroid metastasis in lung cancer

Bandyopadhyay S K, Bandyopadhyay R, Dutta A

ABSTRACT

Metastasis to the thyroid gland is rare despite its rich vascular supply. Among the pulmonary malignancies metastasising to the thyroid, adenocarcinomas are the commonest. The appearance of metastatic disease in lung carcinoma indicates a poor prognosis and the average survival is two months. We report a 62-year-old woman with squamous cell carcinoma of lung metastatic to the thyroid that produced massive enlargement of the gland. The appearance of the secondary preceded the diagnosis of the primary malignancy by a few months. Ultimately, the patient succumbed to her disease.

Keywords: lung cancer, metastasis, thyroid metastasis, thyroid tumour

Singapore Med J 2006; 47(4):324-326

INTRODUCTION

A case of metastatic lung cancer producing massive replacement of thyroid is reported where the appearance of metastasis preceded the symptomatic manifestation of primary pathology.

CASE REPORT

A 62-year-old woman was diagnosed to have simple colloid goitre some ten years ago, based on the presence of grade two goitre, normal thyroid function tests, and normal anti-thyroperoxidase antibody level. The diagnosis was confirmed by fine needle aspiration cytology (FNAC). There was no other past, personal or family history of significance.

Six months ago, the patient first noticed progressive increase in the size of the thyroid gland along with dull ache. Thyroid function tests showed a thyroid stimulating hormone (TSH) value of 12 mU/L (normal range, 0.5-4.7 mU/L). The patient was given oral levothyroxin – initially 50 microgram (μg) – subsequently increased to

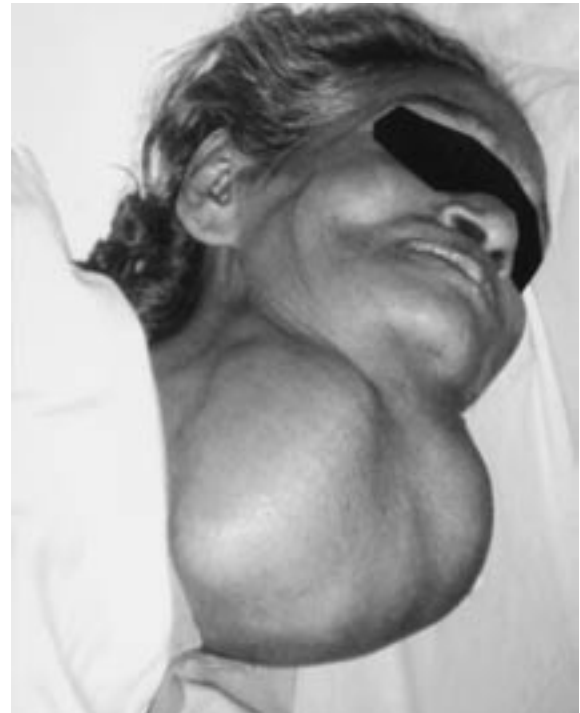

Fig. 1 Clinical photograph shows massive thyroid enlargement.

100 μg and then to 150 μg because of the persistently rising TSH and rapidly increasing size of gland. ^{131}I thyroid scintigraphy showed multifocal areas of decreased uptake.

Gradually she developed hoarseness of voice, puffiness of face and dysphagia mostly to solid foods over the past one month. She also had two episodes of streaks of haemoptysis during the same period.

On physical examination, the thyroid was hugely enlarged asymmetrically (left lobe more enlarged than right lobe). It had a firm irregular surface, with fixation to the skin, but without any rise in local temperature, tenderness, or bruit (Fig. 1). Retrosternal extension was detected on clinical examination. Mild pallor was present without any lymphadenopathy, oedema, or icterus. A few prominent veins were noted on her temple, and neck veins were engorged but non-pulsatile.

Department
of Medicine
Nil Ratan Sircar
Medical College
and Hospital
138, A J C Bose Road
Calcutta 14
India

Bandyopadhyay S K,
MD, DNB
Assistant Professor

Dutta A, MD
Professor

Division of Pathology
Chittaranjan National
Cancer Institute
37, S P Mukherjee
Road
Calcutta 26
India

Bandyopadhyay R, MD
Registrar

Correspondence to:
Dr S K Bandyopadhyay,
Tel: (91) 033 2664 0883
Fax: (91) 033 2321 6940
Email: drsanjay_b@
rediffmail.com

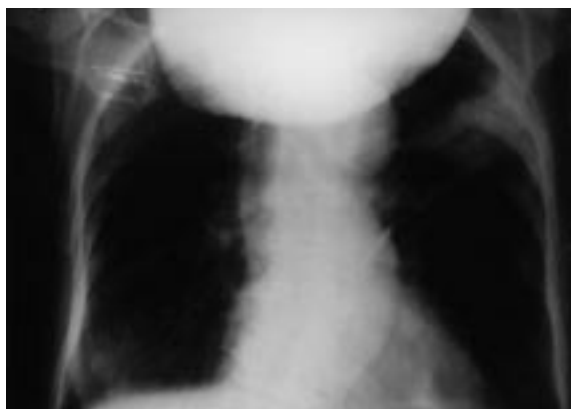


Fig. 2 Chest radiograph (PA view) shows a large inhomogeneous opacity with irregular margin in left upper zone with mediastinal widening.

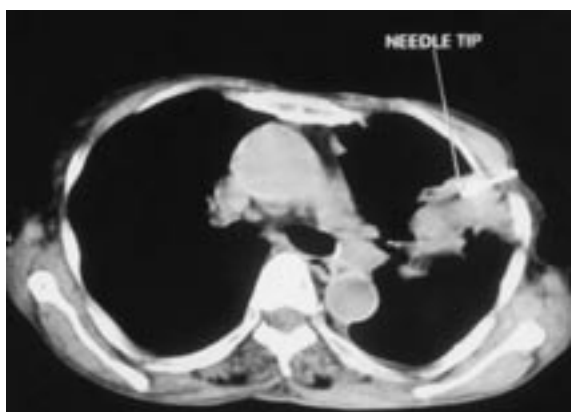


Fig. 3 Axial CT image of the thorax shows a soft tissue density lesion in the upper lobe of the left lung with a solitary lymph node in aorto-pulmonary window.

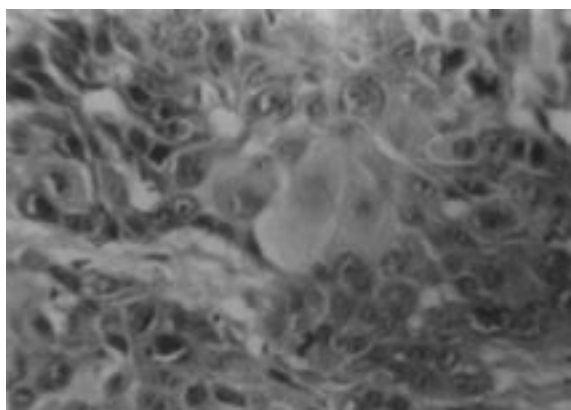


Fig. 4 Photomicrograph of the excision biopsy specimen from the thyroid shows moderately-differentiated squamous cell carcinoma (Haematoxylin & eosin, x275).

Examination of all other systems did not reveal any other abnormality.

Routine blood tests showed a haemoglobin level of 8.3 gm/dL (normal range, 12.0-15.5 gm/dL), with a sedimentation rate of 60 mm at first hour (normal range, 1-25 mm/hour). Renal and hepatic

biochemical profile was normal. Thyroid function tests showed elevated TSH (21 mU/L) along with low free T₄ (0.16 ng/dL) and free T₃ (1.2 pg/mL) [normal ranges, TSH 0.5-4.7 mU/L, free T₄ 0.8-2.7 ng/dL, free T₃ 1.4-4.4 pg/mL]. Chest radiograph showed an ill-defined inhomogeneous opacity in the left lung upper zone with widening of the superior mediastinum (Fig. 2).

Computed tomography (CT) of the thorax showed a soft tissue density lesion in the left upper lobe that abutted the pleural surface and extended from the left hilum to the ipsilateral pleura. No calcification, cavitation, or air bronchogram was seen in this lesion. An enlarged solitary lymph node was noted in aorto-pulmonary window (Fig. 3). CT-guided FNAC from the lung mass showed scattered foci of moderately-differentiated squamous cell carcinoma. Ultrasonography-guided FNAC from the thyroid gland also showed the same pathology.

Limited excision biopsy of the thyroid gland was performed and a diagnosis of metastatic squamous cell carcinoma was established (Fig. 4). A primary tumour in the oesophagus was ruled out by oesophagoscopy and barium swallow study-both of which revealed extrinsic compression in the cervical part of oesophagus. There was no mucosal irregularity, nodule, thickening or intramural/intraluminal growth on barium study. CT of brain and abdomen and bone marrow aspiration study could not detect any metastatic deposit. Patient refused any further therapy and died three weeks after the diagnosis was established.

DISCUSSION

The incidence of metastasis to the thyroid gland in autopsy series varies from 1.3% to 24%, depending on whether the cases are unselected or from patients with widespread malignant neoplasms⁽¹⁾. The kidney is the most common primary tumour site (33%), followed by the lung (16%), breast (16%), oesophagus (9%), and uterus (7%)⁽²⁾. Others have found the breast (22.7%) and lungs (13.6%) to be the most common primary sites⁽³⁾. Some of these metastases are found in pre-existing thyroid lesions, such as follicular adenoma or papillary carcinoma^(1,2).

Dysphagia is an ominous feature, while thyroid function is normal in majority of cases⁽⁴⁾. Hypothyroidism secondary to metastatic infiltration and replacement of the thyroid by cancer is extremely rare. Thyrotoxicosis has also been reported in patients with thyroid metastasis, possibly due to follicular destruction resulting in

unregulated release of thyroid hormones⁽⁵⁾. The thyroid lesion is unifocal in the majority of cases, although multifocal or diffuse involvement is also seen. Ultrasonography usually shows focal or diffusely-infiltrating hypoechoic lesions; likewise inhomogeneously hypodense areas with mild contrast enhancement are observed on CT⁽⁴⁾.

FNAC performed under ultrasonographic guidance is a useful tool, having a sensitivity of 96.6%, and should be carried out for diagnosis, staging and follow-up⁽²⁾. Excision biopsy and histopathology is required for the final diagnosis⁽¹⁾. Survival rate is 2-60 months (mean 19 months)⁽⁴⁾. Where indicated, palliative thyroidectomy can be effective. Metastasis to the thyroid gland is usually considered a terminal event, and the effectiveness of the conventional treatment has been questioned⁽²⁾.

Among the types of lung cancer metastasising to the thyroid, adenocarcinomas are the commonest, followed by squamous cell, small cell, large cell and bronchoalveolar carcinoma^(6,7). The appearance of metastatic disease in the thyroid indicates a poor prognosis in lung carcinoma, where it represents a pre-terminal event and the average survival from diagnosis to death is two months⁽⁶⁾. Occasionally, thyroid secondaries have been reported to precede the diagnosis of primary pulmonary malignancy^(6,7).

This case report highlights a very rare occurrence of metastatic squamous cell lung carcinoma to the thyroid with already existing simple colloid goitre. The metastatic involvement of the gland resulted in its progressive enlargement, with development of biochemical hypothyroidism which was refractory to replacement therapy. Interestingly, no metastatic involvement was found in any other organ. Barring two episodes of haemoptysis, there was no other symptom of primary disease. Instead, symptomatic manifestation of metastatic thyroid disease appeared a few months prior to that of primary lung neoplasm.

REFERENCES

1. Lin JD, Weng HF, Ho YS. Clinical and pathological characteristics of secondary thyroid cancer. *Thyroid* 1998; 8:149-53.
2. Nakhjavani MK, Gharib H, Goellner JR, et al. Metastasis to the thyroid gland. A report of 43 cases. *Cancer* 1997; 79:574-8.
3. Kim TY, Kim WB, Gong G, et al. Metastasis to the thyroid diagnosed by fine-needle aspiration biopsy. *Clin Endocrinol (Oxf)* 2005; 62:236-41.
4. Ferrozzi F, Campodonico F, De Chiara F, et al. Thyroid metastases: the echographic and computed tomographic aspects. *Radiol Med* 1997; 94:214-9.
5. Berdjis N, Baldauf A, Kittner T, et al. Paraneoplastic hyperthyroidism in a patient with metastasizing teratocarcinoma and excessively high HCG. *Aktuelle Urol* 2003; 34:407-9.
6. Singh R, Lehl SS, Sachdev A, et al. Metastasis to the thyroid from lung carcinoma. *Indian J Chest Dis Allied Sci* 2003; 45:203-4.
7. Haraguchi S, Hioki M, Yamashita K, et al. Metastasis to the thyroid from lung adenocarcinoma mimicking thyroid carcinoma. *Jpn J Cardiovasc Surg* 2004; 52:353-6.