

Intrapartum maternal sinus bradycardia with spontaneous resolution following delivery

Devendra K, Ching C K, Tan L K, Tan H K, Yu S L

ABSTRACT

Pregnancy is a normal physiological state that is characterised by significant adaptive changes, many of which take place in the cardiovascular system. These adaptations are believed to be the cause for the increased incidence in cardiac arrhythmias in pregnancy and particularly, in labour. We report an unusual case of a healthy 32-year-old primigravida who developed profound intrapartum bradycardia which persisted throughout labour. Spontaneous recovery to pre-labour baseline heart rate occurred following spontaneous vaginal delivery. Maternal and foetal statuses remained satisfactory during labour. This case report underscores the importance of recognising that arrhythmias in various forms are common in labour. In the absence of detectable underlying cardiac disease or maternal and foetal compromise, continuation of the labour with a view to vaginal delivery should be the goal.

Keywords: arrhythmia, bradycardia, intrapartum maternal sinus bradycardia, pregnancy complications

Singapore Med J 2006; 47(11):971-974

INTRODUCTION

Cardiac arrhythmias are known to be more common during pregnancy and labour. Management of these women is clinically challenging. Apart from concerns about foetal and maternal well-being as a result of these arrhythmias, there is the need to exclude underlying cardiac disease and to make decisions with regard to timing and mode of delivery. We report an unusual case which clearly illustrates these complexities.

CASE REPORT

A 32-year-old primigravida who had experienced an uneventful pregnancy presented to the delivery

suite of her hospital in spontaneous labour. Antenatal records confirmed that she was normotensive antenatally, with a baseline heart rate of 90-100 beats. When assessed in labour, she was noted to have a bradycardia of approximately 40 beats per minute. An electrocardiogram (ECG) confirmed that this was a sinus bradycardia (Fig.1). There was no evidence of hyperacute changes suggestive of myocardial ischaemia or of an atrio-ventricular conduction defect such as a heart block. A cardiologist who was consulted noted that, apart from a sensation of dizziness, the woman remained haemodynamically stable with blood pressure recordings in the normal range for pregnancy. There was an absence of the expected physiological cyclical acceleration of the maternal heart rate despite the presence of regular, painful uterine contractions. She was transferred to our hospital for further management in recognition of the possible need for a cardiac pacemaker.

Ongoing assessment showed that her bradycardia persisted. However, foetal assessment by cardiotocogram (CTG) confirmed that the foetal condition was satisfactory. Serial 12-lead ECG remained otherwise normal and cardiac enzymes as well as troponin T levels were not elevated. Her labour pains intensified and analgesia was required. There was a reluctance to use an epidural anaesthetic as it was felt that the risk of hypotension in the presence of her refractory bradycardia may be detrimental to mother and foetus. Transcutaneous electric nerve stimulation and opioid analgesics in the form of intramuscular pethidine were used without success. Her labour pains remained intractable. A consensus was reached between the obstetricians, anaesthetists and cardiologist to use an epidural anaesthetic as she remained haemodynamically stable. It was felt that allowing an epidural anaesthetic with a view to vaginal delivery was safer than resorting to caesarean section with the attendant risks associated with major surgery, such as haemorrhage.

An epidural catheter was inserted without complications and an anaesthetic was administered

High Risk Pregnancy
Clinic
Obstetrics and
Gynaecology Centre
Singapore General
Hospital
Outram Road
Singapore 169608

Devendra K, MBBS,
MRCOG
Consultant

Tan L K, MBBS,
MMed, MRCOG
Consultant

Tan H K, MBBS,
MMed, MRCOG
Senior Consultant

Yu S L, MBBS, MMed,
FRCOG
Senior Consultant

Dept of Cardiology
National Heart Centre
Mistri Wing
17 Third Hospital
Avenue
Singapore 168752

Ching C K, MBBS,
MRCP
Associate Consultant

Correspondence to:
Dr Devendra
Kanagalingam
Tel: (65) 9009 0359
Fax: (65) 6225 3464
Email: devendra.
kanagalingam@
sgh.com.sg

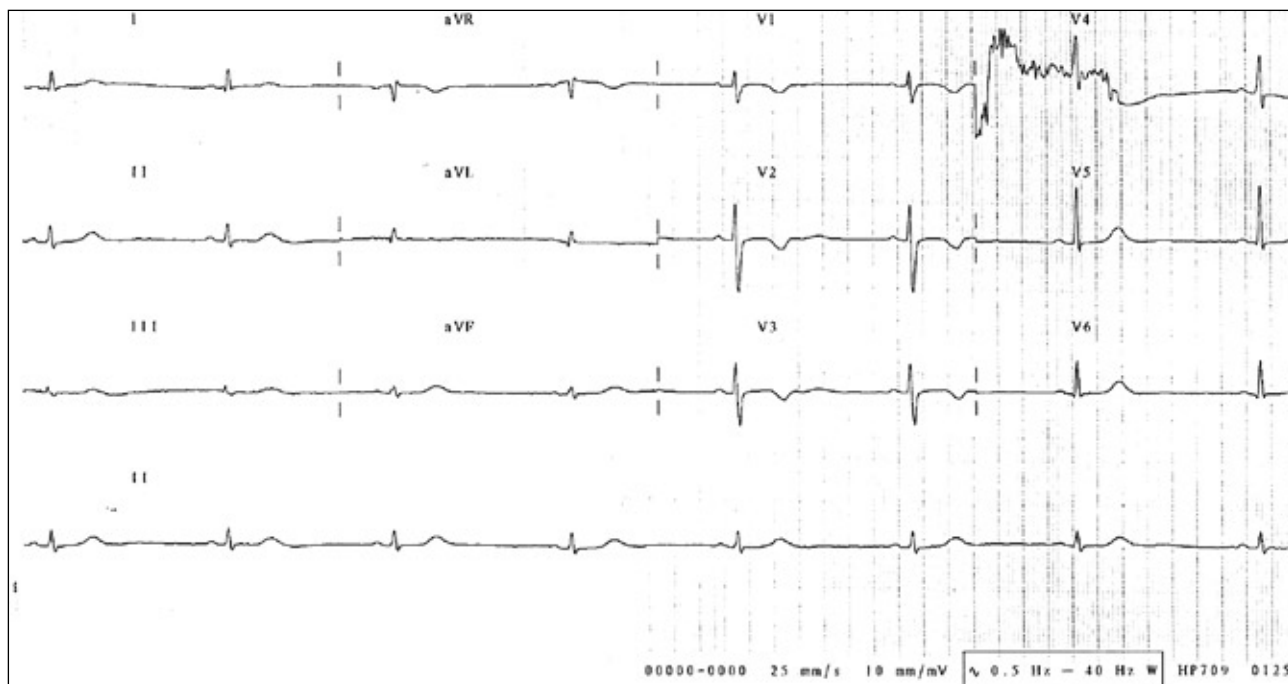


Fig. 1 ECG performed in early labour shows profound maternal bradycardia and the absence of acute changes suggestive of myocardial ischaemia.

by continuous infusion. Her labour progressed uneventfully and resulted in the live birth of a male baby by spontaneous vaginal delivery. The neonate's condition at birth was good. Three hours after delivery, a spontaneous recovery of the maternal heart rate, initially to 60 beats per minute and subsequently, to the pre-labour baseline of 90-100 beats was observed. This recovery was abrupt rather than gradual (Fig. 2). Subsequent investigations, including echocardiography, did not reveal any cardiac abnormality and no recurrence of her bradycardia was recorded during her hospital stay. This was further confirmed on outpatient ambulatory heart rate monitoring (Holter monitoring) and at subsequent outpatient follow-up.

DISCUSSION

Clinical experience and the published literature support the belief that pregnancy and labour are associated with a higher incidence of maternal cardiac arrhythmias⁽¹⁻³⁾. In pregnancy, physiological changes to the cardiovascular system cause an increase in total blood volume, heart rate and cardiac output. Peripheral vascular resistance is lowered and regional blood flow is altered⁽²⁾. There is evidence of an increase in the left ventricular diameter and myocardial hypertrophy⁽⁴⁾. These profound anatomical and functional changes are believed to be the cause for a higher incidence of maternal cardiac arrhythmias.

This case remains unusual for two reasons. Firstly, the woman presented with a bradycardia. Other case series have established that arrhythmias most commonly seen in labour are atrial premature beats, ventricular premature beats, sinus and supraventricular tachycardias⁽⁵⁻⁷⁾. Labour is a period of considerable physical and emotional strain, and the predominance of tachycardia-related arrhythmias as a consequence of endogenous catecholamine release is understandable. Although bradycardias have been reported in the peripartum period, previous studies^(8,9) suggest that these tend to occur following delivery rather than during labour, as in this case. Secondly, this presentation was unique in that the bradycardia persisted throughout the entire labour. Other authors report that a more common pattern is transient arrhythmias which occur intermittently during labour⁽¹⁰⁾. The correlation between arrhythmias and symptoms in pregnant women is poor. This woman complained of dizziness but this symptom, as well as presyncope and even syncope, are not uncommon during pregnancy⁽⁸⁾. These may be attributed to the physiological changes that are present in pregnant women.

Intrapartum analgesia proved to be a clinical dilemma. We were concerned that a regional anaesthetic which frequently induces maternal hypotension could precipitate cardiac failure in a woman who was not able to mount a physiological response in the form of tachycardia. Nevertheless,

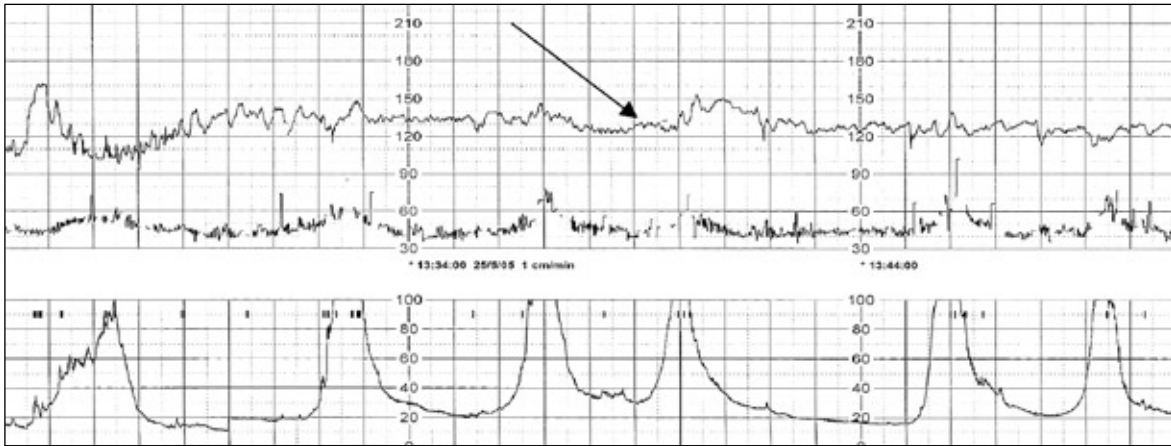


Fig. 2 ECG of simultaneous foetal CTG and maternal heart rate monitoring shows a satisfactory foetal heart rate pattern (arrow) despite the maternal bradycardia. Note the presence of regular uterine contractions.

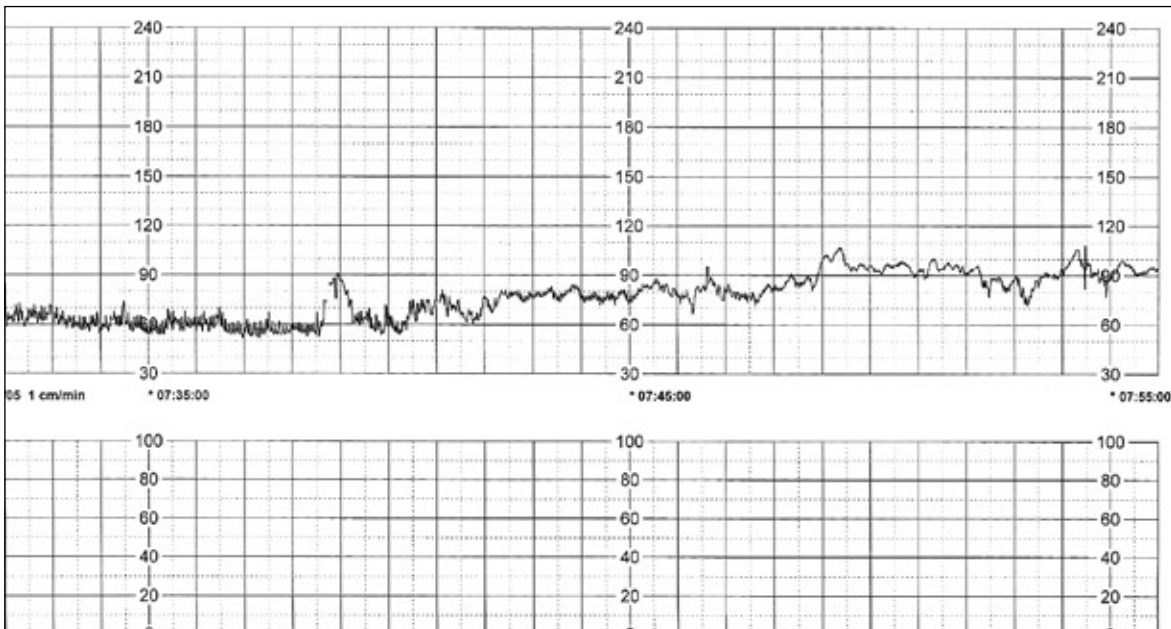


Fig. 3 ECG of postpartum maternal heart rate monitoring shows the rapid return of the maternal heart rate to its pre-labour baseline.

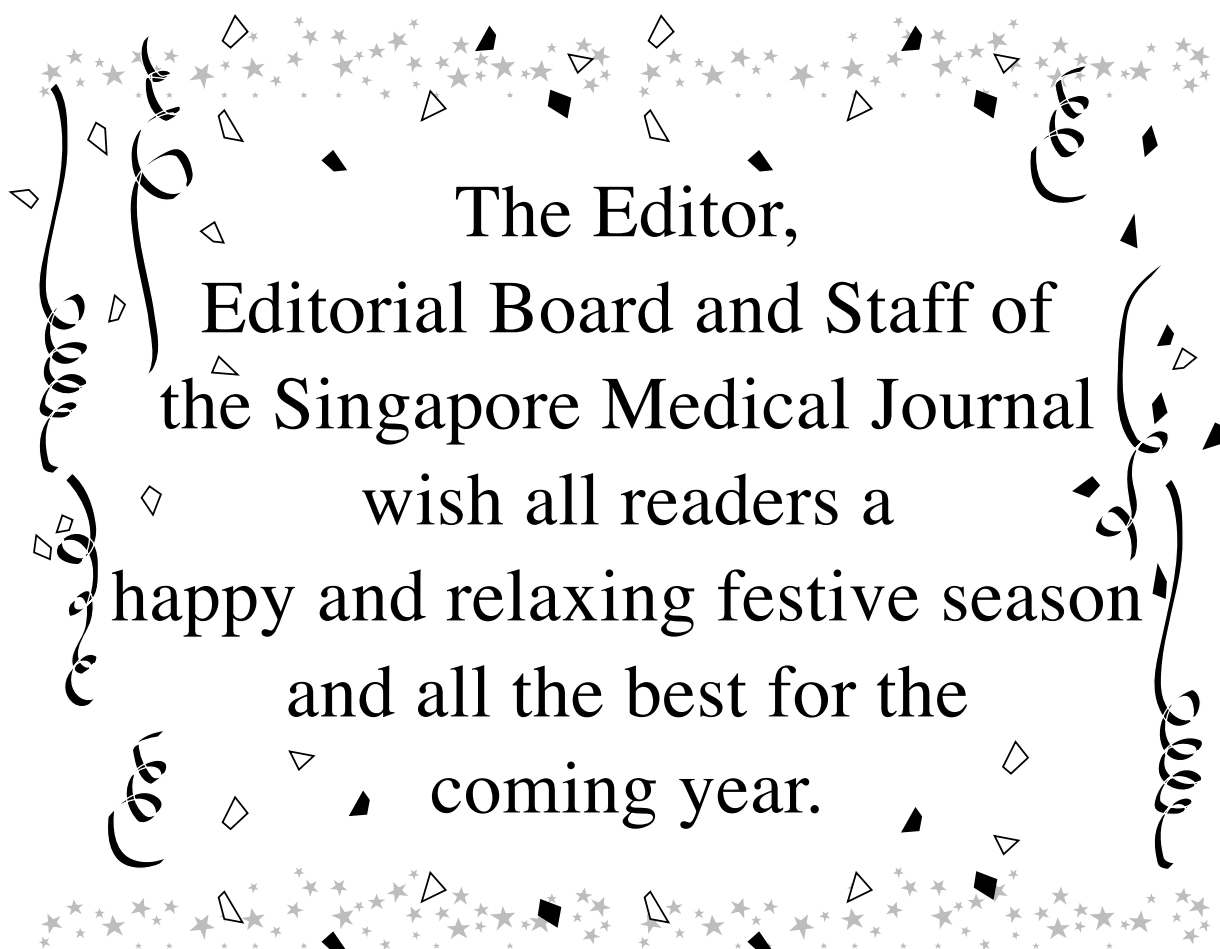the absence of detectable cardiac disease and the fact that she remained haemodynamically stable supported the eventual decision to proceed with the anaesthetic. The pains of labour are frequently severe and in this case, adequate pain relief was a prerequisite to continuation of the labour and subsequent vaginal delivery. The decision to proceed with an epidural anaesthetic was taken on risk-benefit considerations. The only alternative to vaginal delivery is a caesarean section. This major operation is known to carry a higher risk of postpartum haemorrhage and maternal mortality⁽¹¹⁾ than vaginal delivery. These risks could

be further compounded in the presence of a cardiac arrhythmia.

We highlight this case to emphasise the fact that while cardiac arrhythmias are common in labour, their nature and presentation can be quite varied. When faced with such a clinical situation, a rigorous search for underlying cardiovascular disease is mandatory. In the absence of this and haemodynamic compromise, we propose that watchful waiting should be the rule and vaginal delivery the goal. As this case illustrates, regional analgesia is not necessarily contraindicated in these women.

REFERENCES

1. Brown CE, Wendel GD. Cardiac arrhythmias during pregnancy. *Clin Obstet Gynecol* 1989; 32:89-102.
2. Blackburn TS, Lee LD. Cardiovascular system. In: Eoyang T, ed. *Maternal, Fetal and Neonatal Physiology: a Clinical Perspective*. Philadelphia: WB Saunders, 1992:201-12.
3. Leung CY, Brodsky MA. Cardiac arrhythmias and pregnancy: diagnosis and management of maternal and fetal disease. In: Elkayam U, Gleicher N, eds. *Cardiac Problems in Pregnancy*. 3rd ed. New York: Wiley-Liss, 1998:155-75.
4. Robson SC, Hunter S, Boys RJ, Dunlop W. Serial study of factors influencing changes in cardiac output during human pregnancy. *Am J Physiol* 1989; 256:H1060-5.
5. Hair TE Jr, Eagan JT, Orgain ES. Paroxysmal ventricular tachycardia in the absence of demonstrable heart disease. *Am J Cardiol* 1962; 9:209-14.
6. Hubbard WN, Jenkins BA, Ward DE. Persistent atrial tachycardia in pregnancy. *Br Med J (Clin Res Ed)* 1983; 287:327.
7. Brodsky M, Doria R, Allen B, et al. New-onset ventricular tachycardia during pregnancy. *Am Heart J* 1992; 123:933-41.
8. Shotan A, Ostrzega E, Mehra A, Johnson JV, Elkayam U. Incidence of arrhythmias in normal pregnancy and relation to palpitations, dizziness, and syncope. *Am J Cardiol* 1997; 79:1061-4.
9. Romem A, Romem Y, Katz M, Battler A. Incidence and characteristics of maternal cardiac arrhythmias during labor. *Am J Cardiol* 2004; 93:931-3. Comment in: *Am J Cardiol* 2005; 95:435.
10. Upshaw CB Jr. A study of maternal electrocardiograms recorded during labor and delivery. *Am J Obstet Gynecol* 1970; 107: 17-27.
11. Hall MH. Mortality associated with elective caesarean section. *BMJ* 1994; 308:1572.



The Editor,
Editorial Board and Staff of
the Singapore Medical Journal
wish all readers a
happy and relaxing festive season
and all the best for the
coming year.