

Mucormycosis in patients with complicated cirrhosis

Abbas Z, Jafri W, Rasool S, Abid S, Hameed I

ABSTRACT

Introduction: Rhino-orbito-cerebral mucormycosis is a rapidly progressive and fatal disease that mostly occurs in patients with diabetes mellitus and immunocompromised status. Antifungal therapy with surgical debridement is the standard of care. Patients with cirrhosis of liver are more prone to develop different infections. Many of these also show glucose intolerance or frank diabetes mellitus. Little is known about the clinical presentation and outcome of mucormycosis in patients with cirrhosis. Treatment is difficult due to underlying coagulopathy and hepatic dysfunction.

Methods: Medical records of the past five years were searched for the cirrhotic patients admitted with associated diagnosis of mucormycosis or fungal infection. Six patients with mucormycosis were identified.

Results: Out of six patients, five were male. Age range was 15–57 years. Cause of cirrhosis was hepatitis C in four patients, hepatitis B in one patient and autoimmune hepatitis in one patient. Two patients had hepatocellular carcinoma. Four patients had diabetes mellitus, of which one patient was also on steroids for the autoimmune liver disease. Four patients had spontaneous bacterial peritonitis at the time of admission. All six patients presented with rhino-orbito-cerebral mucormycosis with nasal discharge and upper motor neuron signs. Diagnosis of mucormycosis was made by culture of biopsy and scrapings taken from the palate and nasal sinuses. These patients received amphotericin B. Four patients died while in the hospital, while two patients died within next few days after discharge.

Conclusion: Mucormycosis in cirrhosis is not very common and has a poor prognosis. Patients with advanced cirrhosis and diabetes mellitus are at risk of developing infection.

Keywords: cirrhosis, diabetes mellitus, hepatocellular carcinoma, mucormycosis, oculo-rhino-cerebral mucormycosis

Singapore Med J 2007; 48(1):69–73

INTRODUCTION

Mucormycosis is a rare disease and usually occurs in patients with pre-existing debilitating disease or are receiving immunosuppressive therapy. With the increasing number of patients undergoing immunosuppressive therapy and lengthening of the life span due to improving medical care, the incidence of opportunistic mycotic infections like mucormycosis is increasing⁽¹⁾. Mucormycosis is a term used to refer to any fungal infections of the order Mucorales, which belongs to class Zygomycetes. Infection can involve lungs, central nervous system, skin (usually in burn patients) and gastrointestinal tract, but is best known for its rhinocerebral presentation, which is usually initiated with sino-nasal involvement and may progress to the orbit and brain⁽²⁾.

Rhinocerebral mucormycosis is not common and if unrecognised or inadequately treated, is certainly the most acutely fatal fungal infection known to man⁽³⁾. The clinical presentation and prognosis of oculo-rhino-cerebral mucormycosis in patients with cirrhosis is not well known. The available literature is confined to a few case reports or case series only. The aim of the present study is to determine the clinical presentation and outcome of rhinocerebral mucormycosis in patients with cirrhosis.

METHODS

The medical records of the past five years were searched for cirrhotic patients admitted with associated diagnosis of mucormycosis or fungal infection. Six patients with mucormycosis infection proven by histology or culture and managed at the Aga Khan University Hospital were

Department of
Medicine,
The Aga Khan
University Hospital,
Stadium Road,
Karachi 74800,
Pakistan

Abbas Z, FCPS,
FRCP, FACP
Consultant
Gastroenterologist

Jafri W, FRCP,
FACP, FACP
Professor and Chair

Rasool S, MBBS,
FCPS
Fellow in
Gastroenterology

Abid S, MBBS,
FCPS, FRCP
Associate Professor

Hameed I, MD
Research Officer

Correspondence to:
Dr Zaigham Abbas
Tel: (92) 21 493 0051
Fax: (92) 21 493 4294
Email:
zaigham@akunet.org

identified. Apart from detailed clinical evaluation, baseline parameters such as full blood count, liver and renal function test, diagnostic ascitic paracentesis and abdominal ultrasound were done to evaluate hepatic function and for Child-Pugh scoring. Computed tomography (CT) of the head was done, and tissue diagnosis was sought by biopsy obtained either endoscopically under local anaesthesia or by surgical debridement. Material was also sent for culture. Amphotericin B was initiated once the clinical diagnosis was suspected or after radiological and histopathological diagnoses. These patients were managed by gastroenterologists in consultation with specialists in infectious diseases, ophthalmology, and ear, nose and throat (ENT).

RESULTS

A brief summary of these patients is given below. Clinical and radiological features have been summarised in Table I.

Case 1. A 39-year-old man, known to have diabetes mellitus and hypertension, was on interferon alpha-2a and ribavirin therapy for chronic hepatitis C for three months. He was admitted with presenting complaints of headache, fever, slurred speech, gait disturbance and swelling of right eye with dropping of eyelid. Clinically, he had upper motor neuron lesion signs in the limbs, swelling of right eye and numbness on right side of face and multiple cranial nerve palsies. A provisional diagnosis of rhinocerebral mucormycosis was made and he was started on amphotericin B. Magnetic resonance (MR) imaging showed right sinusitis, right orbital cellulitis and infarct in the right brain stem. CT of the paranasal sinuses revealed pan-sinusitis on right side without any gross bony involvement. Surgical debridement and enucleation of right eye was done along with pharmacological

therapy. There was rapid neurological deterioration and he was intubated. Culture from scrapings was positive for mucormycosis. Patient died in spite of standard therapy and a compensated liver disease.

Case 2. A 57-year-old man with hepatitis C virus (HCV) cirrhosis and hepatocellular carcinoma (HCC) presented with shortness of breath, pedal oedema, decreased urine output, bilateral ear infection and parotid swelling for five days. He had a history of oesophageal variceal bleeding with recent band ligation. Clinically, he had jaundice, high-grade fever, moderate to severe ascites, and swelling on the right side of face below the ear. On the basis of clinical and laboratory data, a diagnosis of spontaneous bacterial peritonitis (SBP), hepatic encephalopathy and mucormycosis was made, which was confirmed by the culture of septate hyphae from ear scrapings. He had Child's C liver disease with renal insufficiency. He was started on amphotericin B but surgical intervention was not possible due to the poor clinical situation. He died after a couple of days.

Case 3. A 55-year-old man suffering from hepatitis B virus (HBV) cirrhosis and HCC was admitted with decreasing urine output and hepatic encephalopathy. He had a history of resection of HCC and chemotherapy two years ago. Diagnosis of hepatic encephalopathy secondary to SBP and hepatorenal syndrome was made. During his stay in the hospital, he developed ptosis and ophthalmoplegia of his right eye. Suspecting mucormycosis, amphotericin was started. The next day, he developed multiple cranial nerve palsies. CT of the paranasal sinuses revealed soft tissue thickening in the left maxillary and ethmoidal sinuses. Histopathology from an ulcer on the palate was consistent with mucormycosis. Due to rapid deterioration and poor medical prognosis,

Table I. Clinical and radiological features

Patient no.	Age/gender	Cause of CLD	Child-Pugh class	Complications of cirrhosis	Comorbid conditions	Extent of spread on CT
1	39/M	HCV	B		DM, HTN	Maxillary, ethmoid and sphenoid sinus. MCF
2	57/M	HCV	C	PSE, SBP, HCC	None	Not done
3	55/M	HBV	C	PSE, SBP, HRS, HCC	None	Maxillary and ethmoid sinus
4	15/F	Autoimmune hepatitis	C	PSE, SBP	DM, steroid therapy	Maxillary sinus
5	53/M	HCV	C		DM, HTN	Maxillary, ethmoid and sphenoid sinuses, orbit, MCF
6	35/M	HCV	C	SBP, HRS	DM	Maxillary, ethmoid and sphenoid sinus, orbit.

CLD: Chronic liver disease; HCV: Hepatic C virus; HBV: Hepatitis B virus; DM: Diabetes mellitus; HTN: Hypertension; HCC: Hepatocellular carcinoma; SBP: Spontaneous bacterial peritonitis; PSE: Portosystemic encephalopathy; HRS: Hepatorenal syndrome; MCF: Middle cranial fossa

aggressive treatment (surgery) was avoided and the patient died.

Case 4. A 15-year-old girl, suffering from autoimmune hepatitis and decompensated cirrhosis, was admitted with history of malaena. She was in hepatic encephalopathy on admission. She also had secondary diabetes mellitus, as she had been on steroids for a long time. She developed SBP during her hospital stay. Later, she developed ocular pain, toothache, photophobia, and numbness of the face. Biopsy from black eschar on the palate and nose was positive for mucormycosis. CT of the paranasal sinuses showed mucosal thickening of the right maxillary sinus without any bony extension. Her condition deteriorated and the prognosis was explained to the family who decided that the patient should leave the hospital against medical advice. Patient died three days after discharge.

Case 5. A 53-year-old man, a known case of diabetes mellitus, hypertension and HCV cirrhosis, was admitted with the complaints of fever associated with right eye swelling and pain for four weeks. He also complained of loss of vision in the right eye and deviation of mouth with dribbling of saliva for one week. On examination, he had multiple cranial nerve palsies and an ulcerated lesion on the right side of his palate. His investigations showed uncontrolled diabetes mellitus, with a random blood sugar of 374 mg/dL and HbA1C of 9.7%. He had Child's C liver cirrhosis but no SBP. CT of paranasal sinuses showed sinusitis involving the right sinuses and inflammatory changes in the right orbit. MR imaging of the brain showed minimal abnormal signal intensities in the right temporal lobe with sinusitis and a small area of altered signal intensity along the right optic nerve. Endoscopic debridement of the right sinuses, nasal cavity and ear was done, followed by enucleation of the right eye. Biopsy of palate scraping was positive for mucormycosis, and right eyeball and orbital contents also grew non-septate hyphae of mucormycosis. He received a total dose of 2,000 mg amphotericin B and was discharged from hospital. He died at home, ten days after discharge.

Case 6. A 35-year-old man with Child's C HCV cirrhosis and diabetes mellitus was discharged from the ward with the diagnosis of SBP and hepatorenal syndrome type II. Two weeks later, he was re-admitted with fever, headache, dysphagia and ptosis with loss of vision in his right eye. He had a black ulcer on the hard palate with ophthalmoplegia and multiple cranial nerve palsies. CT of the paranasal sinuses showed involvement of all the sinuses on the right side and orbital cellulitis. Tissue from the nasal cavity and scraping from the ulcer showed moderate broad coenocytic hyphae on fungal smear and later grew mucormycosis. He was started on amphotericin

but refused any surgical debridement. He died within 48 hours of his admission.

DISCUSSION

Known risk factors for rhinocerebral mucormycosis are diabetes mellitus, systemic steroids, neutropenia, malnutrition, immunodeficiency, leukaemia, solid organ and bone marrow transplantation^(4,5). Cirrhosis of liver is an acquired immune deficiency state and patients with chronic liver disease (CLD) are more prone to develop different infections^(6,7). All host defense systems are compromised, e.g. the acute phase response, and macrophage, neutrocyte, and lymphocyte functions. Many of them also show impaired glucose tolerance or diabetes mellitus, while some patients are also taking steroids for autoimmune hepatitis. Dyshomeostasis and malnutrition are also contributing factors. In decompensated CLD, SBP is the most frequent infection. Patients taking prophylactic antibiotics for SBP are prone to develop other atypical infections. There are only few case reports of rhinocerebral mucormycosis in cirrhotic patients with or without liver transplantation^(8,9).

Diabetes mellitus, especially with associated ketoacidosis, is the most important predisposing condition for mucormycosis, though exact cause of this is not known. Ruinous organisms have an active ketone reductase system and thrive in hyperglycaemic, acidotic conditions⁽⁴⁾. In one of the largest single series of 126 patients with rhinocerebral mucormycosis, 70% of patients were diabetic⁽⁴⁾. In our series of cirrhotic patients, four out of six were diabetic. There is a known association of diabetes mellitus with hepatitis C especially for genotypes 2 and 3^(10,11). In our patients, genotyping was not done because we were not contemplating interferon therapy. However diabetes mellitus here seems to be related to hepatitis C cirrhosis, or steroid treatment in a cirrhotic patient. In cases 2 and 3, no other known risk factor existed except these patients had HCC. So we presume that complicated cirrhosis or associated HCC were the possible risk factors. Development of mucormycosis in our patients may reflect compromised immunity of the patient from diabetes mellitus, cancer and advanced cirrhosis.

Rhino-orbito-cerebral mucormycosis may have seasonal incidence, peaking in the fall and early winter⁽¹²⁾. Spores of mucormycosis are transmitted through inhalation. The nasal ciliary clearance system transports these spores out of the nasal cavity, down to the pharynx, to be cleared out by the gastrointestinal tract. Spores inhaled into the lungs are cleared by phagocytes. Fever, nasal ulceration and necrosis, periorbital or facial swelling, ptosis, decreased vision, ophthalmoplegia, headache and decrease in mental status are the main presenting clinical

features in the first 72 hours⁽¹³⁾. Some of these features are masked in patients with cirrhosis due to underlying hepatic dysfunction and hepatic encephalopathy. Therefore a high index of suspicion is required for early diagnosis and management of this disease in cirrhotic patients because it is a rapidly progressive and highly fatal disease.

CT is the initial investigation of choice, although in the early stages of the disease, changes are often minimal and non-specific⁽¹⁴⁾. Typical findings are diffuse thickening of the mucosa of involved sinuses. This is frequently accompanied by erosion or destruction of the bony sinus wall and extra sinusoidal spread of infection⁽¹⁵⁾. Histological diagnosis of mucormycosis can be presumed on the basis of broad ribbon-like hyphae, haphazardly branched. The aetiological agents of mucormycosis are readily seen with haematoxylin and eosin tissue stains (Fig. 1). Special fungal stains like Gomori methenamine silver can be helpful, although other fungal stains such as periodic acid-schiff and Gridley stain mucor poorly⁽³⁾.

With the increasing recognition of the typical features, early diagnosis by radiology and histopathology and the development of amphotericin B, the morbidity and mortality of the disease have reversed dramatically. The main stays of therapy are reversal of the source of immunocompromisation, early institution of systemic high dose amphotericin B and surgical debridement of non-viable tissue⁽¹⁴⁾. With this approach, the survivorship in diabetic patients ranges from 60% to 90%, whereas in leukaemia patients it is 20%–50%^(4,16). Six-week post-treatment survival was 33% in another series⁽¹⁴⁾ from a regional country. Unfortunately, there are some practical problems in the management of rhino-cerebral mucormycosis in patients with cirrhosis especially decompensated cases. Due to deranged coagulation and thrombocytopenia in patients with cirrhosis, surgical management of the involved tissues is difficult. Patients and their relatives are not willing for

any surgical procedure. Even surgeons and anaesthetists are sometimes reluctant.

Amphotericin B is the cornerstone of pharmacological therapy. Due to its significant side effects of renal toxicity and electrolyte imbalance, it is difficult to administer this drug in patients with cirrhosis.

Repeated surgical debridement with pharmacological therapy is necessary for a good control of the disease and better outcome⁽¹⁷⁾. However, therapeutic options are limited due to the toxicity of the currently-available antifungal therapy and unsuitability of patients with advanced liver disease for any aggressive surgical intervention. In our case series, repeated surgical debridement was possible in only two cases. Other patients were either too ill or their family refused to consent for any surgical intervention due to the underlying advanced chronic liver disease. Aggressive control of predisposing illness is considered another important determinant of survival⁽¹⁸⁾. Optimal control of hyperglycaemia and ketoacidosis may not be a problem. Unfortunately in decompensated liver diseases, most of the hormonal and metabolic systems of the body are irreversibly altered and liver transplantation may be the only way to normalise these derangements.

In this case series from a tertiary care hospital, mortality was 100% in spite of all possible available therapeutic measures for this disease. Only one patient was able to complete a course of amphotericin B but he also expired shortly after his discharge. These patients had different complications of chronic liver disease, like encephalopathy, SBP, hepatorenal syndrome and HCC, which made the management of this disease very difficult.

In conclusion, this paper describes the clinical presentation and outcome of rhinocerebral zygomycosis in six patients with hepatic cirrhosis. A high index of suspicion is required for the diagnosis of this rare and potentially fatal complication in patients with advanced cirrhosis and who

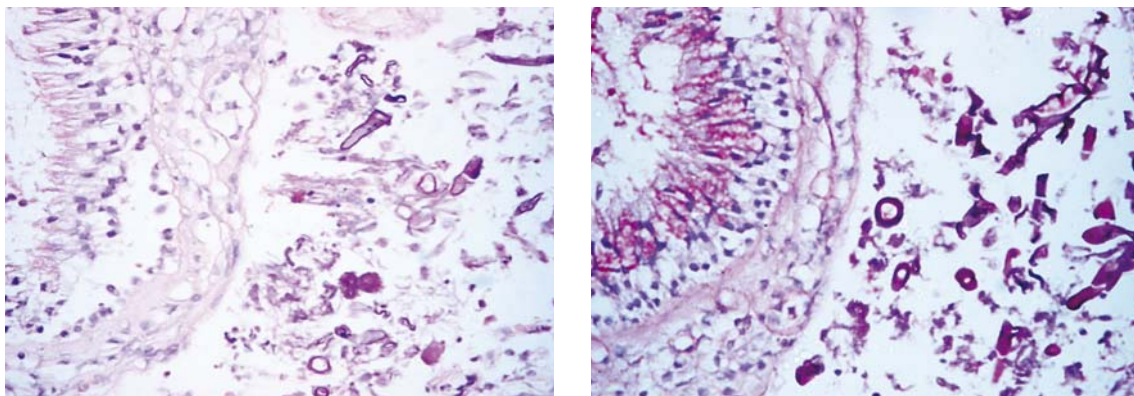


Fig. 1 Photomicrographs from Case 5 show mucormycosis hyphae and spores with haematoxylin and eosin (H & E) stain (left) and periodic acid schiff with diastase (PASD) stain (right).

develop sepsis and fail to respond to conventional antibiotic therapy. Four patients had a known predisposing condition, which was diabetes mellitus. But diabetes mellitus in these patients was related to the liver; a consequence of hepatitis C, cirrhosis or steroid therapy for autoimmune liver disease. In two cases, no known risk factor existed. Role of cirrhosis per se or associated HCC as risk factors for zygomycosis are not yet reported. The poor outcome of all of these patients was related to the underlying condition (diabetes mellitus, decompensated cirrhosis, HCC), site of infection, and inability to offer adequate antifungal and surgical treatments in most of the cases.

REFERENCES

- Peterson KL, Wang M, Canalis RF, Abemayor E. Rhinocerebral mucormycosis: evaluation of the disease and treatment options. *Laryngoscope* 1997;107:855-62.
- Sugar AM. Agents of mucormycosis and related species. Infectious disease and their etiological agents. In: Mandell G, Bennett J, Polin R, eds. *Principles and Practices of Infectious Diseases*. 4th ed. New York: Churchill Livingstone, 1995: 2311-20.
- Rippon JW. Mucormycosis. In: *Medical Mycology. Fungi and Pathogenic Actinomycetes*. 2nd ed. Philadelphia: WB Saunders, 1982: 615-40.
- Blitzer A, Lawson W, Meyers BR, Biller HF. Patient survival factors in paranasal sinus mucormycosis. *Laryngoscope* 1980; 90:635-48.
- Sugar AM. Mucormycosis. *Clin Infect Dis* 1992; 14 suppl 1:S126-9.
- El-Serag HB, Anand B, Richardson P, Rabeneck L. Association between hepatitis C infection and other infectious diseases: a case for targeted screening? *Am J Gastroenterol* 2003; 98:167-74.
- Yakoob J, Jafri W, Hussainy AS. *Candida oesophagitis with hepatitis C virus: an uncommon association*. *Eur J Gastroenterol Hepatol* 2003;15:701-3.
- Georgopoulou S, Kounougeri E, Katsenos C, Rizos M, Michalopoulos A. Rhinocerebral mucormycosis in a patient with cirrhosis and chronic renal failure. *Hepatogastroenterology* 2003; 50:843-5.
- Davari HR, Malekhossini SA, Salehi HA, et al. Outcome of mucormycosis in liver transplantation: four cases and a review of literature. *Exp Clin Transplant* 2003; 1:147-52.
- Mason AL, Lau JY, Hoang N, et al. Association of diabetes mellitus and chronic hepatitis C virus infection. *Hepatology* 1999; 29:328-33. Comment in: *Hepatology* 1999; 30:584. *Hepatology* 1999; 29:604-5, *Hepatology* 1999; 30:342.
- Noto H, Raskin P. Hepatitis C infection and diabetes. *J Diabetes Complications* 2006;20:113-20.
- Talmi YP, Goldschmied-Reouven A, Bakon M, et al. Rhino-orbital and rhino-orbito-cerebral mucormycosis. *Otolaryngol Head Neck Surg* 2002; 127:22-31.
- Yohai RA, Bullock JD, Aziz AA, Markert RJ. Survival factors in rhino-orbital-cerebral mucormycosis. *Surv Ophthalmol* 1994; 39:3-22.
- Dhiwakar M, Thakar A, Bahadur S. Improving outcomes in rhinocerebral mucormycosis — early diagnostic pointers and prognostic factors. *J Laryngol Otol* 2003; 117:861-5.
- Estrem SA, Tully R, Davis WE. Rhinocerebral mucormycosis: computed tomographic imaging of cavernous sinus thrombosis. *Ann Otol Rhinol Laryngol* 1990; 99:160-1.
- Pillsbury HC, Fischer ND. Rhinocerebral mucormycosis. *Arch Otolaryngol* 1977; 103:600-4.
- Nithyanandam S, Jacob MS, Battu RR, et al. Rhino-orbito-cerebral mucormycosis. A retrospective analysis of clinical features and treatment outcomes. *Indian J Ophthalmol* 2003; 51; 231-6. Comment in: *Indian J Ophthalmol* 2004; 52:171-2; author reply 172, *Indian J Ophthalmol* 2004; 52:82; author reply 82-3.
- Blitzer A, Lawson W, Meyers BR, Biller HF. Patient survival factors in paranasal sinus mucormycosis. *Laryngoscope* 1980; 90:635-48.