

Delayed diagnosis of chronic mesenteric ischaemia

Woon CYL, Tay KH, Tan SG

ABSTRACT

Chronic mesenteric ischaemia is a rare disease. Patients typically present with a protracted course of vague abdominal symptoms and profound weight loss, leading to a delay in diagnosis. If untreated, it progresses to bowel infarction, which has a poor prognosis. Once diagnosed, however, it can be easily remedied via endovascular stenting or open surgery. Symptom reversal is prompt and patients rapidly achieve premorbid habitus. We report a 58-year-old man in whom the diagnosis was missed for two years, during which numerous investigations were performed. The diagnosis was eventually revealed on angiography, and he was cured by mesenteric bypass surgery. For patients with the triad of chronic, unrelenting weight loss, sitophobia (food fear) and postprandial abdominal pain, this condition must be considered, and actively sought after with angiography.

Keywords: angiography, duplex ultrasonography, mesenteric blood flow, mesenteric ischaemia

Singapore Med J 2007; 48(1):e9–e12

INTRODUCTION

Chronic mesenteric ischaemia (CMI), or intestinal angina, is a rare disease. Left untreated, 26%–66% of patients with multivessel disease eventually develop acute thrombosis and bowel infarction⁽¹⁾. The diagnosis is easily missed as patients present with weight loss and abdominal pain for which the list of differential diagnoses is extensive. These patients may undergo extensive investigations over a protracted period before a diagnosis is reached. We present a case of CMI successfully treated by antegrade bypass surgery. CMI is a curable disease that should always be a differential diagnosis in patients with chronic weight loss.

CASE REPORT

A 58-year-old man had a history of Billroth I gastrectomy performed more than 20 years ago for

peptic ulcer disease and a 30-year smoking history. He first presented with colicky pain in the right hypochondrium and epigastrium. He was diagnosed with acute cholecystitis and underwent open cholecystectomy. Recovery was uneventful. Over the following two years, he was admitted ten times for colicky left hypochondriac and epigastric pain, often worse postprandially, poor appetite, diarrhoea, and weight loss of 13 kg. Abnormalities on blood investigations included mildly-elevated alkaline phosphatase, gamma glutamyl transferase, serum amylase and urine amylase. Repeated oesophagogastroduodenoscopies (OGDs), colonoscopies, barium studies, abdominal computed tomography (CT) and magnetic resonance cholangiopancreatography scans were normal. He finally underwent a coeliac plexus block for pain relief.

Two months later, he returned with similar abdominal symptoms. Owing to his severely cachectic appearance and the persistence of symptoms, the diagnosis of CMI was entertained. Mesenteric angiography revealed chronic occlusion at the origins of both the coeliac axis (CA) and superior mesenteric artery (SMA), and severe stenosis at the origin of the inferior mesenteric artery (IMA). He underwent an antegrade mesenteric bypass with a 14 mm (main stem diameter) × 7 mm (individual leg diameter) bifurcated Dacron graft anastomosed from supracoeliac aorta (proximal end) to common hepatic artery (CHA) and SMA (two distal ends) (Figs. 1–2b). After the surgery, his body weight reached a nadir of 27 kg. With adequate enteral nutritional supplementation, he gained 3 kg over the next two weeks and eventually discharged.

Two and a half years after surgery, the bifurcated graft remains patent on follow-up CT angiograms (Fig. 3). The patient remained symptom-free, and has gained a total of 16 kg since discharge from the hospital and has given up smoking. His current appearance contrasts starkly with his preoperative appearance two years ago (Figs. 4a–b). In retrospect, a review of his previous abdominal CT images revealed that there was indeed occlusion of the coeliac artery and gradual occlusion of the SMA during the two years of follow-up for abdominal complaints. This finding was not noted previously.

Department of
Surgery,
Singapore General
Hospital,
Outram Road,
Singapore 169608

Woon CYL, MBBS
Medical Officer

Tan SG, MBBS,
FRCSG, FAMS
Senior Consultant

Department of
Diagnostic
Radiology

Tay KH, MBBS,
FRCR, FAMS
Senior Consultant

Correspondence to:
Dr Colin Woon
Tel: (65) 6321 4051
Fax: (65) 6220 9323
Email: wolv23@
gmail.com

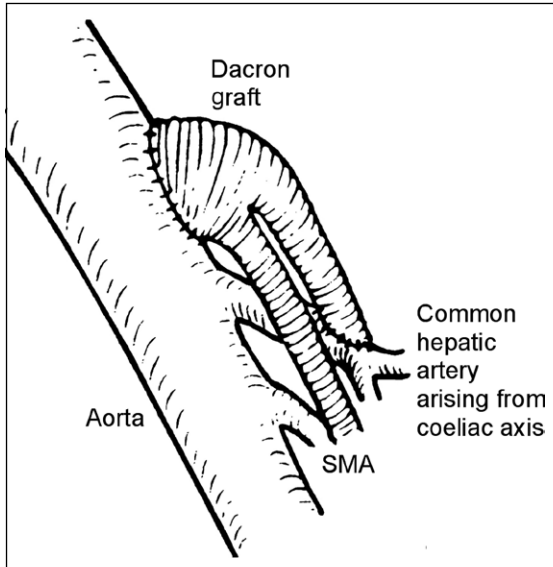


Fig. 1 Diagram illustrates the antegrade bifurcated Dacron graft from the supracoeliac aorta to the common hepatic artery.

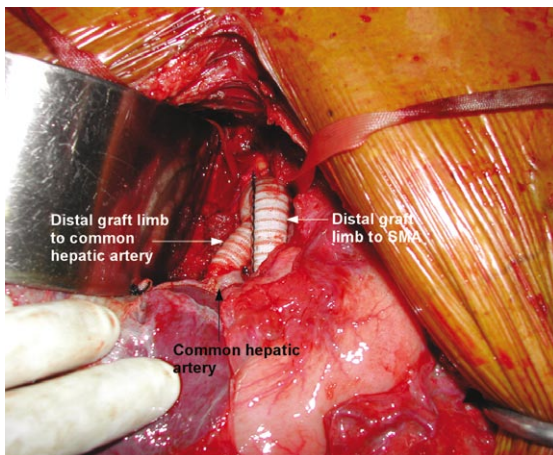


Fig. 2a Operative photograph shows a bifurcated antegrade Dacron graft anastomosis from the supracoeliac aorta to the common hepatic artery (one of two limbs).

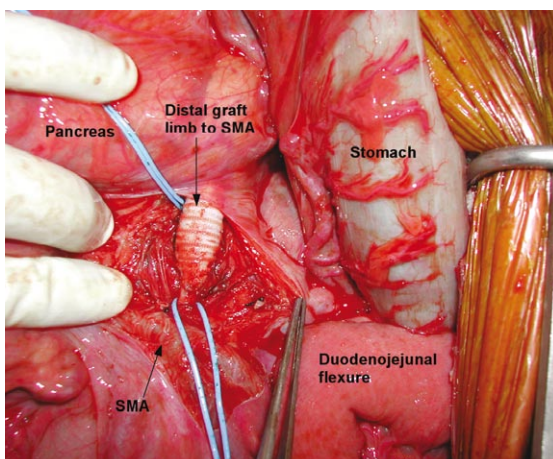


Fig. 2b Operative photograph shows the distal-limb anastomosis to the SMA via the retropancreatic approach.

DISCUSSION

This patient's long history illustrates the difficulty in diagnosing this disease. CMI is often mistaken for peptic ulcer disease, cholecystitis, liver disease, diverticular disease and malignancy⁽²⁾. It occurs in patients with advanced atherosclerosis, and is associated with atherosclerotic risk factors such as smoking, hypertension, cerebrovascular disease, and coronary artery disease. Unlike other ischaemic diseases, CMI is more common in females, with a 3:1 ratio of women to men^(2,3). In most patients, two or more visceral arteries are involved. Three-vessel involvement, such as in this patient, occurs in 33% of patients. The SMA is most commonly affected in up to 92%, CA in 83%, and both SMA and CA in 78% of patients⁽²⁾. In younger patients, median arcuate ligament compression or systemic vasculitis are other differential diagnoses^(1,2).

The classical clinical triad of postprandial abdominal pain, sitophobia and progressive weight loss was evident in this patient. Postprandial abdominal pain, noted by Councilman more than a century ago, is explained by obstruction of blood flow through the visceral arteries in the face of increasing postprandial metabolic demands⁽⁴⁾. Basal blood flow to CA and SMA measures 800 ml and 500 ml, respectively, increasing by 50%–100% after meals. Stenosis and occlusion prevent this increase in flow⁽¹⁾. Pain is typically dull and cramping epigastric or mid-abdominal pain, occurring 30 minutes to an hour after eating, and resolving one to two hours later. 91% of symptomatic patients harbour dual- or triple-vessel disease, as single-vessel disease rarely causes complaints owing to an extensive collateralisation among CA, SMA and IMA⁽⁵⁾.

The natural history of pain includes progression from postprandial to more prolonged periods, and from aggravation by large meals to smaller meals and even drinks, and finally rest pain, occurring without food or drink consumption, not unlike the natural history of cardiac angina, leading to the terms “intestinal angina” and “abdominal vascular rest pain”⁽¹⁾. Weight loss may be profound, typically 10–15 kg. Sitophobia, or “food fear”, arises from the anticipation of postprandial pain. Patients may also alter eating habits to avoid large meals and solid food (“small meal syndrome”). Nausea, vomiting, diarrhoea, or constipation are other atypical symptoms⁽¹⁻³⁾.

The abdominal pain is described as “out of proportion” with an unimpressive abdominal examination. Physical examination reveals a cachectic appearance from progressive weight loss owing to food fear. An epigastric arterial bruit may be heard, but this sign is present in less than 50% with arterial stenosis⁽¹⁾. Carotid and femoral bruit, as well as weak peripheral pulses point to advanced underlying

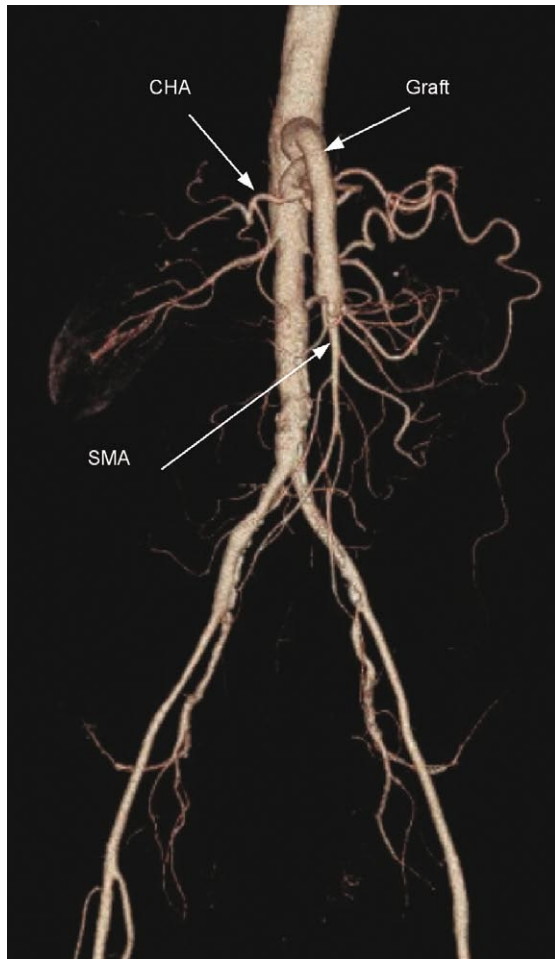


Fig. 3 Reconstructed CT angiogram image at two years postoperation shows a bifurcated Dacron graft from the supraceliac aorta to the CHA and SMA. The graft was patent at two-years follow-up.

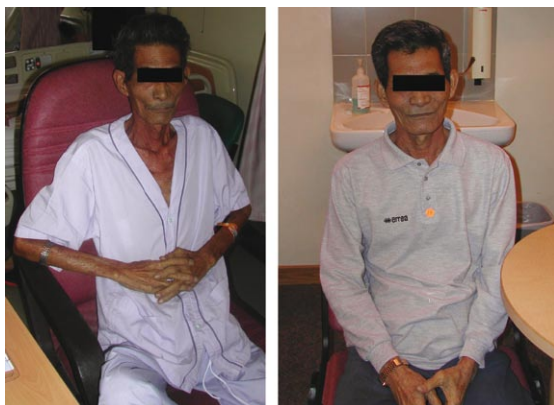

Fig. 4 Clinical photographs comparing the patient's (a) preoperative appearance and (b) his current appearance.

atherosclerotic disease, which is often present. Laboratory tests are not diagnostic but may reveal anaemia, hypoalbuminaemia, hypoproteinaemia and hypocholesterolaemia secondary to malnutrition. Abdominal radiographs, gastrointestinal contrast studies, colonoscopy and OGD are only helpful in exclusion of other differential diagnosis.

Duplex ultrasonography is the most widely used screening tool. The CA and SMA can be visualised in 80%–90% of patients. In the remaining 10%–20%, the arteries' location behind the air-filled stomach prevents proper visualisation⁽¹⁾. This modality is up to 96% sensitive, 96% specific and 96% accurate in predicting SMA stenosis, and up to 100% sensitive, 88% specific and 97% accurate in predicting CA stenosis⁽³⁾. However, where surgical intervention is planned, contrast angiography is mandatory. Mesenteric angiography, CT angiography (CTA) and magnetic resonance angiography (MRA) are the imaging modalities of choice for establishing a diagnosis. While biplanar selective splanchnic angiography remains the gold standard, CTA and MRA are emerging modalities that can confidently identify atherosclerotic changes (stenosis and occlusion) and collateral vessels, without the invasiveness of conventional angiography. Collateralisation, such as retrograde filling of the SMA or CA via the artery of Riolan, suggests chronic ischaemia. With overall sensitivity and specificity of 100% and 95%, respectively, MRA is gaining increasing acceptance in the diagnosis of mesenteric stenosis⁽¹⁾.

The goals of revascularisation are “to relieve pain, improve nutritional status and prevent progression to mesenteric infarction^(6,7).” Open surgery and endovascular methods are available alternatives, although the best treatment option is still a matter of debate. Among surgeons, there is still disagreement regarding the optimal site of graft origin (supraceliac versus infrarenal), conduit material (autologous versus synthetic), and single-versus multi-vessel revascularisation. With single-vessel disease, both operative or endovascular revascularisation can be considered. Open revascularisation was chosen in this case owing to extensive involvement of all three vessels with complete vascular occlusion in two vessels. In skilled hands, technical success rates approach 95%⁽⁷⁾. In complete occlusion, endovascular recanalisation is technically difficult and has a higher rate of complications and lower long-term patency, although anecdotal experience with augmentation by stents has been successful^(6,7).

Antegrade bypass from the supraceliac aorta was preferred in this patient. Unlike the infrarenal aorta, the supraceliac aorta is usually free of atherosclerotic and aneurysmal disease. Furthermore, prograde flow with reduced turbulence and reduced likelihood of graft kinking, is less susceptible to occlusion^(2,8). This approach preserves the infrarenal aorta for future revascularisation efforts as many patients have peripheral vascular disease⁽³⁾. Retrograde bypass from infrarenal aorta or iliac artery risks runs a long, tortuous course and risks graft kinking by overlying bowel. This method is preferred in ill patients who are unable to tolerate aortic clamping.

Two-vessel revascularisation was chosen to minimise symptom recurrence and provide a margin of safety against bowel infarction in the event of single graft occlusion⁽⁸⁾. The number of vessels revascularised influences five-year survival (73%, 57% and 0% for three-vessel, two-vessel and one-vessel repair, respectively) and five-year graft patency (90%, 54% and 0%, respectively)⁽⁶⁾. Revascularisation of the SMA was critical for success while IMA reconstruction could be safely ignored^(8,9). Both synthetic conduits (Dacron or PTFE) and native veins (long saphenous vein or superficial femoral vein) provide similar long-term patency rates and long-term symptom-free survival. Bifurcated synthetic graft was chosen in this patient owing to ease of anastomosis for dual-vessel revascularisation, compared with autologous vein graft.

Perioperative mortality for open surgery is 5%–15%, with morbidity rates of up to 30%. Underlying coronary artery disease and peripheral vascular disease and chronic malnutrition increase these rates further. Endovascular revascularisation has less inherent risks and is feasible where fewer vessels are involved⁽⁶⁾. Additional stent placement is preferred where there is residual stenosis of 30%, intimal flap dissection post angioplasty, or recurrent stenosis within 12 months of angioplasty⁽⁷⁾. Endovascular revascularisation can attain initial technical success rates up to 96%⁽¹⁰⁻¹²⁾. Primary patency rates of up to 85% and primary assisted patency rates of up to 91% at 11 months have been reported⁽¹²⁾.

Retrospective comparison of angioplasty and stenting versus open revascularisation revealed similar morbidity, 30-day mortality, and long-term survival⁽⁶⁾. For elderly patients of more than 70 years of age, however, open surgery carries higher morbidity and mortality rates⁽⁸⁾. Endovascular therapy is further associated with higher incidence of symptom recurrence (up to 17%) and restenosis (up to 29%) especially with single-vessel revascularisation⁽¹¹⁾. Therefore, it should be reserved for the elderly or patients deemed to be poor surgical candidates. In malnourished patients, stenting may have a place as bridge therapy for open revascularisation after a period of optimisation. In fit patients, surgical revascularisation should be preferentially offered⁽⁶⁾.

Postoperative follow-up should include graft imaging to determine patency. Symptoms are only 33% sensitive in this respect⁽³⁾. As a result of extensive

collaterals, complete graft occlusion can occur long before symptoms are produced. Although CT angiography was done in this case at two years, surveillance duplex scanning performed at closer intervals has been suggested as a more economically-viable alternative⁽³⁾.

In conclusion, CMI should be considered in patients who present with the triad of chronic postprandial abdominal pain, weight loss and sitophobia. Abdominal imaging such as CT may not detect this condition, unless actively sought after, and angiography of visceral vessels should be performed to secure the diagnosis. As an adjunct, we strongly advocate smoking cessation in patients undergoing either surgical or endovascular procedures. Open surgery remains the mainstay of treatment, although percutaneous angioplasty and stenting are possible options in the poor surgical candidate. Early treatment will ultimately prevent progression to bowel infarction.

REFERENCES

1. Kolkman JJ, Mensink PBF, van Petersen AS, Huisman AB, Geelkerken RH. Clinical approach to chronic gastrointestinal ischaemia: from 'intestinal angina' to the spectrum of chronic splanchnic disease. *Scand J Gastroenterol Suppl* 2004; (241):9-16.
2. Moawad J, McKinsey JF, Wyble CW, et al. Current results of surgical therapy for chronic mesenteric ischemia. *Arch Surg* 1997; 132:613-9.
3. Leke MA, Hood DB, Rowe VL, et al. Technical consideration in the management of chronic mesenteric ischemia. *Am Surg* 2002; 68:1088-92.
4. Councilman WT. Three cases of occlusion of the superior mesenteric artery. *Boston Med Surg J* 1894; 130:410-1.
5. Brandt LJ, Boley SJ. AGA technical review on intestinal ischemia. American Gastrointestinal Association. *Gastroenterology* 2000; 118:954-68.
6. Kasirajan J, O'Hara PJ, Gray BH, et al. Chronic mesenteric ischemia: open surgery versus percutaneous angioplasty and stenting. *J Vasc Surg* 2001; 33:63-71.
7. Matsumoto AH, Angle JF, Spinosa DJ, et al. Percutaneous transluminal angioplasty and stenting in the treatment of chronic mesenteric ischemia: results and longterm followup. *J Am Coll Surg* 2002; 194 (1 Suppl):S22-31.
8. Park WM, Cherry KJ Jr, Chua HK, et al. Current results of open revascularization for chronic mesenteric ischemia: a standard for comparison. *J Vasc Surg* 2002; 35:853-9.
9. Foley MI, Moneta GL, Abou-Zamzam AM, et al. Revascularization of the superior mesenteric artery alone for treatment of intestinal ischemia. *J Vasc Surg* 2000; 32:37-47.
10. Allen RC, Martin GH, Rees CR, et al. Mesenteric angioplasty in the treatment of chronic mesenteric ischemia. *J Vasc Surg* 1996; 24:415-23.
11. Silva JA, White CJ, Collins TJ, et al. Endovascular therapy for chronic mesenteric ischemia. *J Am Coll Cardiol* 2006; 47:944-50.
12. Sharafuddin MJ, Olson CH, Sun S, Kresowik TF, Corson JD. Endovascular treatment of celiac and mesenteric arteries stenoses: applications and results. *J Vasc Surg* 2003; 38:692-8.