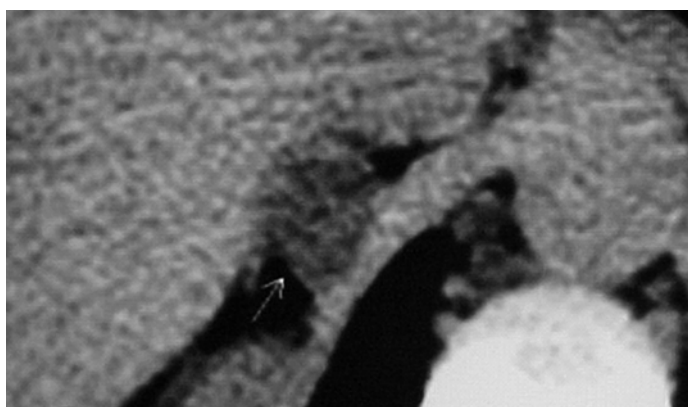


**CME Article****Clinics in diagnostic imaging (I13)**

Vieira MT, Costa AFP, Resurreição FM, dos Santos VM

**Fig. 1** Magnified abdominal CT image coned to the right adrenal gland.**CASE PRESENTATION**

A 27-year-old Brazilian woman came to hospital because of refractory hypertension. It was detected when she was 19 years old, during her second pregnancy, which evolved with pre-eclampsia and miscarriage. About one year later, her third pregnancy also resulted in miscarriage. She was unsuccessfully treated with a low salt diet, atenolol, hydrochlorothiazide and nifedipine in another hospital. During the last five years, she used medications such as chlorthalidone 50 mg/day, atenolol 100 mg/day, enalapril 40 mg/day, and hydralazine 50 mg/day. Despite this, the hypertension remained refractory with blood pressure elevations to 270/140 mmHg, and she developed weakness, paraesthesia, cramps and hypertensive crises. More recently, the use of captopril 100 mg/day and spironolactone 50 mg/day caused a mild reduction in hypertension, and she was sent for our evaluation. On admission, she related bathing in rivers from an endemic area of schistosomiasis, and there was a positive family history of hypertension, without nephropathy. She complained of polyuria, but had no

oedema, weight gain, snoring, morning headaches, daytime sleepiness, palpitations, nor pallor. Body temperature, thyroid, lungs, heart and peripheral pulses were essentially normal. Blood pressure was 220/180 mmHg in the right arm, 220/170 mmHg in the left arm, 200/150 mmHg in the right thigh and 210/150 mmHg in the left thigh. Abdominal, neurological and fundoscopic examinations were essentially normal. Blood investigations were: haematocrit 33.6%, normal erythrocyte sedimentation rate (ESR), glucose 4.1 mmol/L, urea 7.1 mol/L, creatinine 70 µmol/L, sodium 133 mmol/L, potassium 2.2 mmol/L, creatinine clearance 84.7 ml/min, LE cells negative, proteinuria 140 mg/24 hours, total metanephrine 0.30 mg/g creatinine, normetanephrine 0.26 mg/g creatinine, epinephrine 180.5 pg/ml, norepinephrine 1.285 pg/ml, dopamine 32.01 pg/ml, plasma aldosterone (PA) 40.7 ng/dL, plasma renin activity (PRA) 0.40 ng/ml/h, and PA/PRA ratio >100. An echocardiogram showed left ventricle hypertrophy, and renal scanning with <sup>99m</sup>Tc-DTPA was normal. Computed tomography (CT) of abdomen was performed (Fig. 1). What is the diagnosis?

Armed Forces  
Hospital (HFA),  
Estrada do  
Contorno do  
Bosque s/n,  
Brasília-DF  
70603-900,  
Brazil

Vieira MT, MD  
Physician

Department of  
Nephrology,  
Sugar and Alcohol  
Agroindustry  
Hospital,  
Av Fernandes Lima  
Km 05,  
Maceió-AL  
57057-000,  
Brazil

Costa AFP, MD, PhD  
Physician

Resurreição FM, MD  
Physician

Department of  
Internal Medicine,  
Catholic University  
and HFA,  
Estrada do  
Contorno do  
Bosque s/n,  
Brasília-DF  
70603-900,  
Brazil

dos Santos VM,  
MD, PhD  
Professor

**Correspondence to:**  
Prof Vitorino  
Modesto dos Santos,  
SMPW Quadra 14  
Conjunto 2 Lote 7  
Casa A,  
Setor de Mansões  
Park Way,  
Brasília-DF 71745-  
140,  
Brazil  
Tel: (55) 61 3380 2666  
Fax: (55) 61 3233 1599  
Email:  
vitorinomodesto@  
gmail.com

## IMAGE INTERPRETATION


The abdominal CT showed a well-defined ovoid hypodense (measuring 7 HU) mass (arrowed) in the right adrenal gland. This is highly suggestive of a benign adrenal neoplasm.

## DIAGNOSIS

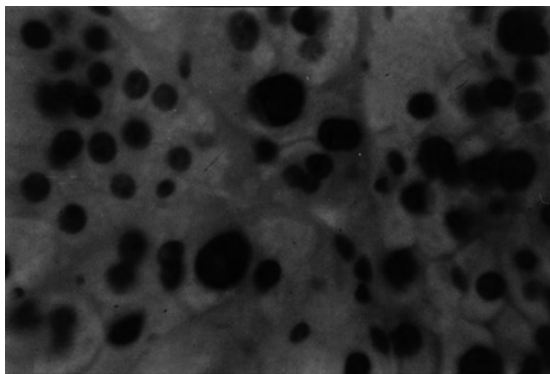
Primary hyperaldosteronism (Conn's syndrome) due to unilateral aldosteronoma.

## CLINICAL COURSE

The association of severe hypokalaemia with refractory hypertension, and high levels of serum aldosterone with low renin and elevated PA/PRA ratio reinforced the diagnosis of primary hyperaldosteronism, which was further confirmed by abdominal CT (Fig.1). The right adrenal gland was resected and pathological findings of the resected specimen were characteristic of those of aldosteronoma (Figs. 2–3). Since the first day after surgery, her blood pressure declined to a stable average of 100/60 mmHg and her serum potassium normalised. During subsequent ambulatory follow-up visits, she remained asymptomatic, normokalaemic, and required no antihypertensive drugs.



**Fig. 2** Specimen photograph of the right adrenal gland shows a solitary encapsulated mass with bright-yellow cut surface.



**Fig. 3** Photomicrograph of the adrenal mass shows a high percentage of cortical cells with occasional pleomorphism and absence of anaplasia (x 200). Special stain with sudan shows that these cells contain abundant fat.

## DISCUSSION

Jerome W Conn described arterial hypertension and hypokalaemic metabolic alkalosis in a middle-aged woman with primary hyperaldosteronism nearly five decades ago, a syndrome that still bears his name<sup>(1)</sup>. Classically, it occurs in 0.1%–0.5% of the hypertensive population, diagnosed through plasma aldosterone and renin activity determinations, their ratios<sup>(2–4)</sup>, in addition to tests for autonomous aldosterone secretion such as the salt loading test<sup>(3)</sup>. The first clue to diagnosis used to be a spontaneous or excessive hypokalaemia and refractory hypertension; nevertheless, the normokalaemic subgroups should warrant consideration<sup>(2,5–8)</sup>. To distinguish between bilateral hyperplasia and unilateral aldosteronoma, when no obvious tumour is radiologically-visible, adrenal venous sampling (AVS) is required. Postural testing is now largely superseded by AVS, due to the relative inaccuracy and significant overlap in values attained using the former technique between bilateral and unilateral disease<sup>(3,6,9,10)</sup>.

In our patient, because of unremarkable biochemical information and absence of suggestive symptoms of hypokalaemia during the early years prior to being sent to our hospital, the patient followed long-standing treatment for “essential hypertension” before the diagnosis of hyperaldosteronism<sup>(6–8)</sup>. She was given a low salt diet. The refractory arterial hypertension raised the hypothesis of secondary hypertension. Furthermore, she had suffered two miscarriages, and developed suggestive features of primary hyperaldosteronism, such as hypokalaemia, hypertensive crises, paresthesia, and cramps<sup>(1,5,6)</sup>. Other causes of secondary hypertension include: renal parenchyma diseases and renal artery stenosis, aortic coarctation, Cushing syndrome, pheochromocytoma, obesity, and obstructive sleep apnoea.

Another concern was about the possibility of glomerulopathy associated with schistosomiasis. However, this parasite was not detected by parasitological study, and neither haematuria, proteinuria, nor high creatinine levels were found. As her blood pressure measured in four extremities in the supine and seated positions were comparable, and no bruits were audible, in addition to normal ophthalmoscopic findings, the hypotheses of aortic coarctation, renal artery stenosis and malignant hypertension were excluded. The normal creatinine clearance and the absence of inappropriately-elevated level of serum renin eliminated the differentials of malignant nephropathy and renin-producing tumour. The epinephrine and dopamine serum levels were found mildly elevated, possibly related to patient stress. In the absence of diagnostic levels of catecholamines and metanephrines, pheochromocytoma is most unlikely. As LE cells were negative, and the ESR and leukocyte counts were normal, the possibility of vasculitis was

not favoured. Moreover, the renal scanning showed no abnormalities indicative of renovascular diseases. The association of severe hypokalaemia with refractory hypertension, and high levels of serum aldosterone with low renin and elevated PA/PRA ratio reinforced the diagnosis of primary hyperaldosteronism<sup>(2,3)</sup>, which was further confirmed by abdominal CT (Fig.1)<sup>(9,10)</sup>.

In conclusion, primary hyperaldosteronism seems to remain undiagnosed, particularly when patients are normokalaemic<sup>(7, 8)</sup>. Although bilateral idiopathic hyperaldosteronism may not be surgically amenable, unilateral aldosteronoma is a potentially curable cause of hypertension in young people. Early detection of this condition allows the reversal of hypertension before development of lesions in target-organs<sup>(3, 5)</sup>, and prevention of miscarriages in future pregnancies.

#### ABSTRACT

**Primary hyperaldosteronism is described in a 27-year-old Brazilian woman from an endemic area of schistosomiasis. She presented with hypokalaemia, cramps and polyuria, refractory hypertension, plasma aldosterone of 40.7 ng/dL and aldosterone/renin activity ratio higher than 100, due to an associated long-standing unsuspected aldosteronoma. Computed tomography showed a well-defined ovoid right adrenal mass, which was subsequently resected and confirmed to be an aldosteronoma. During subsequent follow-up visits, she remained**

**asymptomatic, normokalaemic, and required no antihypertensive drugs. The differential diagnoses of refractory hypertension are discussed.**

**Keywords: adrenal gland neoplasm, Conn's syndrome, hypertension, primary hyperaldosteronism.**

*Singapore Med J 2007; 48(1):93-96*

#### REFERENCES

1. Conn JW. Presidential address. I. Painting background. II. Primary aldosteronism, a new clinical syndrome. *J Lab Clin Med* 1955; 45:3-17.
2. Mulatero P, Dluhy RG, Giacchetti G, et al. Diagnosis of primary aldosteronism: from screening to subtype differentiation. *Trends Endocrinol Metab* 2005; 16:114-9.
3. Seiler L, Rump LC, Schulte-Mönting J, et al. Diagnosis of primary aldosteronism: value of different screening parameters and influence of antihypertensive medication. *Eur J Endocrinol* 2004; 150:329-37.
4. Unger N, Schmidt IL, Pitt C, et al. Comparison of active renin concentration and plasma renin activity for the diagnosis of primary hyperaldosteronism in patients with an adrenal mass. *Eur J Endocrinol* 2004; 150:517-23.
5. Al Fehaily M, Duh QY. Clinical manifestation of aldosteronoma. *Surg Clin North Am* 2004; 84:887-905.
6. Loh KC. Approach to a patient with suspected primary aldosteronism. *Singapore Med J* 1999; 40:371-4.
7. Gordon RD. Primary aldosteronism – actual epidemics or false alarm? *Arq Bras Endocrinol Metabol* 2004; 48:666-73.
8. Williams JS, Williams GH, Raji A, et al. Prevalence of primary hyperaldosteronism in mild to moderate hypertension without hypokalaemia. *J Hum Hypertens* 2006; 20:129-36.
9. Lerttumnongtum P, Muttarak M, Visrutaratna P, Ya-In C. Imaging features of unusual adrenal masses. *Australas Radiol* 2004; 48:107-13.
10. Peh WCG, Muttarak M. Clinics in diagnostic imaging (39). Conn's syndrome due to adrenocortical adenoma (Conn's tumour). *Singapore Med J* 1999; 40:487-90.

**SINGAPORE MEDICAL COUNCIL CATEGORY 3B CME PROGRAMME**  
**Multiple Choice Questions (Code SMJ 200701B)**

	True	False
<b>Question 1.</b> Regarding hypokalaemia and reliable symptoms for mineralocorticoid excess:		
(a) Cramps and weakness are associated with hypokalaemia.	<input type="checkbox"/>	<input type="checkbox"/>
(b) Excessive renal Na <sup>+</sup> /K <sup>+</sup> exchange usually results in hypokalaemia.	<input type="checkbox"/>	<input type="checkbox"/>
(c) Reliable symptoms are not known for mineralocorticoid excess.	<input type="checkbox"/>	<input type="checkbox"/>
(d) Cramps and weakness are always present.	<input type="checkbox"/>	<input type="checkbox"/>
<b>Question 2.</b> Regarding vascular volume and polyuria in patients with hyperaldosteronism:		
(a) Polyuria may be associated with the antihypertensive regimen.	<input type="checkbox"/>	<input type="checkbox"/>
(b) Polyuria is usually due to kidney failure.	<input type="checkbox"/>	<input type="checkbox"/>
(c) Expanded vascular volume is associated with hypokalaemia and metabolic alkalosis.	<input type="checkbox"/>	<input type="checkbox"/>
(d) Sodium retention occurs at the expense of potassium and hydrogen excretion.	<input type="checkbox"/>	<input type="checkbox"/>
<b>Question 3.</b> Regarding causes of renin-angiotensin-independent mineralocorticoid excess:		
(a) Congenital adrenal hyperplasia is a common cause.	<input type="checkbox"/>	<input type="checkbox"/>
(b) Aldosterone-secreting adenoma is a common cause.	<input type="checkbox"/>	<input type="checkbox"/>
(c) Nephrotic syndrome is a common cause.	<input type="checkbox"/>	<input type="checkbox"/>
(d) Congestive heart failure is a common cause.	<input type="checkbox"/>	<input type="checkbox"/>
<b>Question 4.</b> Regarding schistosomiasis:		
(a) Schistosomiasis is a known cause of glomerulopathy in tropical areas.	<input type="checkbox"/>	<input type="checkbox"/>
(b) Schistosomiasis is a public health problem in the developing world	<input type="checkbox"/>	<input type="checkbox"/>
(c) Schistosomiasis is an enrolled cause of Conn's syndrome.	<input type="checkbox"/>	<input type="checkbox"/>
(d) <i>Schistosoma mansoni</i> affects the urinary tract as frequently as <i>Schistosoma haematobium</i> .	<input type="checkbox"/>	<input type="checkbox"/>
<b>Question 5.</b> Regarding early postoperative phase of adrenalectomy in patients with hyperaldosteronism:		
(a) Hypoaldosteronism rarely occurs.	<input type="checkbox"/>	<input type="checkbox"/>
(b) Suppression of the contralateral gland is a frequent occurrence.	<input type="checkbox"/>	<input type="checkbox"/>
(c) Life-threatening hyperkalaemia can occur if ACE-I are still not discontinued.	<input type="checkbox"/>	<input type="checkbox"/>
(d) Life-threatening hyperkalaemia can occur if spironolactone is still not discontinued.	<input type="checkbox"/>	<input type="checkbox"/>

**Doctor's particulars:**

Name in full: \_\_\_\_\_  
MCR number: \_\_\_\_\_ Specialty: \_\_\_\_\_  
Email address: \_\_\_\_\_

**SUBMISSION INSTRUCTIONS:**

(1) Log on at the SMJ website: [www.sma.org.sg/cme/smj](http://www.sma.org.sg/cme/smj) and select the appropriate set of questions. (2) Select your answers and provide your name, email address and MCR number. Click on "Submit answers" to submit.

**RESULTS:**

(1) Answers will be published in the SMJ March 2007 issue. (2) The MCR numbers of successful candidates will be posted online at [www.sma.org.sg/cme/smj](http://www.sma.org.sg/cme/smj) by 15 March 2007. (3) All online submissions will receive an automatic email acknowledgment. (4) Passing mark is 60%. No mark will be deducted for incorrect answers. (5) The SMJ editorial office will submit the list of successful candidates to the Singapore Medical Council.

**Deadline for submission: (January 2007 SMJ 3B CME programme): 12 noon, 25 February 2007**