

Apert syndrome with septum pellucidum agenesis

Tiwari A, Agrawal A, Pratap A, Lakshmi R, Narad R

ABSTRACT

Apert syndrome is characterised by craniosynostosis, associated with maxillary hypoplasia, symmetrical syndactyly of the hands and feet, and other systemic malformations including mental retardation. Apert syndrome and septo-optic dysplasia is rarely described. We describe the classical clinical and radiological findings of this syndrome in a 20-year-old woman. Though early surgical intervention is imperative for optimal outcome, in developing countries, it may not be possible to intervene at the right time due to financial constraints.

Keywords: Apert syndrome, craniosynostosis, septum pellucidum agenesis, syndactyly

Singapore Med J 2007; 48(2):e62–e65

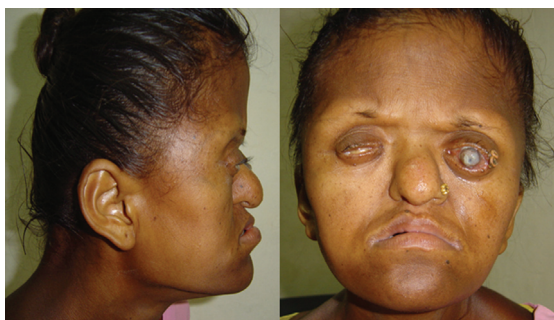

Fig. 1 Clinical photographs show a prominent mandible, ocular hypertelorism and mid-facial hypoplasia with left corneal opacity.

INTRODUCTION

Apert syndrome (AS) is characterised by craniosynostosis, associated with maxillary hypoplasia, symmetrical syndactyly of the hands and feet (which minimally involves digits 2, 3, and 4) and other systemic malformations including mental retardation.⁽¹⁻⁴⁾ AS in association with septo-optic dysplasia has rarely been described.⁽⁵⁾ In addition to the classical clinical and radiological findings of AS, this patient had corneal opacity and phthisis bulbi in the right eye.

CASE REPORT

A 20-year-old woman presented with dysmorphic features since childhood and progressive loss of vision in the right eye. The characteristic features on general physical examination were short stature, midface hypoplasia, prominent jaw, exophthalmia of the right eye with a hypoplastic optic disc, corneal opacity in the right eye and ocular hypertelorism (Fig. 1). She also had symmetrical syndactyly of all the digits of the hands and feet (Figs. 2–3), with fusion of fingernails of the three middle digits (synonychia). Her toenails were discoloured and fragile and a KOH examination from toenails and sole skin was positive for yeast. She was mentally subnormal with an intelligence quotient of less than 70. Radiographs of both hands showed bony fusion of phalanges (Fig. 4). Computed tomography (CT) of the brain and face revealed malformation of facial and cranial skeleton, agenesis of the septum pellucidum; ventriculomegaly and phthisis bulbi of the right eye (Figs. 5–7). The clinical and radiological features supported the diagnosis of AS.

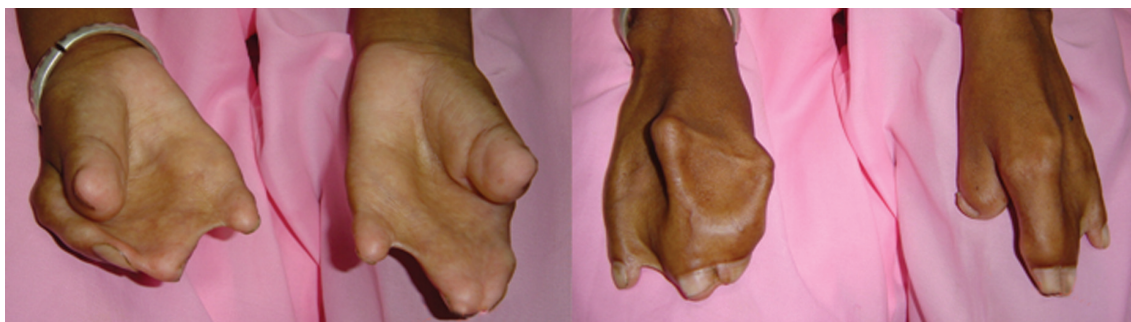

Fig. 2 Clinical photographs show syndactyly and fusion of nails (synonychia) of the digits of both hands.

Department of
Radiology,
B P Koirala Institute
of Health Sciences,
Dharan,
Nepal

Tiwari A, MD
Assistant Professor

Narad R, MBBS
Junior Resident

Department of
Surgery

Agrawal A, MCh
Assistant Professor in
Neurosurgery

Pratap A, MCh
Assistant Professor in
Paediatric Surgery

Department of
Medicine

Lakshmi R, MD
Assistant Professor

Correspondence to:
Dr Amit Agrawal
Tel: (977) 25 525 555
ext 2047
Fax: (977) 25 520 251
Email: dramitagrawal@gmail.com

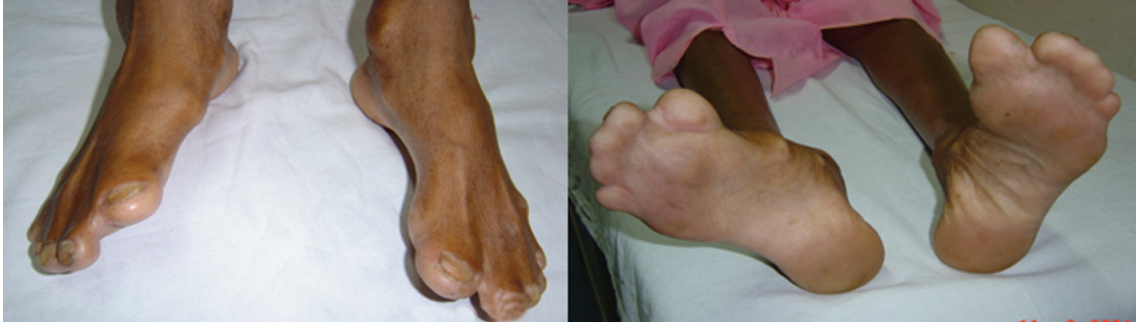

Fig. 3 Clinical photographs show fusion of the digits (syndactyly) and discoloured nails of both feet, with discoloured skin of the sole.

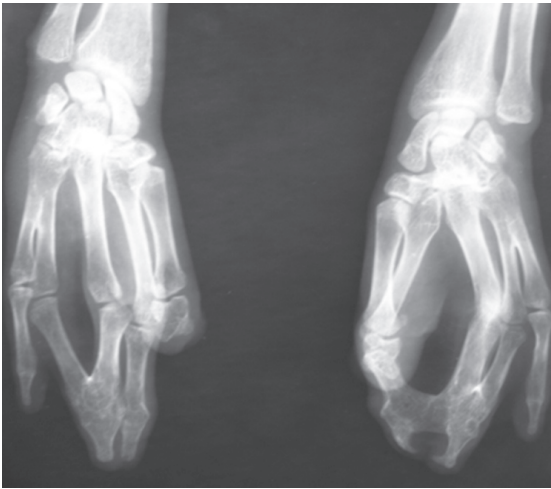

Fig. 4 Radiograph of both hands shows bony fusion of the phalanges of adjacent digits.

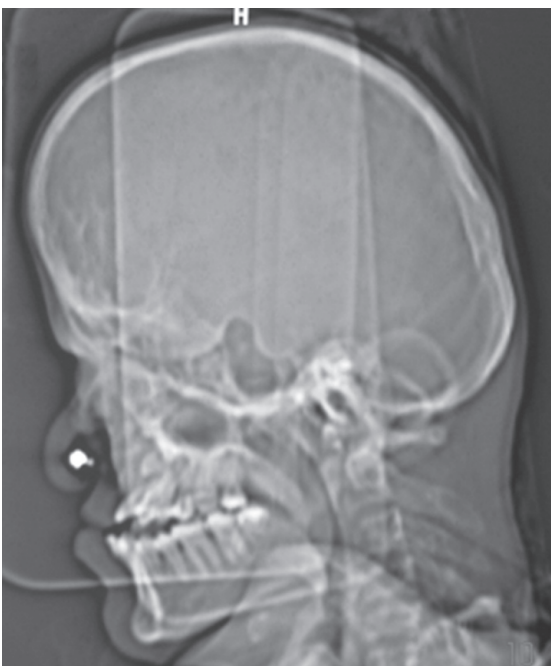


Fig. 5 Scout CT image shows a small anterior cranial fossa.

DISCUSSION

The incidence of AS is approximately one in 50,000 births. Some investigators state that 4.5% of all craniosynostosis represent AS.⁽²⁾ It may have an autosomal dominant inheritance but most cases are sporadic. The sporadic cases have been found to be associated with advanced paternal age.^(2,6) An embryopathic factor, released at 5–6 weeks gestation, is postulated to be the cause for this new association.⁽⁵⁾ In recent years, there has been an upsurge in the study of fibroblast-growth-factor receptors (FGFRs) as they affect human development. At least 15 different genetic dysplasias, such as AS, have been linked to FGFRs.^(7,8) Experiments have indicated that FGFR2 may act as a negative regulator of bone growth.⁽¹⁾ In AS, the mutation is known to occur at the Ser252 Trp site in the FGFR2 gene.⁽⁹⁾

The common skin manifestations in AS include hyperhidrosis, brittle nails, and synonychia. This combination often leads to candidal infection and colonisation. Severe acne that responds only to isotretinoin is also seen in association with AS.⁽¹⁰⁾ Other reported findings include hypopigmentation, hyperkeratosis, and excessive skin wrinkling of the forehead, shoulders, elbows, and knuckles.^(1,11) In AS, patients have a reduction in the size of the maxilla, particularly in the anteroposterior direction which results in tooth crowding. Cleft palate or bifid uvula is found in approximately 75% of patients. Dental anomalies such as impacted teeth, delayed eruption, ectopic eruption, supernumerary teeth, and thick gingiva are also common.⁽¹²⁾

The ocular manifestations, hypertelorism and exophthalmia, seem to be present in all cases. The ocular orbits are shallow and the accompanying exophthalmia may lead to blindness.⁽¹¹⁾ The most frequently reported cranial malformation is bilateral craniosynostosis of the coronal and lambdoid sutures along with reduction of the anterior, deep middle and

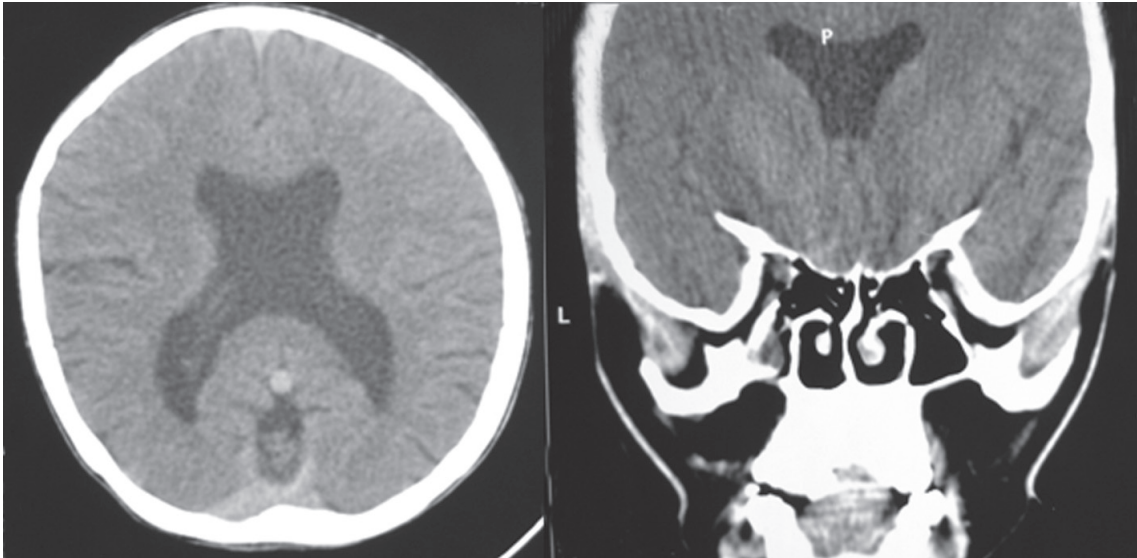


Fig. 6 Axial (left) and coronal (right) CT images of the brain show an absent septum pellucidum and ventriculomegaly.

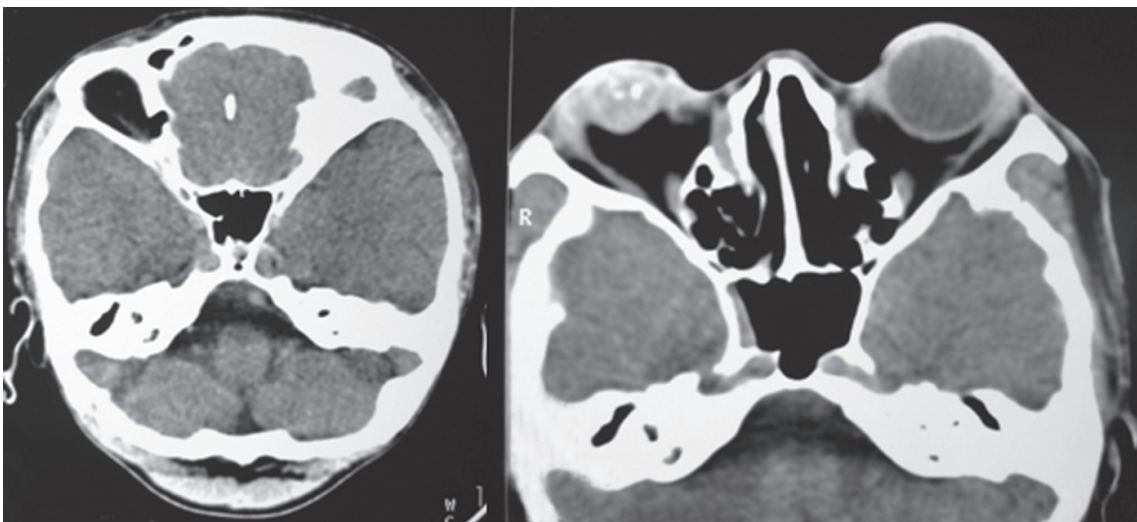


Fig. 7 Axial CT images show expansion of the middle cranial fossae with elevation and forward bowing of the sphenoid ridges and lateral bowing of the temporal squamosa. The orbital angle is also widened. There is also associated phthisis bulbi of the right eyeball (seen on the right image).

posterior cranial fossae that results in abnormalities in placement of the brain structures.⁽¹³⁾ The alterations in cranial shape due to multiple craniosynostosis can limit cerebral growth and development. Intracranial hypertension can occur in up to 45% of the cases, and result in higher morbidity and mortality in AS.⁽¹⁴⁻¹⁶⁾

The intracranial malformations usually reported in this syndrome are abnormalities of the corpus callosum, hypoplasia or absence of the septum pellucidum, hippocampal hypoplasia or dysplasia and cerebral cortex dysplasia.^(1,4) Ventriculomegaly, megalencephaly and gyral malformation have also

been reported.^(1,4,17) Absent septum pellucidum, optic nerve hypoplasia and short stature in this case were suggestive of septo-optic hypoplasia.⁽¹⁸⁾ Mental retardation occurs in most patients with AS and may be due to brain malformations, high intracranial pressure or family environment.^(1-4,14) Early operative intervention, preferably before the age of nine months, minimises mental retardation in these patients. Particular attention should also to be paid to the sociofamilial environment of the patient.⁽¹⁴⁾

The important findings on neuroimaging include ventricular enlargement, corpus callosum hypoplasia, septum pellucidum hypoplasia, cavum vergae and

arachnoid cysts.⁽⁴⁾ Magnetic resonance (MR) imaging is the preferred investigation of choice to demonstrate the anomalies of the brain in these patients, and a careful analysis is necessary to detect these associated brain abnormalities.⁽¹⁴⁾ Brain ultrasonography in infants and CT can also reveal central nervous system abnormalities where MR imaging is not available.⁽⁵⁾ Early surgical treatment of both cranial and facial malformations reduces the deleterious effects of increasing intracranial pressure on nervous structures, thereby leading to a harmonious development of cranioencephalic set and minimising the cognitive loss.⁽¹⁴⁾ Although the timing of surgery is controversial, the present tendency is to perform it early, before the first year of life.^(14,19) The surgical treatment proposes to remodel the skull in order to improve and redirect the vectorial growth of the restricted cranium, so as to improve the cerebral growth, facilitate breathing difficulties arising due to midface hypoplasia and improving the aesthetic aspects of the patients.^(14,19) Fronto-orbital advancement, the usual surgical technique, increases the intracranial volume and improves the disposition of encephalic structures previously deformed by a short skull.⁽⁴⁾ Early surgical intervention to correct the craniosynostosis is crucial in order to maximise the chances for normal development.⁽¹¹⁾

In conclusion, a strong multidisciplinary approach needs to be adopted in patients with AS. Neurosurgeons, plastic surgeons, otorhinolaryngologists, orthodontists, ophthalmologists, radiologists, geneticists, paediatricians and dermatologists must all work in concert to care for these patients. Until there are means to correct the molecular defect, we must rely on surgical and rehabilitative measures to improve the quality of life of these patients.⁽¹¹⁾ In developing countries, the appropriate management at an early stage is still not possible due to financial constraints.

REFERENCES

1. Cohen MM Jr, Kreiborg S. The central nervous system in the Apert syndrome. *Am J Med Genet* 1990; 35:36-45.
2. Albuquerque MA, Cavalcanti MG. Computed tomography assessment of Apert syndrome. *Pesqui Odontol Bras* 2004; 18:35-9.
3. Blank CE. Apert's syndrome (a type of acrocephalosyndactyly) – observations on a British series of thirty-nine cases. *Ann Hum Genet* 1960; 24:151-64.
4. Yacubian-Fernandes A, Palhares A, Giglio A, et al. Apert syndrome: analysis of associated brain malformations and conformational changes determined by surgical treatment. *J Neuroradiol* 2004; 31:116-22.
5. Teng RJ, Wang PJ, Wang TR, Shen YZ. Apert syndrome associated with septo-optic dysplasia. *Pediatr Neurol* 1989; 5:384-8.
6. Glaser RL, Broman KW, Schulman RL, et al. The paternal-age effect in Apert syndrome is due, in part, to the increased frequency of mutations in sperm. *Am J Hum Genet* 2003; 73:939-47.
7. McIntosh I, Bellus GA, Jab EW. The pleiotropic effects of fibroblast growth factor receptors in mammalian development. *Cell Struct Funct* 2000; 25:85-96.
8. Ibrahim OA, Chiu ES, McCarthy JG, Mohammadi M. Understanding the molecular basis of Apert syndrome. *Plast Reconstr Surg* 2005; 115: 264-70.
9. Doutetien C, Laleye A, Tchabi S, et al. [Apert's syndrome: a case report]. *J Fr Ophthalmol* 2003; 26:738-42. French.
10. Downs AM, Condon CA, Tan R. Isotretinoin therapy for antibiotic-refractory acne in Apert's syndrome. *Clin Exp Dermatol* 1999; 24:461-3.
11. Verma S, Draznin M. Apert syndrome. *Dermatol Online J* 2005; 11:15.
12. Vijayalakshmi AM, Menon A. Apert syndrome. *Indian Pediatr* 2002; 39:876-8.
13. Kreiborg S, Aduss H, Cohen MM Jr. Cephalometric study of the Apert syndrome in adolescence and adulthood. *J Craniofac Genet Dev Biol* 1999; 19:1-11.
14. Renier D, Arnaud E, Cinalli G, et al. Prognosis for mental function in Apert's syndrome. *J Neurosurg* 1996; 85:66-72.
15. Gault DT, Renier D, Marchac D, Jones BM. Intracranial pressure and intracranial volume in children with craniosynostosis. *Plast Reconstr Surg* 1992; 90:377-81.
16. Gosain AK, McCarthy JG, Wisoff JH. Morbidity associated with increased intracranial pressure in Apert and Pfeiffer syndromes: the need for long-term evaluation. *Plast Reconstr Surg* 1996; 97:292-301.
17. Hanieh A, David DJ. Apert's syndrome. *Childs Nerv Syst* 1993; 9:289-91.
18. Polizzi A, Pavone P, Iannetti P, Manfre L, Ruggieri M. Septo-optic dysplasia complex: a heterogeneous malformation syndrome. *Pediatr Neurol* 2006; 34:66-71.
19. Marchac D, Renier D, Broumand S. Timing of treatment for craniosynostosis and facio-craniosynostosis: a 20-year experience. *Br J Plast Surg* 1994; 47:211-22.