

The Walker-Warburg syndrome with cleft lip and palate

Pratap A, Agrawal A, Tiwari A, Lakshmi R, Rajbanshi S

ABSTRACT

The Walker-Warburg syndrome is a rare and lethal autosomal recessive disorder. We report a newborn male infant with the Walker-Warburg syndrome. He had typical clinical features, including lissencephaly, congenital muscular dystrophy and an ocular abnormality associated with cleft lip and palate without hydrocephalus.

Keywords: cleft lip, cleft palate, lissencephaly, Walker-Warburg syndrome

Singapore Med J 2007; 48(2):e66–e67

INTRODUCTION

The Walker-Warburg syndrome (WWS) is a rare and lethal autosomal recessive disorder characterised by cranial, cerebellar and retinal malformations, and congenital muscular dystrophy.⁽¹⁻⁶⁾ The WWS brain manifests with cobblestone lissencephaly with agenesis of the corpus callosum, fusion of hemispheres, hydrocephalus, dilatation of the fourth ventricle, cerebellar hypoplasia, hydrocephalus, and sometimes encephalocele.^(4,6-8) In the present case, we report an infant who had typical clinical features of WWS and a rare association with cleft lip and palate⁽⁹⁾ without hydrocephalus.

CASE REPORT

A four-day-old boy was born to second degree consanguineous parents at term with a birth weight of 2,400 g. At birth, he had unilateral macrocephaly, abnormal right eye, and severe hypotonia (Fig. 1). There was associated complete cleft lip and palate. Delivery was complicated by asphyxia and meconium aspiration. His 5- and 10-minute Apgar scores were 2 and 4, respectively. On examination, he was hypotonic, and had diminished spontaneous movements. Sucking was weak, but grasp and rooting reflexes were present. There was bilateral corneal clouding and megalocornea. Fundus examination showed severe myopic changes. Cranial computed tomography at seven days showed brain stem hypoplasia and abnormal gyral patterns, along with white matter hyperlucency and absent corpus callosum. There was abnormal enlargement of the right frontal bone with

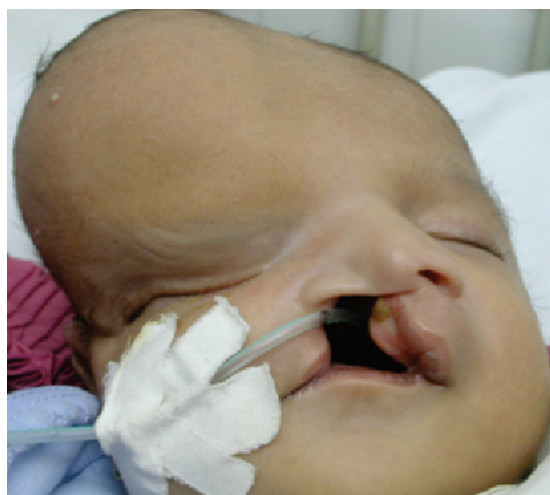

Fig. 1 Clinical photograph shows unilateral frontal bossing, complete cleft lip and cleft palate.

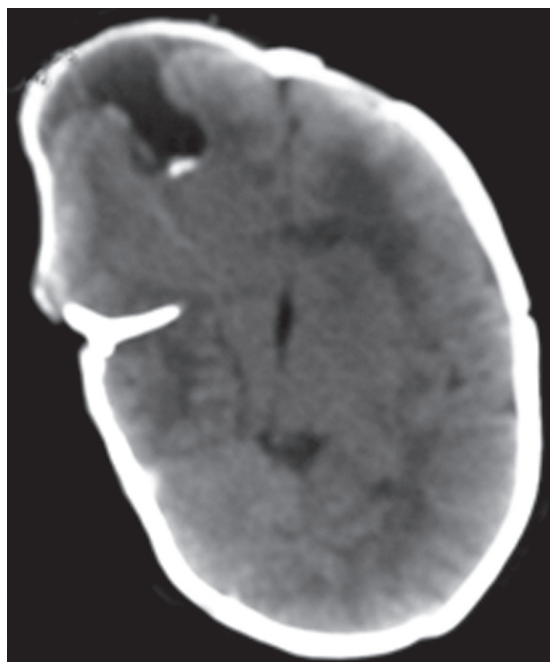


Fig. 2 Axial CT image shows right frontal encephalocele with cyst in the right frontal lobe, marked pachygyria. There was no hydrocephalus.

thinned-out underlying frontal cortex and presence of cyst (Fig. 2). Serum creatine kinase was raised (1,842 U/L). With all these features, a diagnosis of

Department of
Surgery,
B P Koirala Institute
of Health Sciences,
Dharan,
Nepal

Pratap A, MCh
Assistant Professor in
Paediatric Surgery

Agrawal A, MCh
Assistant Professor in
Neurosurgery

Rajbanshi S, MBBS
Junior Resident

Department of
Radiology

Tiwari A, MD
Assistant Professor

Department of
Medicine

Lakshmi R, MD
Assistant Professor

Correspondence to:

Dr Amit Agrawal
Tel: (977) 25 525 555
ext 2047
Fax: (977) 25 520 251
Email: dramitagrawal
@gmail.com

WWS was made. He died at two weeks of age. Postmortem was not performed due to unwillingness of the relatives.

DISCUSSION

Neuronal migration is a key process in the development of the cerebral cortex. During neocortex lamination, new sets of neurones proliferate at the subventricular zone and migrate alongside specialised radial glial fibres to occupy their final destinations in an “inside-out” fashion.⁽¹⁰⁾ More than 25 neuronal migration disorders resulting in death or improper positioning of the cortical neurones have been described in humans.⁽¹¹⁾ In the cobblestone neocortex, the postmitotic neurones do not respond to their stop signals and when crossing through the neocortex, bypass the glia limitans and invade the subarachnoid space. The resulting cortex is chaotically structured, consisting of an irregular lissencephalic surface and absence of lamination.^(12,13) Cobblestone lissencephalies are often seen in association with additional features, such as eye malformations and congenital muscular dystrophy.

WWS, muscle-eye-brain (MEB), and Fukuyama congenital muscular dystrophy (FCMD) are the three major entities of this group. Patients are classified into these three entities on the basis of the severity of the phenotype and the presence of syndrome-specific symptoms. WWS is the most severe syndrome of the group, especially with regard to the brain phenotype.^(7,8) Causative genes for WWS (POMT1),⁽¹²⁾ FCMD (Fukutin),⁽¹⁴⁾ and MEB (POMGnT1)⁽¹⁵⁾ have been identified. WWS is genetically heterogeneous, and approximately 20% of the patients show POMT1

mutations.⁽¹²⁾ To date, WWS is almost always a lethal congenital disorder.

REFERENCES

1. Rhodes RE, Hatten HP Jr, Ellington KS. Walker-Warburg syndrome. *AJNR Am J Neuroradiol* 1992; 13:123-6.
2. De Wilde G, Hansens M, Govaert P. The Walker-Warburg syndrome. *Bull Soc Belge Ophtalmol* 1992; 243:129-38.
3. Rodgers BL, Vanner LV, Pai GS, Sens MA. Walker-Warburg syndrome: report of three affected sibs. *Am J Med Genet* 1994 15; 49:198-201.
4. Asano Y, Minagawa K, Okuda A, et al. A case of Walker-Warburg syndrome. *Brain Dev* 2000; 22:454-7.
5. Yamaguchi E, Hayashi T, Kondoh H, et al. A case of Walker-Warburg syndrome with uncommon findings. Double cortical layer, temporal cyst and increased serum IgM. *Brain Dev* 1993; 15:61-5.
6. Pabuscus Y, Bulakbasi N, Kocaoglu M, Ucoz T. Walker-Warburg syndrome variant. *Comput Med Imaging Graph* 2002; 26:453-8.
7. Cormand B, Pihko H, Bayes M, et al. Clinical and genetic distinction between Walker-Warburg syndrome and muscle-eye-brain disease. *Neurology* 2001; 56:1059-69. Comment in: *Neurology* 2001; 56:993-4.
8. Dobyns WB, Pagon RA, Armstrong D, et al. Diagnostic criteria for Walker-Warburg syndrome. *Am J Med Genet* 1989; 32:195-210. Comment in: *Am J Med Genet* 1990; 36:371-4.
9. Sahajananda H, Meneges J. Anaesthesia for a child with Walker-Warburg syndrome. *Paediatr Anaesth* 2003; 13:624-8.
10. Marin-Padilla M. Dual origin of the mammalian neocortex and evolution of the cortical plate. *Anat Embryol (Berl)* 1978; 152:109-26.
11. Lammens M. Neuronal migration disorders in man. *Eur J Morphol* 2000; 38:327-33.
12. de Bernabé DB, Currier S, Steinbrecher A, et al. Mutations in the O-mannosyltransferase gene POMT1 give rise to the severe neuronal migration disorder Walker-Warburg syndrome. *Am J Hum Genet* 2002; 71:1033-43.
13. de Bernabé DB, van Bokhoven H, van Beusekom E, et al. A homozygous nonsense mutation in the fukutin gene causes a Walker-Warburg syndrome phenotype. *J Med Genet* 2003;40:845-8.
14. Kobayashi K, Nakahori Y, Miyake M, et al. An ancient retrotransposal insertion causes Fukuyama-type congenital muscular dystrophy. *Nature* 1998; 394:388-92.
15. Yoshida A, Kobayashi K, Many H, et al. Muscular dystrophy and neuronal migration disorder caused by mutations in a glycosyltransferase, POMGnT1. *Dev Cell* 2001; 1:1717-24.