

# Trichobezoars in the stomach and ileum and their laparoscopy-assisted removal: a bizarre case

Palanivelu C, Rangarajan M, Senthilkumar R, Madankumar M V

## ABSTRACT

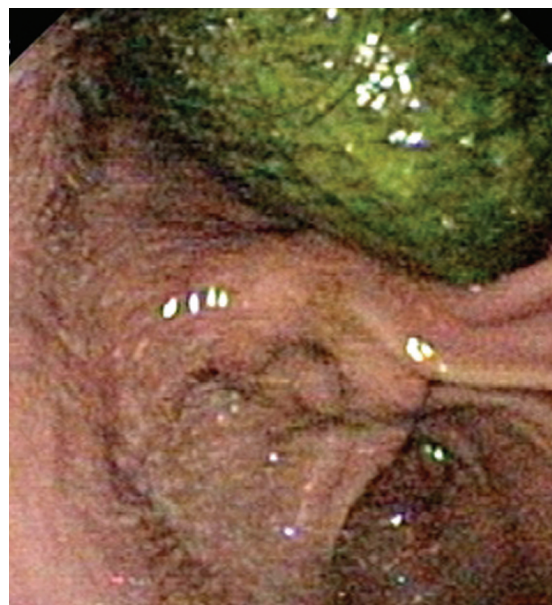A trichobezoar is a ball of swallowed hair that collects in the stomach and fails to pass through the intestines. The risk is greater among the mentally retarded or emotionally disturbed children. We report a 12-year-old girl who presented with features of intestinal obstruction. Endoscopy revealed a trichobezoar in the stomach. Diagnostic laparoscopy also revealed a trichobezoar in the ileum. After gastrotomy and enterotomy, the two trichobezoars were removed through a minilaparotomy. Psychiatric problems associated with these disorders will need attention or recurrence can occur. Trichobezoars may need surgical removal if endoscopy fails. Endoscopic removal may not be possible if the lesion is large and hard. There are some reports of laparoscopy being used in removal surgery. It has the advantages of smaller incisions, better cosmesis and reduced pain.

**Keywords:** bezoar, endoscopy, laparoscopy, minimal access surgery, trichobezoar

*Singapore Med J 2007; 48(2):e37–e39*

## INTRODUCTION

Chewing on or eating hair or any indigestible materials can lead to the formation of a bezoar. A bezoar is a ball of swallowed foreign material (usually hair or fibre) that collects in the stomach and fails to pass through the intestines. The risk is greater among the mentally retarded or emotionally disturbed children. Generally, bezoars are seen in female patients (approximately 90%) aged 10–19 years and only half of the patients have a history of trichophagia.<sup>(1)</sup> Trichobezoars can result in anaemia, abdominal pain, haematemesis, nausea and/or vomiting, bowel obstruction, gastric ulcers, perforation, gastrointestinal bleeding, acute pancreatitis, and obstructive jaundice. Contiguous extension of a trichobezoar into the small bowel can lead to the “Rapunzel syndrome”. The combination of a gastric hairball and a “hairtail” in the jejunum is known as the Rapunzel syndrome, first described in



**Fig. 1** Endoscopic photograph shows the trichobezoar in the stomach.

1968 by Vaughan et al.<sup>(2)</sup> Since then, 11 case reports have been described in the literature. Rapunzel was the long-haired maiden (described by the Grimm brothers in 1812) who had lowered her tresses to allow her “prince charming” to climb up to her prison tower to rescue her.

## CASE REPORT

A 12-year-old girl presented with vomiting of ten-day duration. There was no abdominal pain; only a bloated sensation and early satiety. Relative constipation was present. She was apathic, dehydrated and anaemic. A psychiatrist had seen her earlier to assess her mental status. Endoscopy was done and revealed a large ball of hair (Fig. 1). A diagnosis of trichobezoar was made and removal was attempted using a foreign body forceps, but the grasper could not hold the lesion due to its density and hardness. On retrospective questioning, the patient had a history of abnormal behaviour and hair ingestion. Abdominal radiograph showed evidence of subacute intestinal obstruction, though the exact level of obstruction was not clear. Diagnostic laparoscopy was planned, as the gastric outlet obstruction caused

Department of  
Minimal Access  
Surgery,  
GEM Hospital,  
45-A Pankaja  
Mill Road,  
Ramnathapuram,  
Coimbatore 641045,  
India

Palanivelu C, MCh,  
FRCS, FACS  
Director

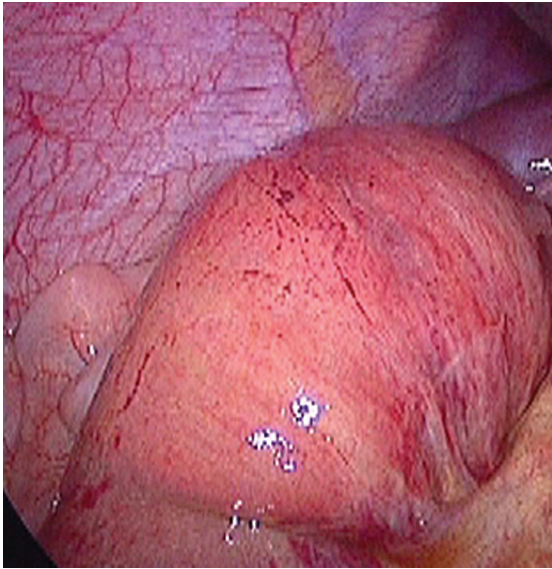
Department of  
Surgical  
Gastroenterology

Rangarajan M, MS,  
DipMIS  
Registrar

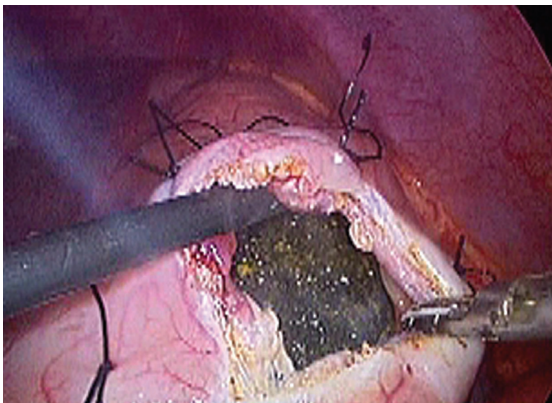
Senthilkumar R, MS  
Registrar

Madankumar MV, MS  
Registrar

**Correspondence to:**  
Dr Muthukumaran  
Rangarajan  
Tel: (91) 422 232 4105  
Fax: (91) 422 232 0879  
Email: rangy68@  
gmail.com



**Fig. 2** Photograph taken during laparoscopy shows the distended ileum containing another trichobezoar.



**Fig. 3** Photograph taken during laparoscopy shows the trichobezoar visible through the gastrotomy.

by the trichobezoar could not be responsible for the subacute intestinal obstructive features.

Laparoscopy revealed a mass in the pyloric area of the stomach. There were also a few dilated ileal and jejunal loops. Further inspection of the bowels unexpectedly showed another mass in the ileum (Fig. 2). Gastrotomy was done over the anterior surface of the stomach, directly over the mass, after placing stay sutures. The trichobezoar was visible through the opening (Fig. 3). A minilaparotomy incision was made on the skin directly over the opened stomach and an endobag was used to protect the wound. The trichobezoar was thus removed. The ileum containing the lesion was also brought out through the same incision; enterotomy was done and the trichobezoar was evacuated. The gastrotomy and

enterotomy wounds were closed with 20 vicryl in a single layer. The patient moved her bowels on the third postoperative day (POD) and was allowed liquids orally. The next day, soft diet was started and she passed stools. She was discharged on the fifth POD. She has been followed-up for two years to date, and had no further symptoms, though she was advised to consult her psychiatrist periodically.

## DISCUSSION

A bezoar is an aggregation within the gut of indigestible foreign matter, which has been repeatedly ingested over a period of time. The first authentic case of human trichobezoars was described in 1779. The bezoar most commonly encountered is the trichobezoar and is almost exclusively seen in young female patients, often associated with psychiatric problems. It is postulated that hair strands too slippery to be propelled are initially retained in altered mucosal crypts of the stomach and become enmeshed over a period of time. Trichobezoars are usually black from denaturation of protein by acid, glistening from retained mucus, and foul smelling from degradation of food residue trapped within it. The more severe manifestations are complete gastric outlet obstruction. Detached fragments of the bezoar may be detected as "satellite masses" within the small bowel and could lead to small bowel obstruction, similar to our case. Trichobezoars with small bowel extensions may produce other complications like bleeding, perforation, protein-losing enteropathies, steatorrhea, pancreatitis, appendicitis and intussusception.

Computed tomography (CT) best describes its size, configuration and location, and differentiates trichobezoars from neoplasms. The characteristic appearance of a trichobezoar on CT is a non-homogeneous, non-enhancing mass within the lumen of the stomach or bowel. Oral contrast agent circumscribes the mass and may fill the minute gaps on the surface of the lesion. The drawback is that sometimes, CT cannot differentiate small bowel faeces from trichobezoars.<sup>(3)</sup> A large trichobezoar has been traditionally removed by laparotomy, which has entailed an upper abdominal incision. With the advent of laparoscopic surgery, it became feasible to retrieve a foreign body from the stomach without the necessity for a laparotomy.<sup>(4)</sup> Since majority of the patients are young females, cosmesis becomes more important in this situation.

Endoscopic removal is usually not successful and results only in the retrieval of a small portion of the gastric trichobezoar.<sup>(5)</sup> However, Wai et al have reported that endoscopic retrieval is possible and open surgical or laparoscopic gastrotomy may be tried

only if this fails. Many endoscopical techniques have been described for breaking up the trichobezoar. These include use of instruments such as normal biopsy forceps, polypectomy snares, foreign body forceps, endoscopic injection with enzymes, water-jet spray and lithotripter.<sup>(6)</sup> In our patient, laparoscopy was indicated, as there was a trichobezoar in the ileum as well that could not be accessed or treated by endoscopy. Zamir et al reported a large series of patients between 1992 and 2002,<sup>(7)</sup> in which 18 patients had bezoars: 16 had phytobezoars and two had trichobezoars. 11 of the patients had previous gastric operations. All patients but one were treated surgically. Laparoscopy has been used in the diagnosis and therapy for trichobezoars. With the help of a laparoscope, Filipi et al first reported a case of percutaneous removal of a trichobezoar.<sup>(8)</sup> Endobags must be used to deliver the specimen, as there is risk of contamination. Laparoscopic approach may be the

treatment of choice for trichobezoar removal in the future, whenever surgery is indicated.

## REFERENCES

1. Yao CC, Wong HH, Chen CC, et al. Laparoscopic removal of large gastric phytobezoars. *Surg Laparosc Endosc Percutan Tech* 2000;10:243-5.
2. Sánchez MW, Rodríguez CDF, Luna-Pérez P. [Rapunzel's syndrome (trichobezoar)]. *Rev Gastroenterol Méx* 1997; 62: 284-6. Spanish.
3. Gayer G, Jonas T, Apter S, et al. Bezoars in the stomach and small bowel – CT appearance. *Clin Radiol* 1999; 54:228-32.
4. De Backer A, Van Nooten V, Vandenplas Y. Huge gastric trichobezoar in a 10-year-old girl: case report with emphasis on endoscopy in diagnosis and therapy. *J Pediatr Gastroenterol Nutr* 1999; 28:513-5.
5. Nirasawa Y, Mori T, Ito Y, et al. Laparoscopic removal of a large gastric trichobezoar. *J Pediatr Surg* 1998; 33:663-5.
6. Wai CT, Lau G, Sutedja DS. Clinics in diagnostic imaging (104). *Singapore Med J* 2005; 46:359-61.
7. Zamir D, Goldblum C, Linova L, et al. Phytobezoars and trichobezoars: a 10-year experience. *J Clin Gastroenterol* 2004; 38:873-6.
8. Filipi CJ, Perdakis G, Hinder RA, et al. An intraluminal surgical approach to the management of gastric bezoars. *Surg Endosc*. 1995; 9:831-3.