

Mobile cauda equina schwannomas

Marin-Sanabria E A, Sih I M, Tan K K, Tan J S H

ABSTRACT

Although very rare, cases of cauda equina tumours migrating several levels have been known to occur. We report two cases of cauda equina schwannomas which migrated from its primary site, one caudally and the other one rostrally as confirmed by magnetic resonance imaging perioperatively. The first patient was a 27-year-old man and the second a 41-year-old man; both presented with back pain. This report aims to remind clinicians that certain tumours attached to the roots in the lumbar spinal canal may migrate.

Keywords: cauda equina, mobile neurogenic tumour, schwannoma, spinal cord

Singapore Med J 2007; 48(2):e53–e56

INTRODUCTION

Few cases of mobile tumour of the spinal cord have been reported (Table I). It appears that the combination of the redundant nerve root,⁽¹⁾ postural changes⁽²⁾ and/or the thrust of the injected radiopaque material during myelography^(3,4) may cause shifting of cauda equina tumours in the spinal canal. Perioperative radiological imaging studies are useful to prevent excessive multilevel laminectomy and to minimise

surgical morbidities. We report two cases of mobile cauda equina schwannomas, in which the migration of tumours were documented by intraoperative magnetic resonance (MR) imaging.

CASE REPORTS

Case 1

A 27-year-old man presented with one year of back pain, radiating to the left buttock and big toe. There was decreased sensation over the left L1–L5 dermatomes, with no motor weakness. Lumbosacral MR imaging showed an intradural extramedullary tumour at L1 vertebral level, obliterating the subarachnoid space (Fig. 1). After L1 laminectomy and midline durotomy, the tumour could not be found in the spinal canal. The laminectomy was extended by undercutting T12 and L2 laminae. However, the tumour still could not be found. Intraoperative lumbosacral radiograph confirmed the correct level of the laminectomy. In view of the young age of the patient and in order to minimise the potential risk of instability, the dura and wound was closed in the standard manner. While still under anaesthesia and intubated, the patient was transferred to the MR imaging suite. Lumbosacral MR imaging revealed that the tumour was located at L2 vertebral level, one level inferior compared to the preoperative MR

Department of Neurosurgery, National Neuroscience Institute, 11 Jalan Tan Tock Seng, Singapore 308433

Marin-Sanabria EA, MD, PhD
Clinical Fellow

Tan KK, MBBS, FRCSE, FRCSG
Consultant

Tan JSH, MBBS, FRCS
Consultant

International Institute for Neurosciences, St Luke's Medical Center, Quezon City, Philippines

Sih I M, MD
Training Officer in Neurosurgery

Correspondence to:
Dr James Tan Siah Heng
Tel: (65) 6357 7191
Fax: (65) 6357 7137
Email: dr.james.tan@gmail.com

Table I. Summary of published cases of spinal mobile tumours.

Authors & year	No. of cases	Location	Migration	Discrepancy	Type of tumour
Wortzmann and Botterell, 1963	1	cauda equina	rostral	NA	ependymoma
Tomimatsu et al, 1974	1	cervical	caudal	2 vertebrae	schwannoma
Hollin et al, 1978	1	cauda equina	rostral	3 vertebrae	schwannoma
Husag et al, 1980	1	cauda equina	caudal	7 cm	schwannoma
Pau et al, 1982	1	cauda equina	caudal	2 vertebrae	schwannoma
Tavy et al, 1987	1	cauda equina	caudal	3 vertebrae	schwannoma
Murai et al, 1991	1	thoraco-lumbar	caudal	8 vertebrae	neurenteric cyst
Satoh et al, 1991	1	thoraco-lumbar	rostral	1 vertebra	schwannoma
Namura et al, 1993	1	thoracic	caudal	3 vertebrae	schwannoma
Iizuka et al, 1998	1	cervicothoracic	caudal	1 vertebra	schwannoma
Friedman et al, 2000	1	cauda equina	rostral	1 vertebra	schwannoma
Friedman et al, 2003	3	cauda equina	rostral	½ vertebra	schwannoma
		cauda equina	rostral	½ vertebra	schwannoma
		cauda equina	rostral	1 vertebra	schwannoma
Present report, 2007	2	cauda equina	rostral	2.2 cm	schwannoma
		cauda equina	caudal	2 vertebrae	schwannoma

NA = not available.

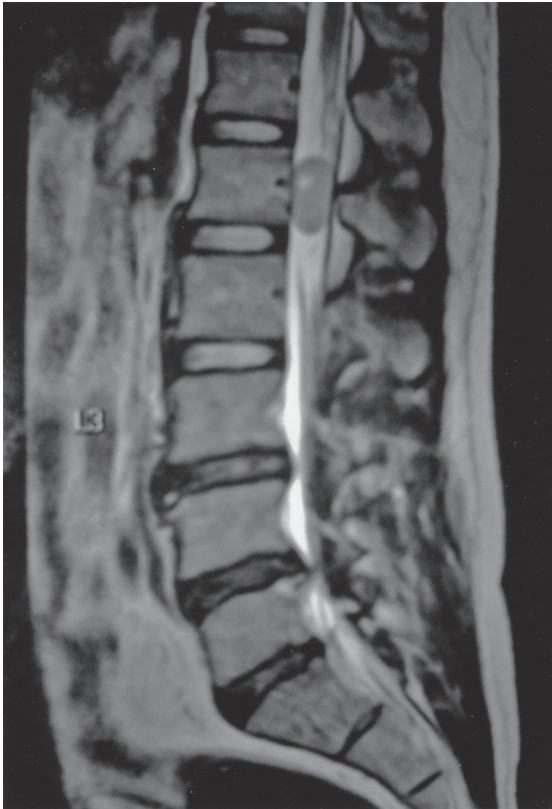

Fig. 1 Preoperative sagittal T2-weighted lumbosacral MR imaging shows tumour at L1 vertebral level.

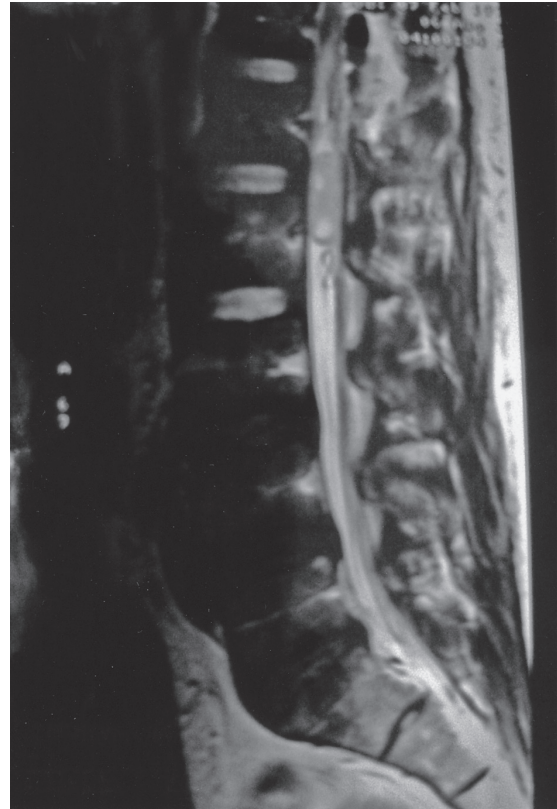


Fig. 2 Intraoperative sagittal T2-weighted lumbosacral MR imaging shows tumour has moved caudally by 2.2 cm at L1/2 interspace.

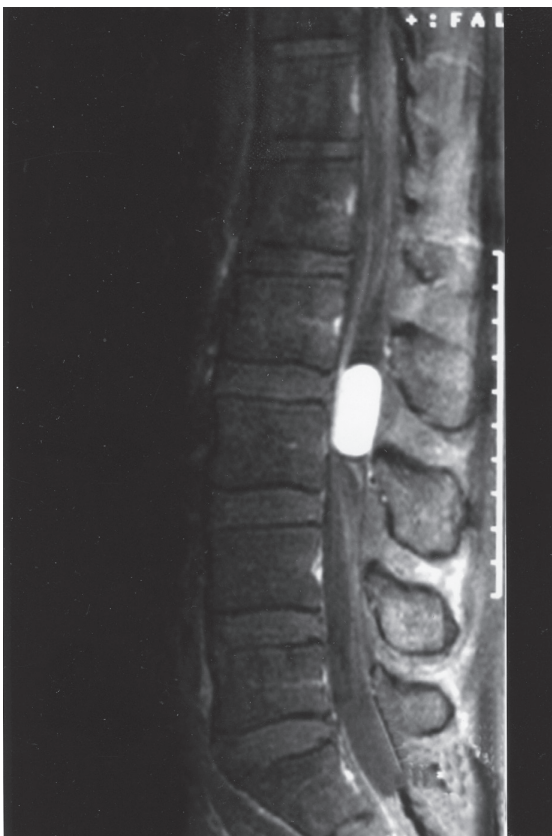

Fig. 3 Preoperative contrast-enhanced T1-weighted lumbosacral MR imaging shows tumour at L2/3 interspace.

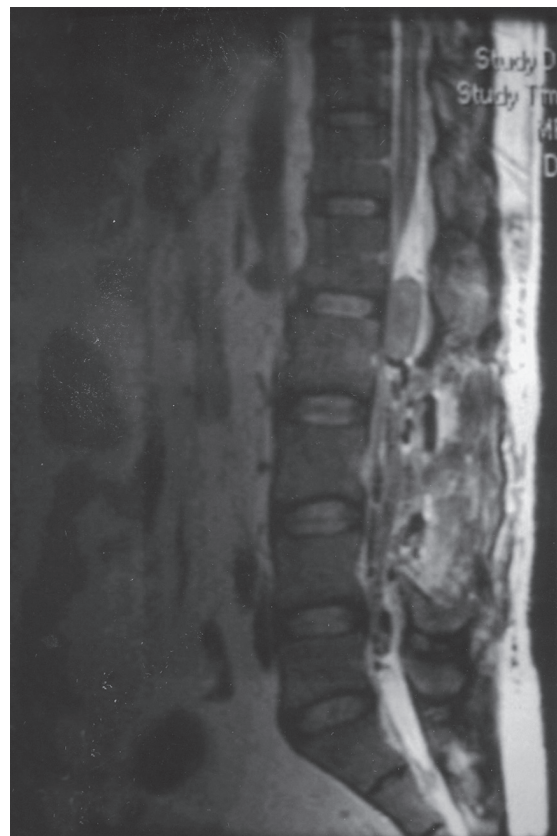


Fig. 4 Intraoperative sagittal T2-weighted lumbosacral MR imaging shows tumour has moved cranially to L1/2 interspace.

imaging. The tumour had migrated 2.2 cm caudally (Fig. 2). The patient was brought back to the operating theatre and the inferior half of the incision was re-opened and extended by 4 cm. L2 laminectomy was done, followed by a midline durotomy. The tumour, measuring 3 cm × 1 cm × 1 cm, was identified and excised from its nerve root origin. The proximal and distal nerve root attachments were cauterised and cut. Postoperatively, the patient's condition was unremarkable and histopathology confirmed a cellular schwannoma.

Case 2

A 41-year-old man presented with one year of progressive back pain with bilateral lower limb radiation and without clinical deficits. Lumbar spine MR imaging showed a 1.5 cm × 2.7 cm × 1.3 cm well-defined enhancing intradural, extramedullary lesion at L2–L3 vertebral level (Fig. 3). Intraoperatively, a L2–L3 laminectomy was performed but the tumour was not found on opening the dura. The surgical exploration was extended caudally and additional L4 laminectomy and durotomy were done. The tumour was still not found. The wound was closed in the standard fashion and the patient was sent to the MR imaging suite. As MR imaging revealed that the tumour had migrated rostrally to L1–L2 vertebral level (Fig. 4); he was returned to the operation theatre. The incision was extended and explored cephalically. The tumour was found and excised. Postoperatively, the patient remained well. Histopathologic examination of the excised tumour confirmed a schwannoma.

DISCUSSION

In 1963, Wortzman and Botterell described the first case of mobile tumour at the cauda equina. It was an ependymoma of the filum terminale and this mobility was attributed to the unusual laxity of the filum terminale.⁽⁵⁾ The present report deals with an unusual discrepancy between the preoperative MR imaging localisation of two cases of intraspinal schwannomas and the surgical findings. It is difficult to explain the discrepancy of tumour location between the preoperative studies and intraoperative findings.

A possible mechanism of tumour mobility is the elongation of the nerve root by tension resulting from the tumour weight. As mentioned by some authors, a redundant root would allow mobility of an attached tumour.^(1,6) Normally, the nerve roots have considerable slack when the lumbar spine and hips are in extension.⁽⁷⁾ Other authors include as possible mechanisms, the dilatation of the subarachnoid space attributable to spinal cord

deformity induced by the extramedullary tumour.⁽⁸⁾ Changes in clinical signs depending upon the changes of patient's posture^(9,10) or straining, sneezing, coughing or muscular relaxation after anaesthesia⁽¹¹⁻¹³⁾ have been reported. Indeed, immediately before anaesthesia, we had noted that the patient in Case 2 had strained significantly at micturition, perhaps the Valsalva manoeuvre could be postulated to cause the migration of the tumour.

Some authors blamed the injection of radiopaque substance during myelography as one of the causes of tumour displacement.^(3,4) At present, MR imaging has replaced myelography as an initial diagnostic procedure of choice for localising a mass in the spinal canal. In our two cases, as well as others reported in the medical literature,^(8,9) the discrepancy in the level of the lesion between preoperative MR imaging and surgical finding cannot be explained based on the injection of contrast material since during MR imaging, there is no intrathecal injection of contrast material. Perioperative imaging techniques have been employed^(1,14) to facilitate localisation of the tumour and reduce the extent of laminectomies, which may contribute to possible surgical morbidities. As these tumours can migrate in any direction, the use of an intraoperative study may prove vital and avoid excessive and unnecessary laminectomy to achieve adequate tumour visualisation and excision.

Intraoperative ultrasonography was mentioned by some authors⁽¹⁴⁾ as a valuable technique in localisation of tumours of the cauda equina, although bony removal will still be necessary. It may be useful as an intraoperative investigation in order to confirm the precise tumour location; however, it should be remembered that the lesion could migrate during the laminectomy procedure,⁽¹⁵⁾ probably due to the positive pressure ventilation and the position of the patient. Whatever the cause of the displacement, spinal tumours as schwannoma, ependymoma and neurenteric cyst may have considerable mobility and we want to remind surgeons of the importance of accurate localisation of the spinal tumour in order to minimise the extent of soft tissue dissection and bony destruction during surgery.

REFERENCES

- Hollin SA, Drapkin AJ, Wancier J, Huang YP. Mobile schwannoma of the cauda equina. Case report. *J Neurosurg* 1978; 48:135-7.
- Friedman JA, Atkinson JL, Lane JI. Migration of an intraspinal schwannoma documented by intraoperative ultrasound: case report. *Surg Neurol* 2000; 54:455-7.
- Caracalos A. Elusive cauda equina tumor. *J Neurosurg* 1987; 67:952.
- Tavy DL, Kuiters RR, Koster PA, Hekster RE. Elusive tumor of the cauda equina. Case report. *J Neurosurg*. 1987; 66:131-3.
- Wortzman G, Botterell EH. A mobile ependymoma of the filum terminale. *J Neurosurg*. 1963; 20:164-6.

6. Pau A, Orunesu G, Sehrbunt Viale E, Turtas S, Zirattu G. Mobile neurinoma of the cauda equina. Case report. *Acta Neurochir (Wien)*. 1982; 60:115-7.
7. Ehni G, Moiel RH, Bragg TG. The "redundant" or "knotted" nerve root: a clue to spondylotic cauda equina radiculopathy. Case report. *J Neurosurg* 1970; 32:252-4.
8. Iizuka H, Iida T, Akai T. Mobile neurinoma of the cervicothoracic junction. *Surg Neurol* 1998; 50:492-3.
9. Isu T, Iwasaki Y, Akino M, Nagashima M, Abe H. Mobile schwannoma of the cauda equina diagnosed by magnetic resonance imaging. *Neurosurgery* 1989; 25:968-71.
10. Tomimatsu T, Yamamura I, Kawaguchi N, et al. [A mobile tumor of the cervical spinal cord. A case report] *Kantoh Seisaisi* 1974; 5:213-8. Japanese.
11. Husag L, Schubiger O, Probst C. [Neurinoma of the cauda equine] *Schweiz Arch Neurol Neurochir Psychiatr* 1980; 127:205-11. German.
12. Murai H, Arai M, Satoh K, et al. [Mobile spinal neurenteric cyst] A case report. *Seikei Geka* 1991; 42:1746-9. Japanese.
13. Satoh T, Kageyama T, Kamata I, Date I. [Mobile neurinoma of the cauda equina; a case report] *No Shinkei Geka* 1991; 19:891-6. Japanese.
14. Friedman JA, Wetjen NM, Atkinson JL. Utility of intraoperative ultrasound for tumors of the cauda equina. *Spine* 2003; 28:288-90.
15. Namura S, Hanakita J, Suwa H, et al. Thoracic mobile neurinoma. Case report. *J Neurosurg* 1993; 79:277-9.