

# Pure choriocarcinoma of testis with rare gingival and skin metastases

Bhatia K, Vaid A K, Rawal S, Patole K D

## ABSTRACT

**A 22-year-old man presented with complaints of gingival and skin lesions. Physical examination revealed the presence of two nodular lesions, one over the sternum, 3 cm in size, and another, on the right side of chin, 1 cm in size. There was another fleshy soft tissue deposit over the left lower gingiva, in the oral cavity. He had noticed these lesions ten days prior to his visit to the hospital. In addition, there was left testicular non-tender swelling which had been present for two months, but was not investigated. Fine-needle aspiration cytology from skin and gingival lesions was suggestive of metastatic deposits. Patient underwent left high orchidectomy, and histopathological examination was consistent with the diagnosis of pure choriocarcinoma. Although rare, cases of testicular neoplasms and especially choriocarcinoma of the testis leading to skin metastases have been reported, but case reports of choriocarcinoma of testis metastatic to gingiva have been reported exceptionally in the English literature. We report this unique case of a young man with pure choriocarcinoma of testis with unusual gingival and skin metastases.**

**Keywords: choriocarcinoma, gingival metastases, gingiva, skin metastases, testicular choriocarcinoma, testicular tumour**

*Singapore Med J 2007;48(3):e77–e80*

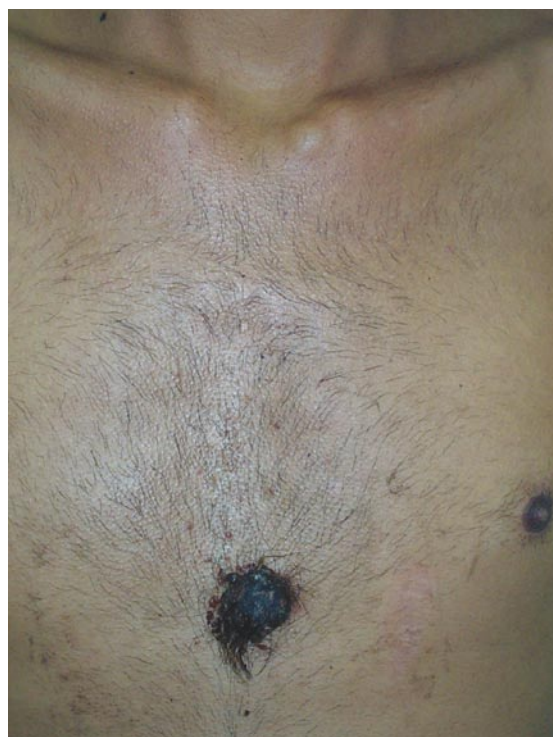## INTRODUCTION

Although every malignancy can lead to skin metastasis, its incidence of occurrence is as low as 0.7%–9%.<sup>(1,2)</sup> Rarely, skin metastasis represents the first evidence of malignancy and are usually seen as a late event in advanced cancer.<sup>(1,2)</sup> Pure testicular choriocarcinoma is a rare germ cell neoplasm, accounting for less than 3% of all the testicular neoplasms.<sup>(3)</sup> It usually metastasises to the lungs, liver and brain.<sup>(3)</sup> The most common primary sites of metastasis to the oral region are the breast, lung, kidney, bone and colon.<sup>(4)</sup> Similar to skin

metastases, oral metastatic tumours are also uncommon and comprise only approximately 1% of the malignant oral neoplasms.<sup>(4)</sup>

## CASE REPORT

A 22-year-old man with no known significant comorbidities, was referred by a dermatologist, with chief complaints of nodular skin swellings over the sternal region (Fig. 1) and over the left chin area of ten days, duration, and which were adherent to the underlying structures. Another swelling over the left lower gingiva was also present. Fine-needle aspiration cytology (FNAC) was done from the sternal lesion by the dermatologist, who was suspicious of malignancy. Clinical examination revealed a dark-pigmented, non-tender, nodular swelling, 3 cm in size, over the sternal region, and another on the chin that was 1 cm in size, and another fleshy non-pigmented soft tissue swelling over the left lower gingiva.



**Fig. 1** Photograph shows a fleshy hyperpigmented nodular lesion measuring 3.5 cm over the sternal region.

Department of  
Medical Oncology,  
Rajiv Gandhi  
Cancer Institute and  
Research Centre,  
Rohini Sector 5,  
Delhi 110085,  
India

Bhatia K, MBBS  
Resident

Vaid AK, MBBS,  
MD, DM  
Senior Consultant

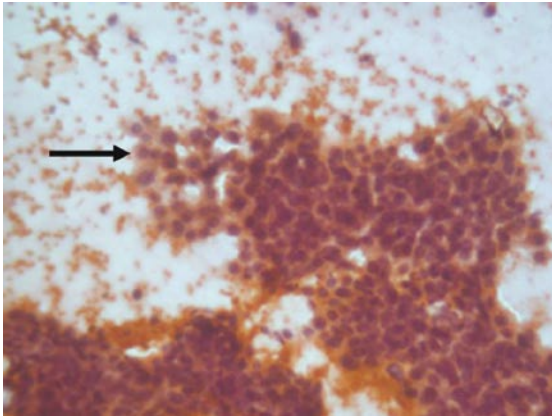
Department of  
Surgical Oncology

Rawal S, MBBS,  
MS, MCH,  
Senior Consultant

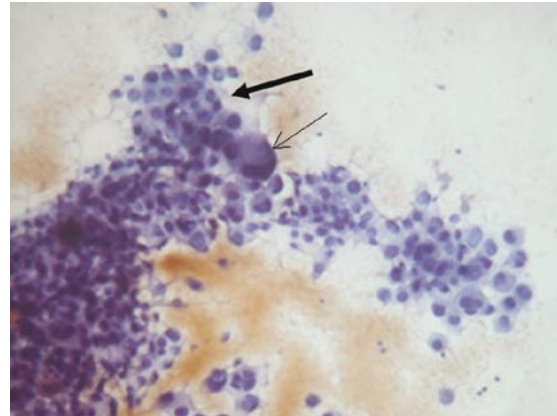
Department of  
Pathology

Patole KD,  
MBBS, MD  
Senior Consultant

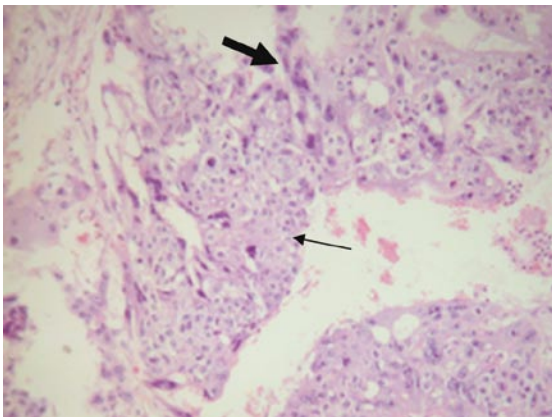
**Correspondence to:**  
Dr Ashok K Vaid  
Tel: (91) 11 2705 1011  
30  
Fax: (91) 11 2793 1342  
Email: akvaid@  
rgci.org



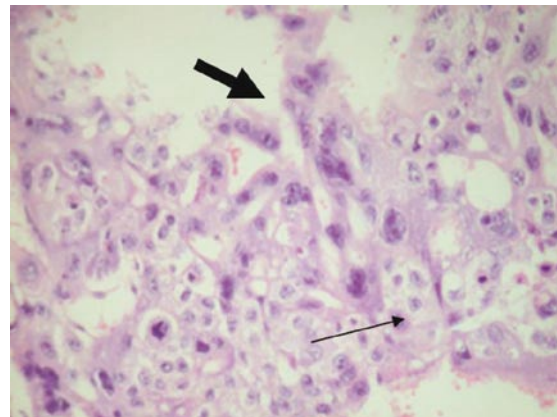
**Fig. 2** FNAC of the skin lesions shows cells with a variable amount of cytoplasm (Pap stain, ×40).



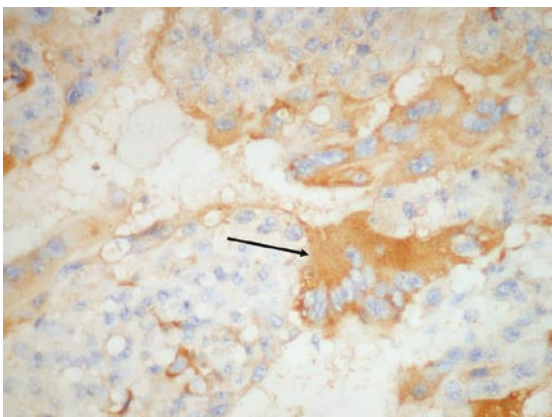
**Fig. 3** FNAC of the skin lesions shows cells with large cytoplasm, pleomorphic nuclei along with multinucleated tumour giant cells (Pap stain, ×40).



**Fig. 4** Photomicrograph of the high orchidectomy specimen shows choriocarcinoma with syncytiotrophoblasts (bold arrow) and cytotrophoblasts (thin arrow) (Haematoxylin & eosin, ×40).



**Fig. 5** Photomicrograph of the high orchidectomy specimen shows choriocarcinoma with syncytiotrophoblasts (bold arrow) and cytotrophoblasts (thin arrow) (Haematoxylin & eosin, ×100).



**Fig. 6** IHC shows immunostaining with beta-HCG of syncytiotrophoblasts (Clone 2B1.3, Isotype IgG2a, ×40).

On further questioning, he revealed the presence of a painless left testicular enlargement, which had been present for the past two months. FNAC from all the

skin nodules (Figs. 2 & 3) was done, due to non-availability of the outside FNAC slides for our review. Histopathological examination was consistent with the diagnosis of metastatic germ cell tumour. Serum beta-human chorionic gonadotrophin (HCG) level was 468 IU/ml (normal range, 0–25 IU/ml). Serum alpha-foetal protein was 0.426 IU/ml (normal < 7.2 IU/ml). Serum lactate dehydrogenase was 438 U/L (normal range, 225–450 U/L). Computed tomography of the chest showed multiple nodular lesions in both lungs, the largest being 2.3 cm × 1.6 cm and 1.9 cm × 1.5 cm in the left and right lungs, respectively. Haematological and biochemical parameters were unremarkable.

He underwent left high orchidectomy and histopathological examination showed choriocarcinoma of the left testis (Figs. 4 & 5). Immunohistochemistry (IHC) was done after discussion with our tumour board, and the result was consistent with the diagnosis of

pure choriocarcinoma (Fig. 6). He was started on chemotherapy with the Bleomycin, Etoposide and Cisplatin (BEP)-based protocol. After completion of three cycles of chemotherapy, his skin and gingival nodules regressed completely. There was decline in the level of serum beta-HCG after all the three cycles (468200/180/160 IU/ml). Although the decline in the levels of beta-HCG was not appropriate, he was continued on the chemotherapy with the BEP protocol in view of good clinical response, as indicated by regression of the skin as well as the gingival lesions.

There was no evidence of clinical relapse after completion of four cycles of chemotherapy. However, after the fourth cycle of chemotherapy, serum HCG level rose to 1,000 IU/ml. In view of the rising beta-HCG, he was planned for brain imaging, with the suspicion of possible central nervous system involvement, although he had no neurological signs and symptoms. He was also planned for salvage chemotherapy in view of rising beta-HCG levels. After the fourth cycle of chemotherapy, the patient was counselled regarding the brain imaging and change of chemotherapy plan. But he moved to another centre for treatment and hence, was lost to follow-up.

## DISCUSSION

Choriocarcinoma is a malignant growth of trophoblastic cells, which is characterised by the secretion of HCGs.<sup>(5)</sup> It usually arises as gestational choriocarcinoma, from foetal trophoblasts of a previous hydatidiform mole pregnancy. Rarely, it arises from germ cells in the testis or ovary. Choriocarcinoma is conventionally classified as pure choriocarcinoma, which is composed of only syncytiotrophoblastic and cytotrophoblastic components, and mixed germ cell tumour, which contains choriocarcinoma as one of the components. In males, it usually occurs as a component of testicular mixed germ cell tumours, whereas its pure form represents less than 3% of all the cases.<sup>(3)</sup> Non-seminomatous germ cell tumours of the testis usually metastasise to the retroperitoneal lymph nodes, lung, liver and brain, but metastases to skin and oral mucosa are very rare.<sup>(6,7)</sup>

The skin is an uncommon site of metastatic disease.<sup>(8)</sup> The overall incidence of metastasis to the skin is only 0.7%–9%.<sup>(1)</sup> The most frequently observed primary sites leading to skin metastases are the breast, colon and melanoma in women, and the lung, colon and melanoma in men.<sup>(1)</sup> With both the genders combined, colorectal carcinoma is the most common visceral malignancy leading to skin metastasis.<sup>(9)</sup>

The anterior chest wall is the most common site for metastatic skin lesions, followed by the face and the lower extremities.<sup>(9,10)</sup> Approximately, 3%–15% of the patients with skin metastasis have multiple metastatic sites.<sup>(6,7)</sup> In general, metastatic carcinoma of skin is considered a poor prognostic sign.<sup>(11)</sup>

Similarly, oral metastatic tumours are also uncommon and comprise only 1% of the malignant oral lesions. The most common primary sources of metastases to the oral region are the breast, lung, kidney, bone and colon. The breast and lungs are the most common primary sites for metastasis to the jawbones and oral soft tissue, respectively. Also, the most common source of metastases to the oral cavity is the breast in women, and lungs in men. Renal cell carcinoma is another common tumour that metastasise to the oral mucosa.<sup>(12)</sup> In the oral soft tissue, the attached gingiva is the most common site of metastasis, followed by the tongue.<sup>(4)</sup> The early manifestations of the gingival metastases may resemble hyperplastic or reactive lesions, such as pyogenic granuloma, peripheral giant cell granuloma, or fibrous epulis.<sup>(4,12,13)</sup>

Hirshberg et al analysed 157 cases of well-documented metastatic lesions to the oral cavity. According to their analysis, the most common oral site of involvement was the gingiva, followed by the tongue, tonsil, palate, lip, buccal mucosa and floor of mouth, in that order.<sup>(12)</sup> Gingival lesions were almost equally distributed between the maxilla and mandible.<sup>(12)</sup> In dentulous patients, 79% exhibited metastases to the attached gingiva, whereas in edentulous patients metastatic lesions were equally distributed between the tongue and the alveolar mucosa.<sup>(12)</sup>

This case is unique in being pure choriocarcinoma of testis, which accounts for less than 3% of the testicular neoplasms with rare skin, and even rarer, oral soft tissue metastases. This also emphasises that metastases to these sites should be investigated for the presence of testicular malignancy in men. Thus, suspicious gingival and skin lesions should be investigated thoroughly by the dentist and dermatologist, respectively, for the presence of an underlying malignancy. Also, the levels of beta-HCG may provide an important clue to the response of the patient. As in our case, the decline in levels of beta-HCG was not appropriate, although clinical response of the patient was encouraging. Apart from refractory disease which can lead to raised levels of beta-HCG, an occult central nervous system should be kept in mind and brain imaging should be done promptly.

**REFERENCES**

1. Spencer PS, Helm TN. Skin metastases in cancer patients. *Cutis* 1987; 39:119-21.
2. Schwartz RA. Cutaneous metastatic disease. *J Am Acad Dermatol* 1995; 33:161-82. Comment in: *J Am Acad Dermatol* 1996; 34:1093.
3. Shimizu S, Nagata Y, Han-yaku H. Metastatic testicular choriocarcinoma of the skin. Report and review of the literature. *Am J Dermatopathol* 1996; 18:633-6.
4. Hirshberg A, Buchner A. Metastatic tumors to the oral region. An overview. *Eur J Cancer B Oral Oncol* 1995; 31B:355-60.
5. Robey EL, Schellhammer PF. Four cases of metastases to the penis and a review of the literature. *J Urol* 1984; 132:992-4.
6. Gates O. Cutaneous metastasis of malignant disease. *Am J Cancer* 1937; 30:219-28.
7. Brownstein MH, Helwig EB. Metastatic tumors of the skin. *Cancer* 1972; 29:1298-307.
8. Chhieng DC, Jennings TA, Slominski A, Mihm MC Jr. Choriocarcinoma presenting as a cutaneous metastasis. *J Cutan Pathol* 1995; 22:374-7.
9. Brownstein MH, Helwig EB. Patterns of cutaneous metastasis. *Arch Dermatol* 1972; 105:862-8.
10. Tharakaram S. Metastases to the skin. *Int J Dermatol* 1988; 27:240-2.
11. Reingold IM. Cutaneous metastases from internal carcinoma. *Cancer* 1966; 19:162-8.
12. Hirshberg A, Leibovich P, Buchner A. Metastases to the oral mucosa: analysis of 157 cases. *J Oral Pathol Med* 1993; 22:385-90.
13. Rim JH, Moon SE, Chang MS, Kim JA. Metastatic hepatocellular carcinoma of gingiva mimicking pyogenic granuloma. *J Am Acad Dermatol* 2003; 49:342-3.