

CME Article

Clinics in diagnostic imaging (II4)

Muttarak M, Thinyu S, Lojanapiwat B

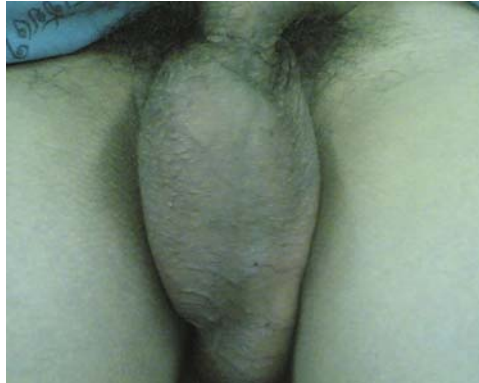

Fig. 1 Clinical photograph of the scrotum.

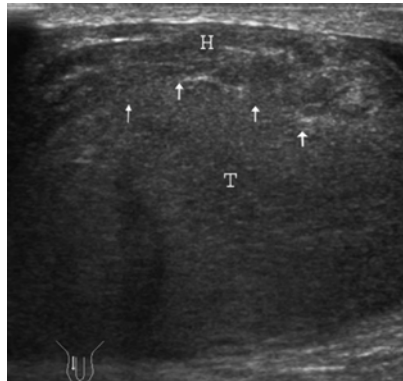


Fig. 2a Longitudinal US image of the right hemiscrotum.

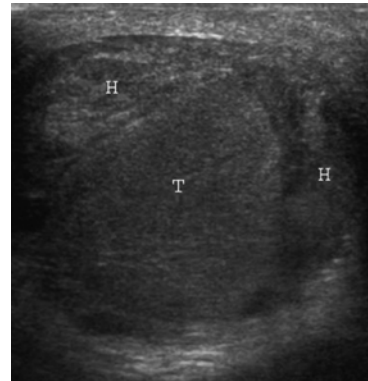

Fig. 2b Transverse US image of the right hemiscrotum.

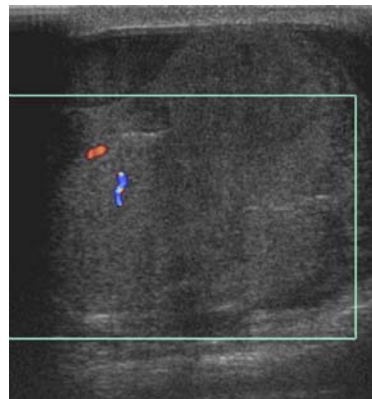


Fig. 2c Colour Doppler US image of the right hemiscrotum.

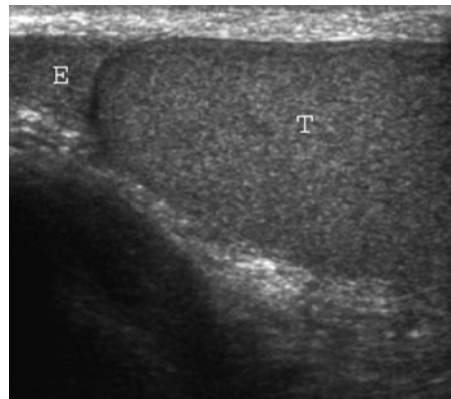


Fig. 2d Longitudinal US image of the left hemiscrotum.

CASE PRESENTATION

A 22-year-old Thai kickboxer presented with a painful swelling of his right hemiscrotum for two hours after he was kicked in the scrotum during a fight. He had no past medical history. Physical examination revealed a young healthy man with swelling of the right hemiscrotum (Fig. 1) and marked

tenderness of the right testis. The left testis and epididymis appeared normal. His blood pressure was 140/70 mmHg, and body temperature was 37°C. Complete blood count and urinalysis were normal. Scrotal ultrasonography (US) was performed (Figs. 2a–d). What do these images show? What is the diagnosis?

Department of Radiology, Chiang Mai University, Chiang Mai 50200, Thailand

Muttarak M, MD Professor

Thinyu S, MD Resident

Department of Surgery

Lojanapiwat B, MD Professor

Correspondence to: Prof Malai Muttarak
Tel: (66) 53 945450
Fax: (66) 53 946136
Email: mmuttara@mail.med.cmu.ac.th

IMAGE INTERPRETATION

The clinical photograph (Fig. 1) showed swelling of the right hemiscrotum with stretching of the scrotal skin but no ecchymosis. Longitudinal and transverse scrotal US images (Figs. 2a–b) showed an enlarged right testis (T) with heterogeneous echoes, indistinct margins (arrows), and a hyperechoic haematocoele (H). The scrotal skin was not thickened. Colour Doppler US (CDUS) (Fig. 2c) showed normal vascularity in the upper pole of the right testis but no vascularity in the lower pole. The left epididymis (E) and testis (T) (Fig. 2d) were of normal size, and had homogeneous echo with smooth well-defined margins.

DIAGNOSIS

Rupture of the right testis.

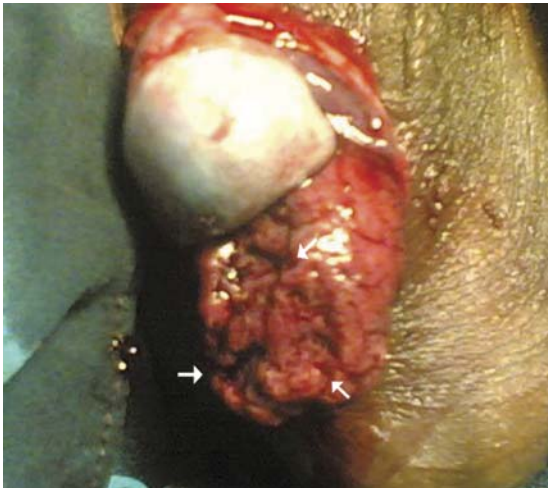


Fig. 3 Operative photograph shows disruption of the tunica albuginea with laceration of the lower pole of the right testis (arrows).

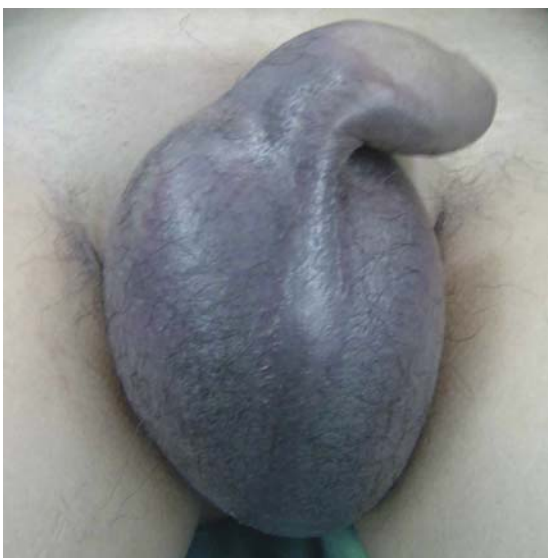

Fig. 4 Clinical photograph shows a markedly-enlarged scrotum with ecchymosis.

CLINICAL COURSE

The patient underwent emergency exploration of the right scrotum which showed disruption of the tunica albuginea and laceration of the lower pole of the right testis (Fig. 3). There was minimal haematocoele. Debridement and repair of the right testis were performed. He made a good postoperative recovery and was discharged one day after operation.

DISCUSSION

Testicular trauma is uncommon and typically results from motorcycle accident, sport injury, direct perineal trauma with compression of scrotum against the pubic bone, and straddle injury. Patients suffering testicular trauma usually have severe testicular pain, with varying degrees of scrotal swelling and ecchymosis. As optimal physical examination is limited by scrotal pain and swelling, it is difficult to differentiate an uncomplicated haematocoele from a testicular rupture.⁽¹⁾ In the presented case, the scrotum was mildly swollen but there was testicular rupture. In other cases, the scrotum may be markedly swollen (Fig. 4) but there was only scrotal haematoma. Prompt diagnosis of testicular rupture is important because more than 80% of ruptured testes can be saved if surgery is performed within the first 72 hours after injury.

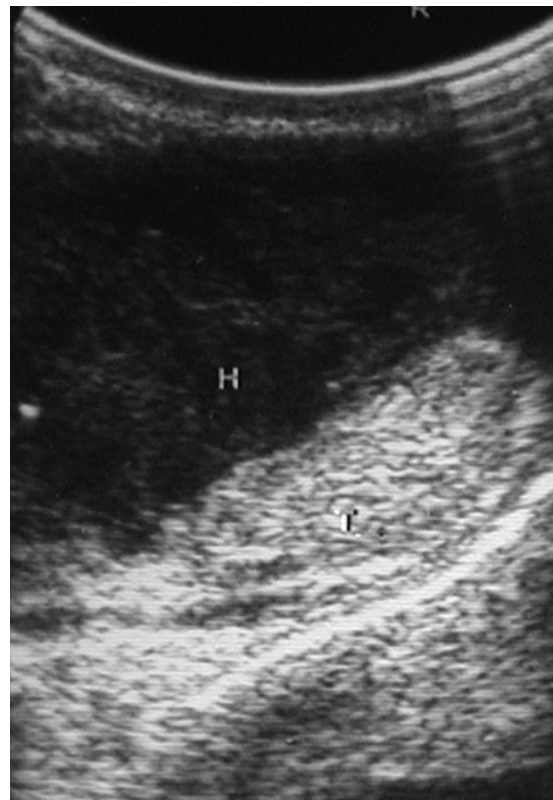


Fig. 5 A 59-year-old man who was kicked in the scrotum one week ago. Longitudinal US image shows a large complex echoic haematocoele (H) and compression of the testis (T).

If testicular injury is left untreated, complications such as ischaemic atrophy, prolonged patient discomfort, and infection may occur.⁽¹⁻⁶⁾

US has an important role in the initial evaluation of patients with scrotal injury. It is noninvasive, can be rapidly performed, and is accurate for determining whether there is solely haematocoele, intratesticular haematoma, testicular contusion, or associated testicular rupture.⁽¹⁻⁶⁾ CDUS should also be performed in all cases of scrotal injury to evaluate the vascular supply of the testis. Haematocoele is common after scrotal trauma but it is nonspecific for testicular rupture as it may be caused by intra- or extratesticular bleeding.^(2,7) Therefore, the presence of haematocoele alone is not indicative of testicular rupture. At US, haematocoele may appear different depending on time following injury. Acute haematocoele is hyperechoic (Fig. 2b) whereas a chronic

haematocoele is hypoechoic, with fluid-fluid levels or septations⁽⁵⁾ (Fig. 5).

Haematoma may occur at the testis, epididymis, or scrotal wall. Scrotal haematoma refers to an accumulation of blood within the soft tissue of the scrotal wall. If it is large, it can displace the testis from the US field-of-view. Hence, if a thorough examination is not performed, a false positive diagnosis of rupture may occur. Although scrotal US is usually performed using a high-frequency transducer, a lower frequency transducer may be used to survey the scrotum for a displaced or compressed testis (Fig. 6). If an intact testis can be identified and vascular status of the testis can be accurately evaluated with CDUS, surgical exploration may be avoided. However, evacuation of a large haematoma will expedite healing. US features of an intratesticular haematoma is also time dependent. In the acute phase, a haematoma appears as

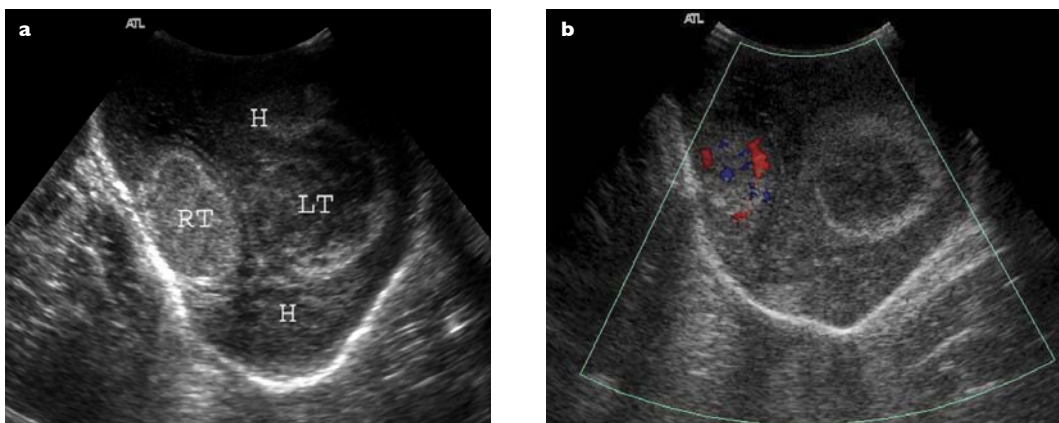


Fig. 6 A 19-year-old man who was struck in the scrotum. (a) Transverse US image of the scrotum using a 3.5 MHz transducer shows large haematocoeles (H) in the scrotum, a homogeneously-echoic right testis (RT), and a heterogeneously-echoic left testis (LT) with indistinct margins. (b) Colour Doppler US image shows vascularity in the right testis but avascularity in the left testis. Surgical exploration revealed rupture of the left testis and a normal right testis.

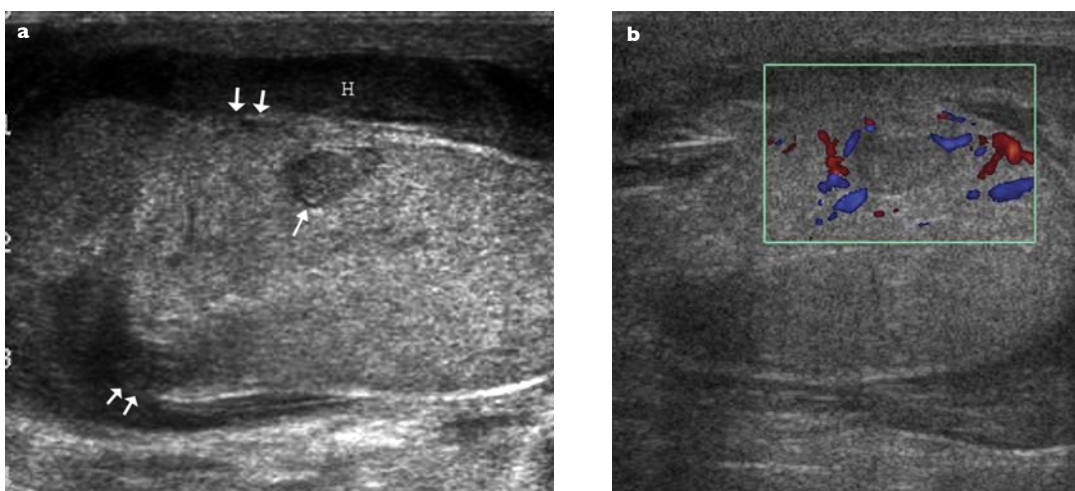


Fig. 7 A 22-year-old man who sustained a direct hit from a ball. (a) Longitudinal US image shows an acute hyperechoic intratesticular haematoma (single arrow). Hyperechoic haematocoele (H) and indistinct testicular contour (double arrows) are also demonstrated. (b) Colour Doppler US image shows no vascularity in the haematoma.

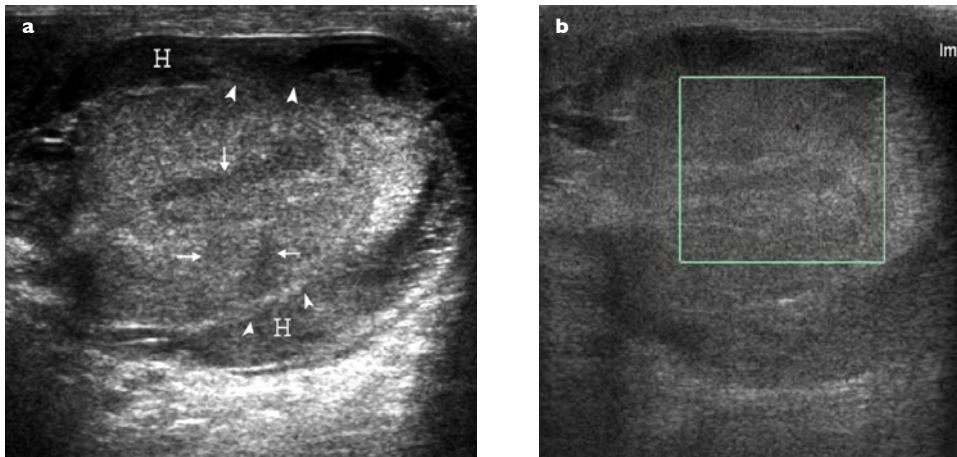


Fig. 8 A 22-year-old man who had blunt trauma in the scrotum. (a) Longitudinal US image shows an indistinct testicular contour (arrowheads), multiple discrete fracture lines (arrows), and echogenic haematocoele (H). (b) Colour Doppler US image shows no vascularity in the testis.

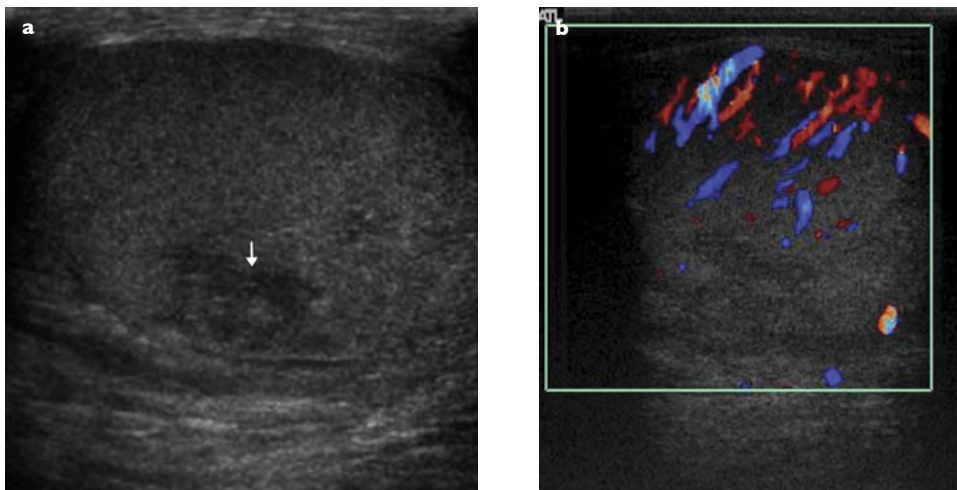


Fig. 9 A 20-year-old man who had a motorcycle accident. (a) Longitudinal US image shows an intratesticular haematoma (arrow) with smooth testicular contour. (b) Colour Doppler US image shows normal vascularity of the testis but an avascular haematoma.

a heterogeneous echogenic mass (Fig. 7a). With time, it becomes complex with cystic components. An intratesticular haematoma may mimic tumour, abscess, and infarct.⁽⁵⁻⁸⁾ Haematomas are avascular on CDUS (Fig. 7b). Another caveat is that 10%–15% of patients with testicular tumour first seek medical attention following an episode of trauma.⁽⁹⁾ Testicular tumours appear hypervascular on CDUS if the diameter is greater than 1.6 cm.⁽¹⁰⁾ Testicular abscess is typically hypervascular in the periphery of the lesion, with avascularity inside the lesion.⁽⁴⁾

The most sensitive sign of testicular rupture is irregular or indistinct testicular contour (Figs. 2a, 5, 7a, & 8a), indicating an interruption of the tunica albuginea.⁽¹¹⁾ A discrete fracture line is rare, and is seen in only 17% of cases.⁽¹⁾ Recent advances in US technology, presence of this fracture line, and multifocal disruption of the normally homogeneous-testicular parenchymal echo pattern are

more often seen (Figs. 5 & 8a). Additional use of CDUS helps evaluate the degree of vitality of the residual parenchyma (Fig. 8b) and hence guides correct surgical management. The presence of intratesticular haematoma alone is also not indicative of testicular rupture unless there is disruption of the testicular margin⁽⁶⁾ (Fig. 9).

In conclusion, US should be performed in cases of scrotal trauma because of the limitation of a physical examination in determining the severity of trauma. Surgical treatment of testicular rupture within 72 hours can save the testis in more than 80% of cases. On the other hand, if less severe abnormalities are present, surgery can be avoided.

ABSTRACT

A 22-year-old man, who was kicked in the scrotum during Thai kickboxing,

presented with a painful swelling of the right hemiscrotum. Scrotal ultrasonography (US) showed an enlarged right testis with heterogeneous echogenicity and irregular contours. Colour Doppler US showed vascularity in the upper pole of the right testis and avascularity in the lower pole. Emergency exploration of the right hemiscrotum revealed laceration of the lower pole of the right testis. Debridement and repair of the right testis were performed. The clinical manifestations, role of US and US findings of scrotal trauma are discussed.

Keywords: colour Doppler ultrasonography, scrotal trauma, scrotum, testicular rupture, testis

Singapore Med J 2007; 48(3):264–269

REFERENCES

1. Jeffrey RB, Laing FC, Hricak H, McAninch JW. Sonography of testicular trauma. *AJR Am J Roentgenol* 1983; 141:993-5.
2. Berman JM, Beidle TR, Kunberger LE, Letourneau JG. Sonographic evaluation of acute intrascrotal pathology. *AJR Am J Roentgenol* 1996; 166:857-61.
3. Horstman WG. Scrotal imaging. *Urol Clin North Am* 1997; 24:653-71.
4. Pavlica P, Barozzi L. Imaging of the acute scrotum. *Eur Radiol* 2001; 11:220-8.
5. Dogra VS, Gottlieb RH, Oka M, Rubens DJ. Sonography of the scrotum. *Radiology* 2003; 227:18-36.
6. Cass AS, Luxenberg M. Testicular injuries. *Urology* 1991; 37:528-30.
7. Bree RL, Hoang DT. Scrotal ultrasound. *Radiol Clin North Am* 1996; 34:1183-205.
8. Benson CB, Doubilet PM, Richie JP. Sonography of the male genital tract. *AJR Am J Roentgenol* 1989; 153:705-13. Comment in: *AJR Am J Roentgenol* 1990; 155:423.
9. Tumei SS, Benson CB, Richie JP. Acute diseases of the scrotum. *Semin Ultrasound CT MR* 1991; 12:115-30.
10. Horstman WG, Melson GL, Middleton WD, Andriole GL. Testicular tumors: findings with color Doppler US. *Radiology* 1992; 185:733-7.
11. Muttarak M. Anatomy and diseases of the scrotum. *J Hong Kong Coll Radiol* 2000; 3:83-93.

SINGAPORE MEDICAL COUNCIL CATEGORY 3B CME PROGRAMME
Multiple Choice Questions (Code SMJ 200703B)

	True	False
Question 1. Concerning scrotal injury:		
(a) It usually results from penetrating injury.	<input type="checkbox"/>	<input type="checkbox"/>
(b) Physical examination is difficult to differentiate an uncomplicated haematocoele from testicular rupture.	<input type="checkbox"/>	<input type="checkbox"/>
(c) Surgery should be performed within the first 72 hours after injury if there is testicular rupture.	<input type="checkbox"/>	<input type="checkbox"/>
(d) Testicular atrophy, discomfort and infection are common complications if testicular injury is left untreated.	<input type="checkbox"/>	<input type="checkbox"/>
Question 2. Concerning scrotal US:		
(a) It is accurate to determine whether there is solely haematocoele.	<input type="checkbox"/>	<input type="checkbox"/>
(b) It is accurate to determine whether there is intratesticular haematoma.	<input type="checkbox"/>	<input type="checkbox"/>
(c) It is accurate to determine whether there is testicular rupture.	<input type="checkbox"/>	<input type="checkbox"/>
(d) Colour Doppler US is not helpful.	<input type="checkbox"/>	<input type="checkbox"/>
Question 3. Concerning scrotal haematoma:		
(a) It may occur at the testis, epididymis or scrotal wall.	<input type="checkbox"/>	<input type="checkbox"/>
(b) High-frequency transducer should be used in cases with a large haematoma.	<input type="checkbox"/>	<input type="checkbox"/>
(c) Haematoma may appear as heterogeneous echoic mass or a complex mass with cystic components.	<input type="checkbox"/>	<input type="checkbox"/>
(d) A large scrotal haematoma may displace the testis from the US field-of-view causing a false positive diagnosis of testicular rupture.	<input type="checkbox"/>	<input type="checkbox"/>
Question 4. Concerning intratesticular haematoma:		
(a) It may mimic tumour, abscess, and infarct.	<input type="checkbox"/>	<input type="checkbox"/>
(b) It is hypervascular on colour Doppler US.	<input type="checkbox"/>	<input type="checkbox"/>
(c) Acute haematoma is seen as a hypoechoic mass.	<input type="checkbox"/>	<input type="checkbox"/>
(d) Surgery can be avoided in cases with a small intratesticular haematoma with an intact testis.	<input type="checkbox"/>	<input type="checkbox"/>
Question 5. Concerning testicular rupture:		
(a) Irregular or indistinct testicular contour indicates testicular rupture.	<input type="checkbox"/>	<input type="checkbox"/>
(b) The presence of haematocoele alone is highly indicative of presence of testicular rupture.	<input type="checkbox"/>	<input type="checkbox"/>
(c) A discrete fracture line in the testis is seen in only 17% of cases.	<input type="checkbox"/>	<input type="checkbox"/>
(d) Correct surgical management can be guided with the additional use of colour Doppler US.	<input type="checkbox"/>	<input type="checkbox"/>

Doctor's particulars:

Name in full: _____

MCR number: _____ Specialty: _____

Email address: _____

SUBMISSION INSTRUCTIONS:

(1) Log on at the SMJ website: www.sma.org.sg/cme/smj and select the appropriate set of questions. (2) Select your answers and provide your name, email address and MCR number. Click on "Submit answers" to submit.

RESULTS:

(1) Answers will be published in the SMJ May 2007 issue. (2) The MCR numbers of successful candidates will be posted online at www.sma.org.sg/cme/smj by 15 May 2007. (3) All online submissions will receive an automatic email acknowledgment. (4) Passing mark is 60%. No mark will be deducted for incorrect answers. (5) The SMJ editorial office will submit the list of successful candidates to the Singapore Medical Council.

Deadline for submission: (March 2007 SMJ 3B CME programme): 12 noon, 25 April 2007