

Laparoscopic surgery for perforation of Meckel's diverticulum

Rangarajan M, Palanivelu C, Senthilkumar R, Madankumar M V

ABSTRACT

We report an eight-year-old boy who presented with features of peritonitis and a vague mass in the periumbilical area. Initial clinical diagnosis was an appendicular abscess. Diagnostic laparoscopy revealed an inflammatory mass with pus due to a perforated Meckel's diverticulum. Laparoscopic stapler resection of the lesion was done and the patient recovered uneventfully. Surgical resection is indicated only if the diverticulum is symptomatic or if the base is narrow. Wedge resection of the diverticulum, including anterior wall of ileum, or stapler resection can be performed. Laparoscopy is useful in both diagnosis and treatment. Laparoscopic resection of Meckel's diverticulum is feasible and ideal, especially in specialised centres.

Keywords: bowel perforation, endostaples, laparoscopic surgery, laparoscopy, Meckel's diverticulitis

Singapore Med J 2007;48(4):e102-e105

INTRODUCTION

Meckel's diverticulum is a rare congenital disorder that was first described about 400 years ago. Diagnosis is rarely made preoperatively as there may be no symptoms. The incidence of Meckel's diverticulum is usually quoted as being approximately 2% of the population, but the prevalence can vary from 0.2% to 4%.⁽¹⁾ The male-to-female ratio of symptomatic diverticulum is 3:1. It is a diverticular remnant of the omphalomesenteric duct that is located on the antimesenteric border of the ileum, a short distance from the caecum (60 cm proximal to the ileocaecal valve). On average, the diverticulum is 2.99 cm long and 1.92 cm wide. Although jejunal, colonic, rectal, pancreatic, duodenal, and endometrial tissues have all been found in the diverticulum, the heterotopic mucosa is likely to be gastric in origin in 80% of cases.⁽²⁾ As a result, the gastric acid secreted from this lining erodes tissue, ultimately causing haemorrhage. Diagnosis of a bleeding Meckel's diverticulum is established by technetium-99m pertechnate scan ("Meckel scan").

Laparoscopy, however, is the most accurate diagnostic tool.⁽³⁾ Laparoscopic resection of perforated Meckel's diverticulum in a patient with clinical symptoms of acute appendicitis was reported by Ruh et al.⁽⁴⁾ We present a similar case of perforated Meckel's diverticulum in a child managed by laparoscopy.

CASE REPORT

The patient was an eight-year-old boy with clinical features of localised peritonitis. Physical examination showed an ill-defined mass in the right lower quadrant, in the vicinity of the umbilicus. Radiograph of the abdomen was essentially normal. Ultrasonography revealed an inflammatory mass in the area of the appendix, suggestive of appendicular perforation. Diagnostic laparoscopy was planned for him, with a possibility of appendicectomy. Open technique was used to establish pneumoperitoneum and the pressure was maintained at 12 mmHg. A 10 mm trocar was inserted into the umbilicus, a 5 mm trocar was introduced in the suprapubic area, and another 5 mm trocar in the right lower quadrant, under direct vision. A 10 mm (30°) laparoscope was introduced into the 10 mm port for diagnostic laparoscopy, which revealed a mass involving the caecum and ileum. Few inflammatory flakes were seen in the area. The 10 mm laparoscope was removed from the umbilical port and replaced with a 5 mm (30°) laparoscope introduced into the 5 mm suprapubic port. The camera surgeon stood on the left of the chief surgeon. The umbilical port was used for the right hand instrument and the right lower quadrant port was used for the left hand instrument. This is the port position that we use for all laparoscopic appendicectomies in our institute because it allows for "triangulation".

The bowel loops were gently separated using the tip of a suction nozzle. The appendix was visualised, inspected and found to be normal. We proceeded with the appendicectomy. Further separation of the loops of ileum revealed a pocket of pus, within which a perforated Meckel's diverticulum was seen (Fig. 1). Thorough peritoneal lavage was performed and the decision to resect the diverticulum was made. An endostapler (Endoscopic Articulating Linear Cutter, size 45 mm) was introduced into a 12 mm trocar, replacing the 10 mm umbilical trocar. It was applied to

Department of Surgical Gastroenterology, GEM Hospital, 45A Pankaja Mill Road, Rammathapuram, Coimbatore 641045, India

Rangarajan M, DipMIS Registrar

Palanivelu C, MCh, FRCS, FACS Director

Senthilkumar R, MS Registrar

Madankumar MV, MS Registrar

Correspondence to: Dr Muthukumaran Rangarajan Tel: (91) 422 232 4105 Fax: (91) 422 232 0879 Email: rangy68@gmail.com

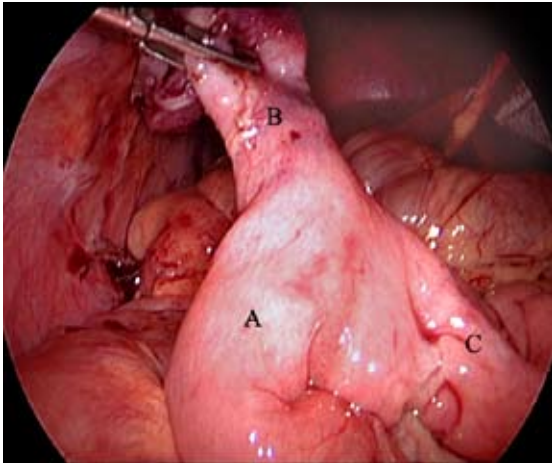


Fig. 1 Operative photograph shows the terminal ileum (A), inflamed Meckel's diverticulum (B), and proximal ileum (C).

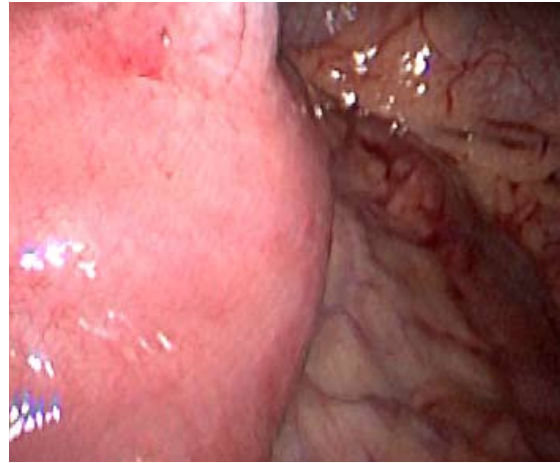


Fig. 2 Operative photograph shows application of the endostapler to the base of the diverticulum.

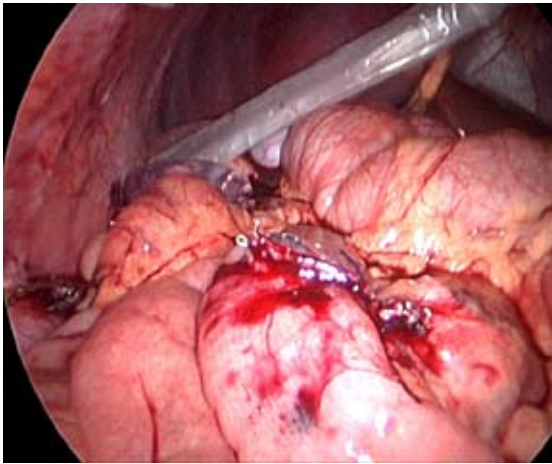


Fig. 3 Operative photograph shows the transverse staple line on the ileum after firing the endostapler.

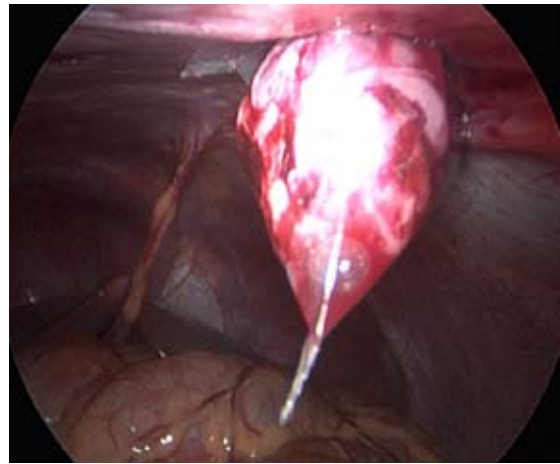


Fig. 4 Operative photograph shows the endobag that was used for specimen delivery.

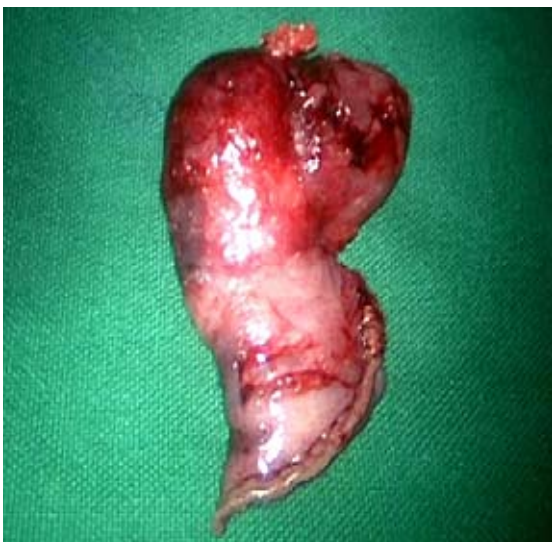

Fig. 5 Photograph of the resected specimen.

the base of the diverticulum, perpendicular to the long axis of the ileum (Fig. 2). The stapler was fired and the diverticulum was resected off the ileum (Fig. 3). A small bleeding point at the edge of the staple line was sutured intracorporeally with three zero vicryl. Another peritoneal lavage was given and the specimen was delivered through the enlarged 12 mm umbilical port with the use of an endobag (Fig. 4). A drainage tube was kept in the peritoneal cavity and fixed to the abdominal wall. The resected specimen was grossly oedematous and inflamed (Fig. 5). Operating time was 110 minutes.

The patient was allowed liquids orally on the third postoperative day (POD) and soft diet the next day. The drainage tube was removed on the second POD. He was discharged on the fifth POD, after he

had passed stools. There was no port site infection. Histopathology showed heterotopic gastric mucosa within the diverticulum and evidence of acute inflammation with perforation. The patient was followed up for two years and is symptom-free.

DISCUSSION

Meckel's diverticulum is the most common form of congenital abnormality of the small intestine, resulting from an incomplete obliteration of the vitelline duct. Although originally described by Fabricius Hildanus in 1598, it is named after Johann Friedrich Meckel, who established its embryonic origin between 1808 and 1820.⁽⁵⁾ The tip of the diverticulum is free in 75% of cases and in 25%, the tip is attached to another organ or structure by means of a band. Most patients are asymptomatic, and it is usually an incidental finding when a barium study or laparotomy is performed for other abdominal conditions. Complications include bowel obstruction (35%), haemorrhage (32%), diverticulitis (22%), umbilical fistula (10%), perforation (5%), other umbilical lesions (1%) and intussusception.⁽⁶⁾

Meckel's diverticulitis may mimic appendicitis. The correct diagnosis is usually established at the laparotomy or laparoscopy. None of the clinical features are pathognomonic, and the diagnosis is rarely made preoperatively. Routine laboratory studies, such as leukocyte and erythrocyte counts, serum electrolytes, blood glucose and urea, serum creatinine and coagulation screen are helpful in the general work-up. These tests will show evidence of acute infection. Computed tomography and ultrasonography have been used for the diagnosis of Meckel's diverticulum but despite the availability of modern imaging techniques, the diagnosis is challenging. Laparoscopy is more useful in this situation as it is clinically difficult to distinguish between diverticulitis and appendicitis.

In our patient, appendicular perforation was the clinical diagnosis. Laparoscopy revealed no perforation of the appendix but a perforated Meckel's diverticulum. Nevertheless, we performed appendectomy in our patient. Laparoscopic appendectomy is almost routine for appendicitis in paediatric patients, as evidenced by many studies.^(7,8) Definitive treatment of a complication, such as bleeding, is the excision of the diverticulum.⁽⁹⁾ Successful resection of a Meckel's diverticulum can also be accomplished through laparoscopy, using endostapling devices.⁽¹⁰⁾ The child with an acute abdomen presents a situation where the advantages and benefits of minimal-access surgery can be truly appreciated. Acute abdomen may be caused by acquired or congenital conditions, for which minimal-access techniques

provide both the diagnosis and therapy.⁽¹¹⁾ There are many reports that describe large series of paediatric patients that are subjected to diagnostic laparoscopy with or without a corrective procedure.⁽¹⁰⁻¹²⁾ Our patient is an example of the benefits of laparoscopy.

Management of Meckel's diverticulum in asymptomatic patients is controversial. Excision is mandatory for all symptomatic diverticuli. With the advent of gastrointestinal stapling devices, excision has become safer, faster and more efficient. Another advantage of stapling is that it closes the bowel lumen as it cuts, thereby completely reducing the chance of contamination. A drawback is the high cost. The only exception to excision is if the diverticulum is so broad-based or so short that stapled excision cannot be technically performed.⁽¹³⁾ If the diverticulum is too short, there is a danger of including too much of the ileum during stapling or leaving behind part of the diverticulum. Either way, both possibilities are undesirable. In such situations, resection can be done with a 5 mm Harmonic scalpel (Ethicon, Cincinnati, OH, USA) and the enterotomy closed with intracorporeal vicryl sutures. Another way to accomplish excision is to exteriorise the diverticulum via a minilaparotomy incision, resection and closing the enterotomy with sutures. If the base of the diverticulum is also inflamed, a wedge resection including part of the normal ileum has to be performed. In our patient, this was not the case, so resection of the lesion alone will suffice. The direction of the staple line should lie perpendicular to the ileum and not longitudinally. This will ensure that the ileal lumen is not compromised. The articulating head of the stapler is invaluable in these situations as it can be manoeuvred precisely on the base of the diverticulum. Laparoscopy has a definite role in paediatric patients with symptomatic Meckel's diverticulum, especially when the diagnosis is in doubt. It provides all the benefits of minimally invasive surgery.

REFERENCES

1. Shalaby RY, Soliman SM, Fawy M, Samaha A. Laparoscopic management of Meckel's diverticulum in children. *J Pediatr Surg* 2005; 40:562-7.
2. Memon AA, Memon GA, Ansari AG, Ghumro AA. Symptomatic Meckel's diverticulum. *J Coll Physicians Surg Pak* 1999; 9:476-9.
3. Schmid SW, Schafer M, Krahenbuhl L, Buchler MW. The role of laparoscopy in symptomatic Meckel's diverticulum. *Surg Endosc* 1999; 13:1047-9.
4. Ruh J, Paul A, Dirsch O, Kaun M, Broelsch CE. Laparoscopic resection of perforated Meckel's diverticulum in a patient with clinical symptoms of acute appendicitis. *Surg Endosc* 2002; 16:1638-9.
5. Fansler RF. Laparoscopy in the management of Meckel's diverticulum. *Surg Laparosc Endosc* 1996; 6:231-3.

6. Vernon AH, Georgeson KE, Harmon CM. Pediatric laparoscopic appendectomy for acute appendicitis. *Surg Endosc* 2004; 18:75-9. Erratum in: *Surg Endosc* 2004; 18:568.
7. el Ghoneimi A, Valla JS, Limonne B, et al. Laparoscopic appendectomy in children: report of 1,379 cases. *J Pediatr Surg* 1994; 29:786-9.
8. Cullen JJ, Kelly KA. Current management of Meckel's diverticulum. *Adv Surg* 1996; 29:207-14.
9. Altinli E. Laparoscopy-assisted resection of complicated Meckel's diverticulum (author's reply). *Surg Laparosc Endosc Percutan Tech* 2002; 12:450-1.
10. Sanders LE. Laparoscopic treatment of Meckel's diverticulum. Obstruction and bleeding managed with minimal morbidity. *Surg Endosc* 1995;9:724-7.
11. Lobe TE. Acute abdomen. The role of laparoscopy. *Semin Pediatr Surg* 1997; 6:81-7.
12. Huang CS, Lin LH. Laparoscopic Meckel's diverticulectomy in infants: report of three cases. *J Pediatr Surg* 1993; 28:1486-9.
13. Echenique M, Dominguez AS, Echenique I, Rivera V. Laparoscopic diagnosis and treatment of Meckel's diverticulum complicated by gastrointestinal bleeding. *J Laparoendosc Surg* 1993; 3:145-8.