

CME Article

Hysterosalpingography: current applications

Eng C W, Tang P H, Ong C L

ABSTRACT

With the recent advances in reproductive medicine, hysterosalpingography has become a relatively quick and non-invasive examination to evaluate fallopian tubes and uterine cavity. It remains the best modality to image fallopian tubes. Congenital uterine malformations, technical artefacts and pathological findings are depicted. Pathological findings that can be detected on hysterosalpingography include salpingitis isthmica nodosa, tubal blockage, peritubal adhesion, submucosal leiomyoma, endometrial polyp, endometrial carcinoma, synechiae and adenomyosis.

Keywords: fallopian tube, hysterosalpingography, reproductive medicine, uterus

Singapore Med J 2007; 48(4):368–374

INTRODUCTION

With the recent advances in reproductive medicine, hysterosalpingography has become a relative quick and non-invasive examination to evaluate the fallopian tubes and uterine cavity. It remains the best modality to image the fallopian tubes. Radiation risks from a typical hysterosalpingography are also low.⁽¹⁾ In addition, there is also a controversial point that the procedure may be therapeutic.^(2,3) The purpose of this pictorial essay is to illustrate the spectrum of technical artefacts, congenital uterine malformations and pathological findings encountered during hysterosalpingography.

TECHNIQUE

In our institution, hysterosalpingography is carried out within the first ten days after the last menstrual period **and when menstrual flow has ceased**. The patient is advised to abstain from sexual intercourse in the days after her menses and prior to the procedure, to ensure that she is not pregnant during the procedure. Using an aseptic technique, a speculum is used to distend the vagina and an 8F Foley catheter is inserted into the uterine cavity. Diluted, water soluble, hyperosmolar iodinated contrast agent (Telebrix 35, Guerbet, Aulnay-sous-Bois, France) is then hand injected into the uterine cavity via the Foley catheter. A normal hysterosalpingogram depicts

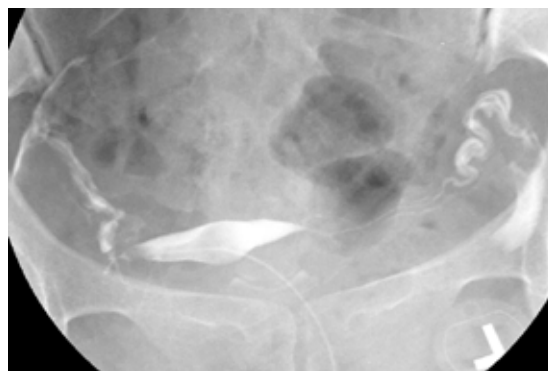


Fig. 1 Normal hysterosalpingogram shows a smooth triangular outline of the uterine cavity and free spillage of contrast from both fallopian tubes.

a smooth triangular uterine outline with opacification of both fallopian tubes and free spillage of contrast into the peritoneum (Fig. 1). Occasionally, in difficult cases, the Leech-Wilkinson or other uterine catheters may be used.

TECHNICAL ARTIFACTS**Air bubbles**

Air bubbles are often inadvertently introduced into the uterine cavity during hysterosalpingography. When multiple air bubbles are present, they can be easily recognised. However, a single air bubble can be mistaken for other uterine pathologies, such as a polyp or a submucosal fibroid. An air bubble is seen as a mobile, spherical and well-defined filling defect. Its mobility and lack of persistence indicates its nature (Fig. 2). It is possible to aspirate the air bubble and re-inject the contrast agent to show a normal uterine cavity. Alternatively, the air bubble can be expelled into the peritoneal cavity. Another indication of its true nature is that air bubbles move to the non-dependant part of the uterus when the patient turns.

Contrast intravasation

Contrast intravasation can occur via the venous or lymphatic routes. Predisposing factors include increased intrauterine pressure or recent uterine surgery. It can also be seen in a normal examination. In our institution, a water-soluble contrast agent is administered for hysterosalpingography and contrast intravasation

Department of
Diagnostic Imaging,
KK Women's and
Children's Hospital,
100 Bukit
Timah Road,
Singapore 229899

Eng CW, MBBS
Medical Officer

Tang PH, MBBS,
MMed, FRCR
Associate Consultant

Ong CL, MBBS,
FRCR
Senior Consultant

Correspondence to:
Dr Chee-Way Eng
Tel: (65) 9834 9980
Fax: (65) 6256 2860
Email: engcheeway@
yahoo.com.sg

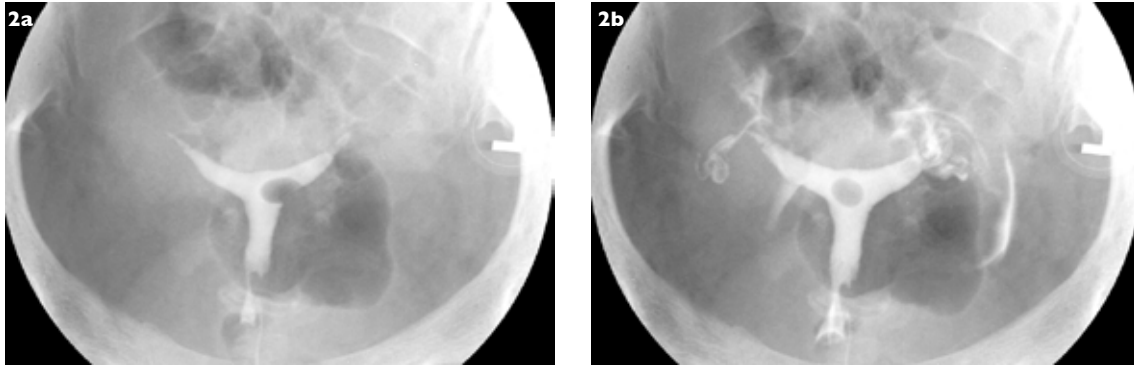


Fig. 2 Artifact due to air bubble. (a) Hysterosalpingogram shows a well-defined filling defect in the left lateral aspect of the uterine cavity. (b) The filling defect is mobile and is now seen in the middle of the uterine cavity, compatible with an air bubble.

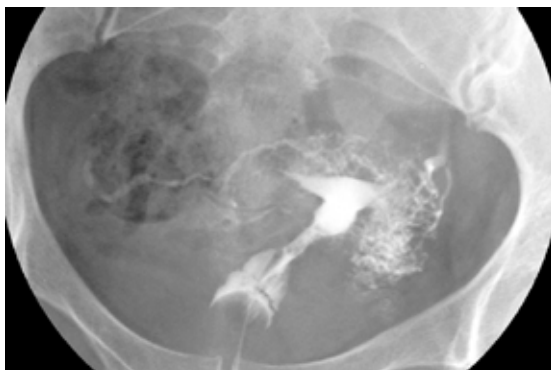


Fig. 3 Artifact due to venous intravasation. Hysterosalpingogram shows multiple linear densities forming a reticular pattern adjacent to the outlined uterine cavity with opacification of the left ovarian vein, compatible with venous contrast intravasation.

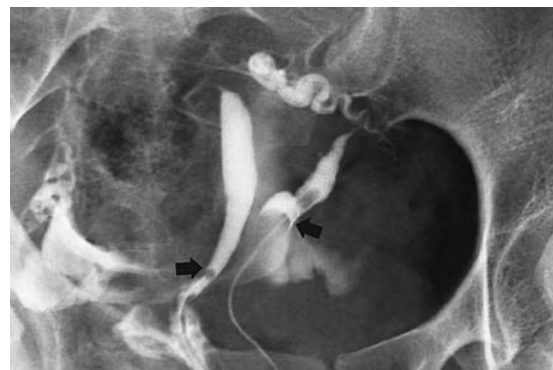

Fig. 4 Didelphys uterus. Hysterosalpingogram shows two cervixes (arrows) that were cannulated separately, and leading to their corresponding uterine cavities.

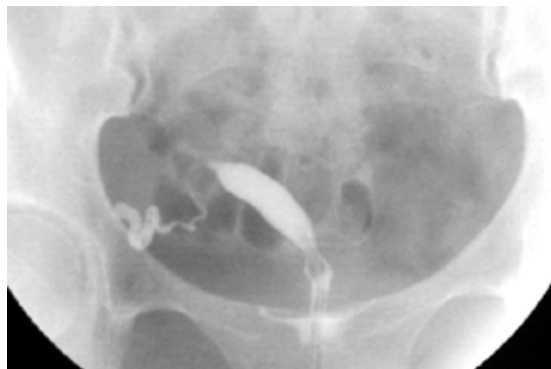

Fig. 5 Unicornuate uterus. Hysterosalpingogram shows opacification of a single left uterine horn. The other uterine horn was rudimentary and was only visualised on ultrasonography.

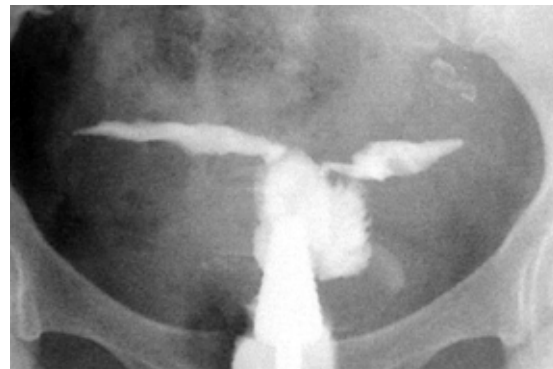

Fig. 6 Bicornuate uterus. Hysterosalpingogram shows a wide separation of the two uterine horns.

usually does not cause any adverse effect.⁽⁴⁾ It is seen radiographically as multiple thin lines, forming a reticular pattern (Fig. 3) and should not be mistaken for opacification of the fallopian tubes. In some cases, the ovarian veins may be opacified. While the contrast agent in the opacified fallopian tubes tend to persist, contrast in the veins and lymphatics tend to wash out once the injection stops.

CONGENITAL UTERINE MALFORMATIONS

Mullerian ducts anomalies

There is a spectrum of uterine anomalies related to defects of Mullerian duct fusion. These include uterus didelphys (Fig. 4), unicornuate uterus (Fig. 5), bicornuate uterus (Fig. 6), septate uterus (Fig. 7) and arcuate uterus (Fig. 8). The most common anomaly is the arcuate uterus, which has no impact on fertility. The arcuate

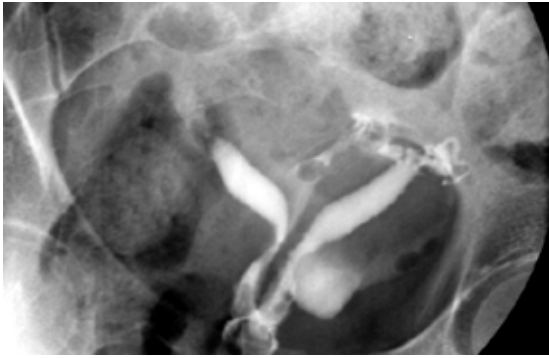


Fig. 7 Septate uterus. Hysterosalpingogram shows a deep cleft separating the two horns of the uterus. Both septate and bicornuate uterus may have a similar appearance on hysterosalpingography. Accurate differentiation will require 3D ultrasonography or MR imaging.

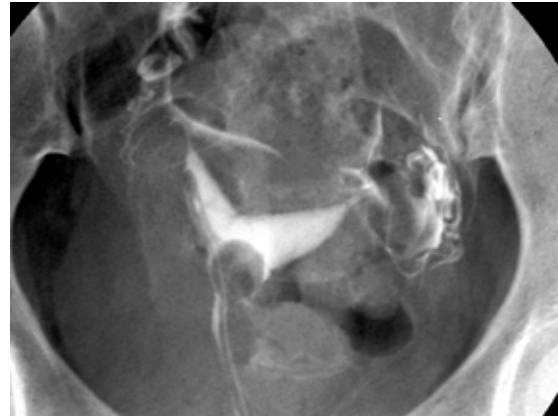

Fig. 8 Arcuate uterus. Hysterosalpingogram shows indentation of the uterine cavity outline in the fundal region, compatible with an arcuate uterus.

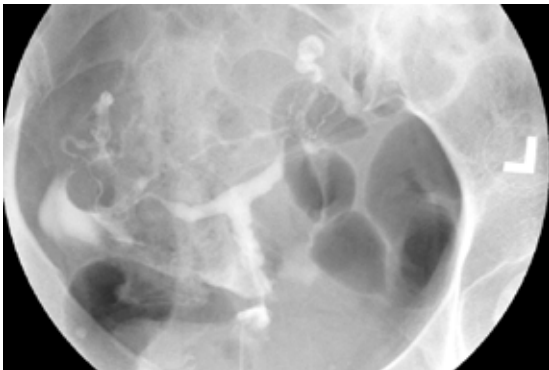

Fig. 9 Infantile uterus. Hysterosalpingogram shows a T-shaped uterine cavity with a 1:1 ratio between the uterine body and cervix, compatible with an infantile uterus.

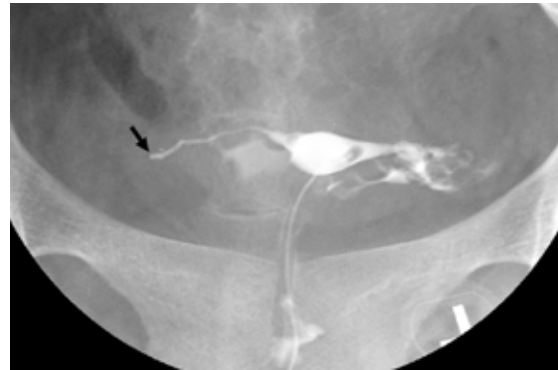

Fig. 10 This patient had previous right salpingectomy for ectopic pregnancy. Hysterosalpingogram shows only opacification of the proximal segment of the right fallopian tube with abrupt cut-off at the isthmic portion (arrowed). There is normal opacification of the left fallopian tube with spillage of contrast.

uterus has a smooth convex fundal mucosal margin on the hysterosalpingogram and a smooth fundal serosal outline on ultrasonography or magnetic resonance (MR) imaging. The presence of septate uterus and bicornuate uterus is inferred from the angle between the uterine horns. A wider or obtuse angle favours the diagnosis of a bicornuate uterus. However, they may appear similar on hysterosalpingogram and require correlation with ultrasonography or MR imaging, as accurate differentiation of these anomalies requires visualisation of the external contour of the uterus. MR imaging and recently, three-dimensional ultrasonography, are the preferred modalities.⁽⁵⁾

Infantile (T-shaped) uterus

Infantile uterus is seen as a T-shape uterine cavity on hysterosalpingography with a 1:1 ratio between the uterine body and cervix (Fig. 9). This is in contrast with the normal adult uterus where the uterine body comprises 60%–70% of the total uterine length. Infantile

uterus is associated with maternal diethylstilbestrol exposure, oestrogen deficiency or prolonged intake of oral contraceptives by the patient.⁽⁶⁾

COMMON PATHOLOGICAL FINDINGS

Tubal occlusion

Evaluation of the patency of the fallopian tubes is usually the main purpose for carrying out hysterosalpingography. Fallopian tube occlusion can occur secondary to inflammation or previous surgery. It may be the sequelae of pelvic inflammatory disease, and any segment of the fallopian tube can be involved. Radiographically, it manifests as non-opacification or abrupt cut-off of the fallopian tube with no free intra-peritoneal spillage (Fig. 10). However, a common pitfall is non-opacification of the fallopian tube due to spasm. This entity may require administration of an antispasmodic or selective cannulation of the tube to distinguish it from a truly blocked tube.⁽⁷⁾

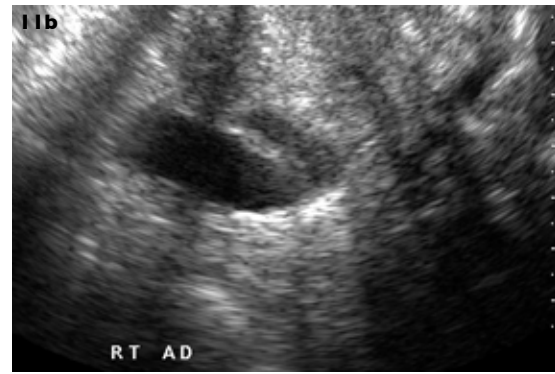
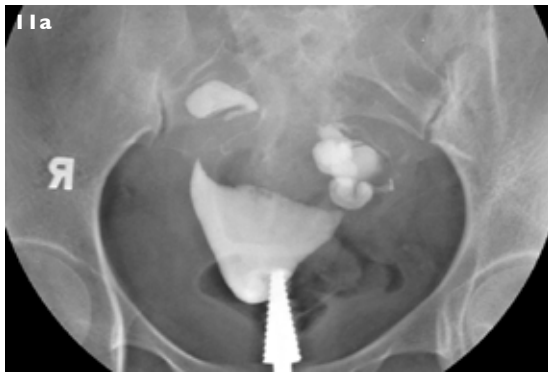


Fig. 11 Bilateral hydrosalpinges. (a) Hysterosalpingogram shows tubular convoluted structures on both sides of the uterus, representing bilateral hydrosalpinges. No intra-peritoneal spillage of contrast is demonstrated. (b) Corresponding ultrasonography image shows the right hydrosalpinx as a tubular cystic structure in the right adnexa containing internal echoes.

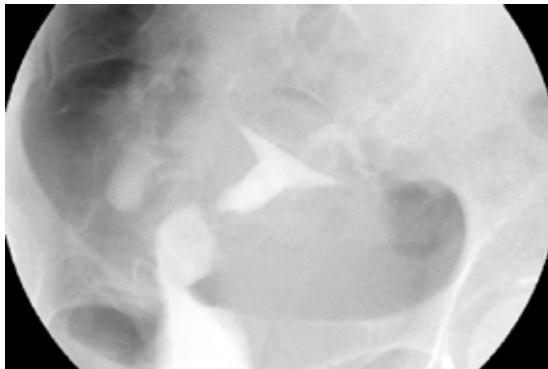


Fig. 12 Peritubal adhesions. Hysterosalpingogram shows pooling of the contrast agent which had spilled from the right fallopian tube, secondary to peritubal adhesions. The contrast agent does not outline the peritoneal folds or the bowel loops.

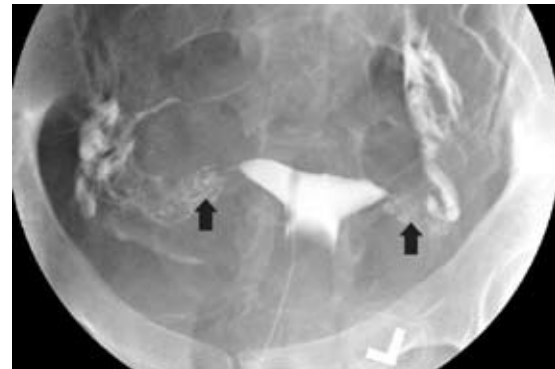


Fig. 13 Salpingitis isthmica nodosa. Hysterosalpingogram shows small outpouchings in the isthmus region (arrowed) of both fallopian tubes. These represent the protruded tubal epithelium, characteristic of salpingitis isthmica nodosa.

Hydrosalpinx

This is usually the sequelae of distal tubal occlusion leading to dilatation of the proximal segment. The hydrosalpinx is seen as a dilated, convoluted tubular structure on hysterosalpingography (Fig. 11).

Peritubal adhesion

Peritubal adhesions occurs secondary to previous inflammation or surgery, similar to the causes of tubal occlusion. Adhesions around the fallopian tube results in loculation of contrast material that has spilled from the fallopian tubes (Fig. 12). The spilled contrast material does not outline the peritoneal folds or bowel loops, as seen in normal cases.

Salpingitis isthmica nodosa

This entity is of unknown aetiology and is presumed to be post-inflammatory. It is associated with ectopic pregnancy and infertility. Microscopically, it consists of pockets of tubal epithelium that protrude through the tube to lie beneath the serosa.⁽⁸⁾ Corresponding radiological findings are small outpouchings or

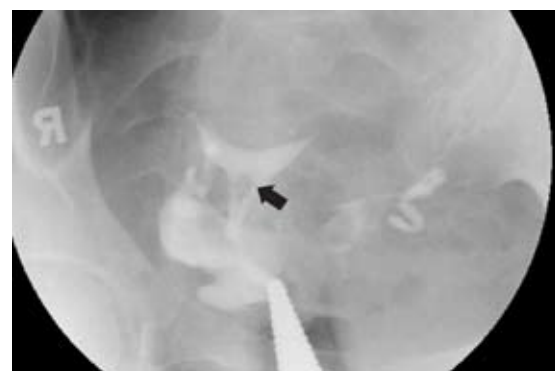

Fig. 14 Synechia. Hysterosalpingogram shows a linear filling defect (arrowed) in the uterine cavity, representing adhesions seen in synechia.

diverticula, mainly at the isthmus segment of the fallopian tube (Fig. 13).

Synechia

Synechia refers to adhesions within the uterine cavity from scarring. This can be a result of endometrial infection or from previous dilation and curettage.

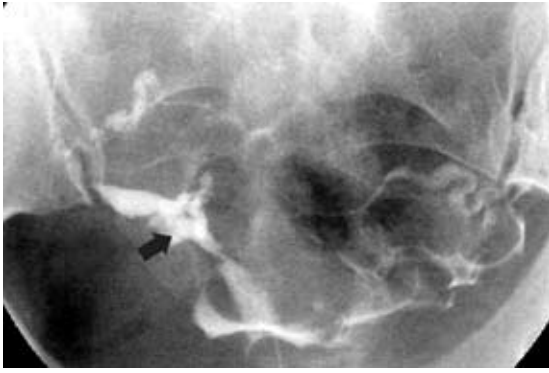


Fig. 15 Asherman's syndrome. Hysterosalpingogram shows a severe form of intrauterine adhesion with distortion of the uterine cavity (arrowed). It is known as Asherman's syndrome when it is associated with amenorrhoea and infertility.

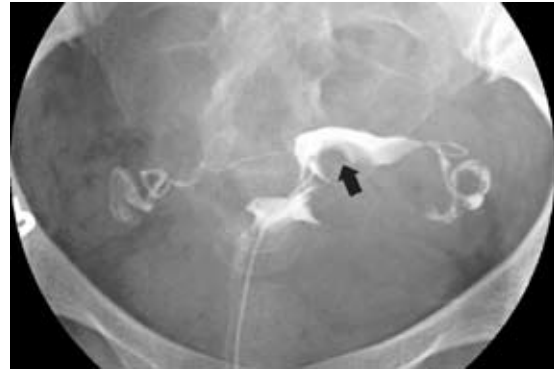

Fig. 16 Submucosal fibroids. Hysterosalpingogram shows a distorted uterine cavity (arrowed) with loss of the normal triangular shape by multiple submucosal fibroids. The fibroids are well demonstrated in a separate ultrasonography examination, which is not shown here.

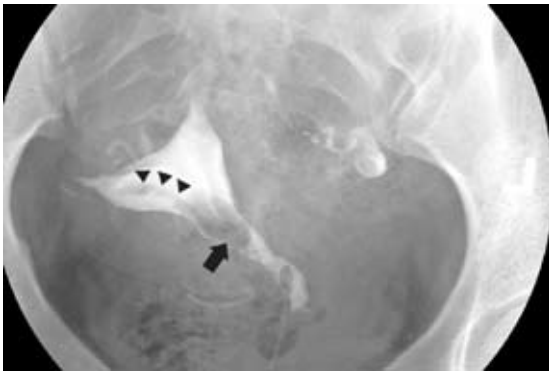

Fig. 17 Endometrial lesion. Hysterosalpingogram shows a well-defined filling defect in the lower uterine body (arrowed) with a stalk (arrowheads) arising from the right cornu, representing an endometrial polyp or fibroid.

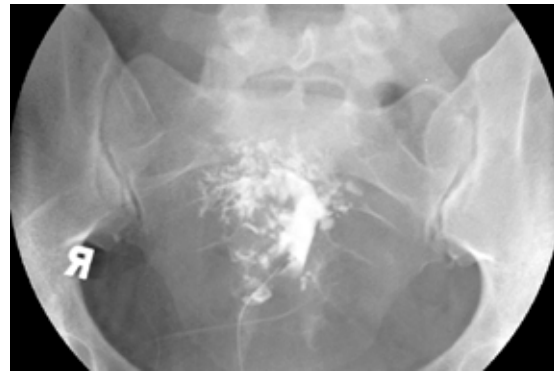

Fig. 18 Adenomyosis. Hysterosalpingogram shows adenomyosis with irregular branching outpouchings radiating from the uterine cavity, representing extension of the endometrial glands into the myometrium.

It is usually seen as a linear irregular filling defect in the opacified uterine cavity (Fig. 14). It is important to recognise this filling defect during the early filling phase of the uterine cavity. Excessive amount of contrast agent within the uterine cavity may obscure this finding. The most severe form of adhesions is known as Asherman's syndrome (Fig. 15), which is associated with amenorrhoea and infertility.

Submucosal leiomyoma

Leiomyomas are associated with habitual abortion, especially the submucosal type. Submucosal leiomyomas present as well-defined filling defects which distort the uterine cavity on hysterosalpingography (Fig. 16). Small intramural or subserosal leiomyomas do not distort the endometrial cavity and are not visualised on hysterosalpingography.

Endometrial polyp

Endometrial polyp presents as a well-defined filling defect, sometimes with a visible stalk (Fig. 17). This lesion is again better appreciated during the early filling

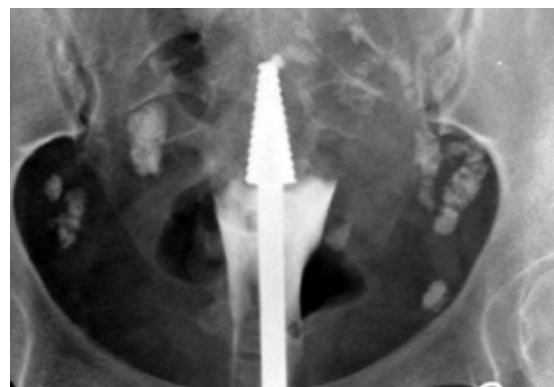


Fig. 19 Endometrial tuberculosis. Hysterosalpingogram shows that the uterine cavity is severely scarred and obliterated by previous endometrial tuberculosis. All the contrast agent injected has refluxed into the vagina, with no filling of the uterine cavity. Multiple calcified densities in the pelvis represent calcified lymph nodes.

phase of the procedure. Saline infusion hysterosonography or hysteroscopy is the modality of choice for characterisation of this lesion. However, hysterosalpingography remains a useful screening test for evaluation of the uterine cavity, as it has a fairly high sensitivity.⁽⁹⁾

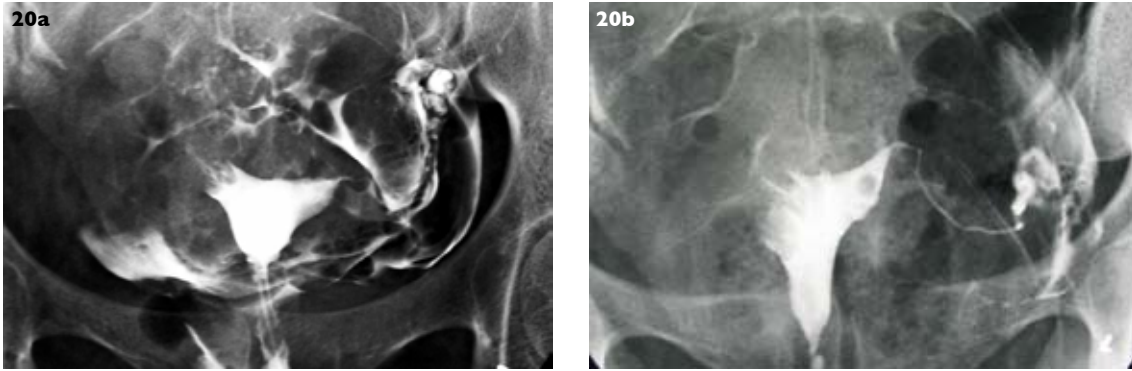


Fig. 20 Endometrial carcinoma (a) Initial hysterosalpingogram shows a filling defect in the right cornual region, with non-opacification of the right fallopian. Initially, the appearance was attributed to cornual spasm. (b) Repeat hysterosalpingogram done five months later, when the patient returned for selective right tubal cannulation, shows that the irregular right cornual filling defect had increased in size. Histology confirmed endometrial carcinoma. The filling defect in the left side of the uterine cavity is an air bubble.

Adenomyosis

Adenomyosis is a condition where the endometrial glands extend deep into the myometrium. MR imaging is highly accurate for detection of adenomyosis. This condition is only occasionally recognised on hysterosalpingography, if there is a connection between the ectopic endometrial glands and the endometrial cavity. It manifests as irregular branching outpouchings that are continuous with the uterine cavity (Fig. 18). Adenomyosis is associated with infertility. Its exact pathophysiology is still not clear, and may be related to the high level of nitrous oxide and altered immune response in the affected uterus.⁽¹⁰⁾

Endometrial tuberculosis

The appearance of endometrial tuberculosis on hysterosalpingography is non-specific, and includes synechiae, distorted uterine cavity outline or contrast intravasation. However, the presence of calcified pelvic lymph nodes and severe adhesions, with obliteration of the endometrial cavity (Fig. 19), strongly supports the diagnosis.⁽¹¹⁾ Tuberculosis can also affect other parts of the genital tract and is an important cause of infertility in developing countries.

Endometrial carcinoma

Rarely, an irregular filling defect may represent a more sinister finding such as endometrial carcinoma, especially if it demonstrates interval growth. This may represent an incidental finding on routine hysterosalpingography and should not be overlooked (Fig. 20). Hysteroscopy and ultrasonography are the investigations of choice for the evaluation of endometrial disease.⁽¹²⁾

CONCLUSION

A wide variety of uterine and tubal abnormalities can be demonstrated with hysterosalpingography. Some of these abnormalities have an impact on the patient's fertility and require treatment if conception is to be achieved. It is important to recognise these findings. At the same time, artefacts should also be identified and not be misdiagnosed as being pathological.

REFERENCES

- Persinakis K, Damilakis J, Grammatikakis J, Theocharopoulos N, Gourtsoyiannis N. Radiogenic risks from hysterosalpingography. *Eur Radiol* 2003; 13:1522-8
- Spring DB, Barkan HE. Enhanced fertility after diagnostic hysterosalpingography may be a myth. (commentary) *AJR* 2004; 183:1728.
- Johnson NP, Hadden WE, Chamley LW. Fertility enhancement by hysterosalpingography with oil-soluble contrast media: Reality not myth. (letters) *AJR* 2005; 185:1654-7.
- Simpson WL, Beitia LG, Mester J. Hysterosalpingography: A reemerging study. *AJR* 2006; 26:419-31.
- Braun P, Grau VF, Pons RM, Enguix DP. Is hysterosalpingography able to diagnose all uterine malformation correctly? A retrospective study. *Eur J Radiol* 2005; 53:274-9.
- Ubeda B, Paraira M, Alert E, Abuin RA. Hysterosalpingography: Spectrum of normal variants and nonpathological findings. *AJR* 2001; 177:131-5.
- Winfield AC, Pittaway D, Maxson W, Daniel J, Wentz AC. Apparent cornual occlusion in hysterosalpingography: Reversal by Glucagon. *AJR* 1982; 139:525-7.
- Jenkins CS, Williams SR, Schmidt GE. Salpingitis isthmica nodosa: a review of the literature, discussion of clinical significance, and consideration of patient management. *Fertil Steril* 1993; 60:599-607.
- Dalfo AR, Ubeda B, Ubeda A, et al. Diagnostic value of hysterosalpingography in the detection of intrauterine abnormalities: A comparison with hysteroscopy. *AJR* 2004; 183:1405-9.
- Matalliotakis IM, Katsikis IK, Panidis DK. Adenomyosis: What is the impact on fertility? *Curr Opin Obstet Gynecol* 2005; 17:261-4.
- Chavhan GB, Hira P, Rathod K, et al. Female genital tuberculosis: Hysterosalpingographic appearances. *Br J Radiol* 2004; 77:164-9.
- Clark TJ. Outpatient hysteroscopy and ultrasonography in the management of endometrial disease. *Curr Opin Obstet Gynecol* 2004; 16:305-11.

SINGAPORE MEDICAL COUNCIL CATEGORY 3B CME PROGRAMME
Multiple Choice Questions (Code SMJ 200704B)

	True	False
Question 1. Regarding hysterosalpingography:		
(a) Hysterosalpingography is usually carried out in the first ten days after the last menstrual period.	<input type="checkbox"/>	<input type="checkbox"/>
(b) Pregnancy is an absolute contraindication.	<input type="checkbox"/>	<input type="checkbox"/>
(c) Contrast intravasation usually results in serious adverse effects.	<input type="checkbox"/>	<input type="checkbox"/>
(d) Contrast intravasation can occur via the venous or lymphatic routes.	<input type="checkbox"/>	<input type="checkbox"/>
Question 2. Regarding congenital uterine malformation:		
(a) Arcuate uterus is the most common Mullerian duct anomaly and causes impaired fertility.	<input type="checkbox"/>	<input type="checkbox"/>
(b) A wide angle between the uterine horns on hysterosalpingography favours the diagnosis of a bicornuate uterus instead of septate uterus.	<input type="checkbox"/>	<input type="checkbox"/>
(c) Normal adult uterus has a 1:1 ratio between the uterine body and cervix.	<input type="checkbox"/>	<input type="checkbox"/>
(d) Infantile (T-shaped) uterus is associated with maternal diethylstilbestrol exposure and oestrogen deficiency.	<input type="checkbox"/>	<input type="checkbox"/>
Question 3. Regarding hysterosalpingographical diagnosis of tubal occlusion:		
(a) No free intraperitoneal spillage of contrast is always due to tubal occlusion.	<input type="checkbox"/>	<input type="checkbox"/>
(b) Tubal spasm can mimic tubal occlusion.	<input type="checkbox"/>	<input type="checkbox"/>
(c) Tubal occlusion can lead to hydrosalpinx.	<input type="checkbox"/>	<input type="checkbox"/>
(d) Fallopian tube occlusion can be secondary to previous surgery or pelvic inflammatory disease.	<input type="checkbox"/>	<input type="checkbox"/>
Question 4. Regarding pathological findings demonstrated on hysterosalpingography:		
(a) Spillage of contrast from the fallopian tube excludes the diagnosis of peritubal adhesion.	<input type="checkbox"/>	<input type="checkbox"/>
(b) Subserosal and intramural leiomyomas are usually visualised on hysterosalpingography.	<input type="checkbox"/>	<input type="checkbox"/>
(c) Severe form of uterine cavity adhesions (Asherman's syndrome) can cause amenorrhoea and infertility.	<input type="checkbox"/>	<input type="checkbox"/>
(d) Severe adhesions of endometrial cavity and calcified pelvic lymph nodes are indicative of endometrial tuberculosis.	<input type="checkbox"/>	<input type="checkbox"/>
Question 5. Regarding the diagnostic usage and capability of hysterosalpingography:		
(a) Ovaries are visualised during hysterosalpingography.	<input type="checkbox"/>	<input type="checkbox"/>
(b) Hysterosalpingography is the modality of choice for investigation of congenital uterine malformation.	<input type="checkbox"/>	<input type="checkbox"/>
(c) Evaluation of patency of fallopian tube is usually the main purpose for carrying out hysterosalpingography.	<input type="checkbox"/>	<input type="checkbox"/>
(d) Hysterosalpingography is the modality of choice for evaluation of endometrial polyp and adenomyosis.	<input type="checkbox"/>	<input type="checkbox"/>

Doctor's particulars:

Name in full: _____

MCR number: _____ Specialty: _____

Email address: _____

SUBMISSION INSTRUCTIONS:

(1) Log on at the SMJ website: www.sma.org.sg/cme/smj and select the appropriate set of questions. (2) Select your answers and provide your name, email address and MCR number. Click on "Submit answers" to submit.

RESULTS:

(1) Answers will be published in the SMJ June 2007 issue. (2) The MCR numbers of successful candidates will be posted online at www.sma.org.sg/cme/smj by 15 June 2007. (3) All online submissions will receive an automatic email acknowledgment. (4) Passing mark is 60%. No mark will be deducted for incorrect answers. (5) The SMJ editorial office will submit the list of successful candidates to the Singapore Medical Council.

Deadline for submission: (April 2007 SMJ 3B CME programme): 12 noon, 25 May 2007