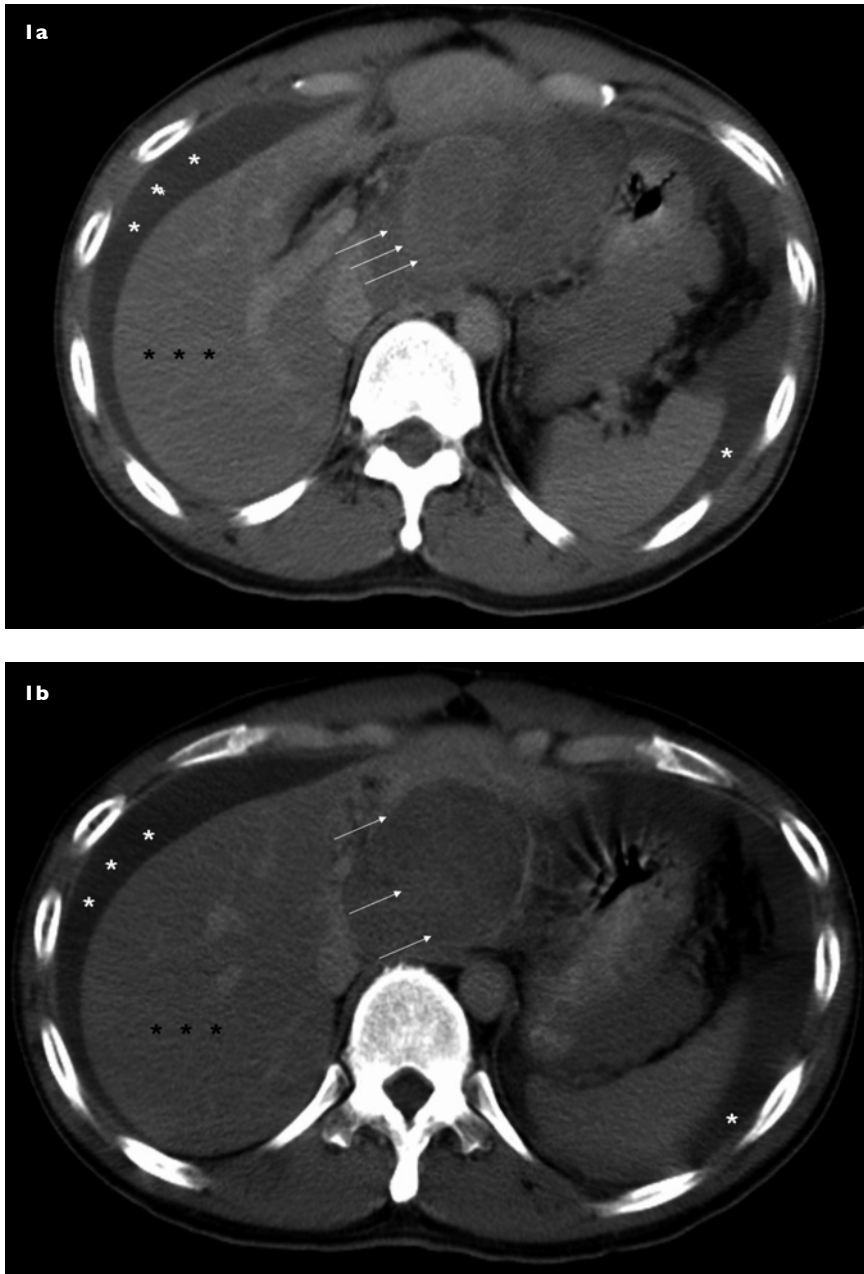


**CME Article**

# Clinics in diagnostic imaging (II6)

Pan J Y, Seto K Y, Wai C T



**Fig. 1 (a & b)** Axial CT images of the abdomen taken during the portal venous phase.

**CASE PRESENTATION**

A 37-year-old Chinese man with chronic hepatitis B infection, but who frequently defaulted follow-up, was admitted for sudden onset of severe epigastric pain, associated with vomiting and constipation. Examination

revealed hypotension, and a tender and guarded epigastrium. Urgent computed tomography (CT) of the abdomen was performed (Fig. 1). What does the CT show? What is the diagnosis and subsequent management?

Department of  
Medicine,  
National University  
Hospital,  
5 Lower Kent Ridge  
Road,  
Singapore 119074

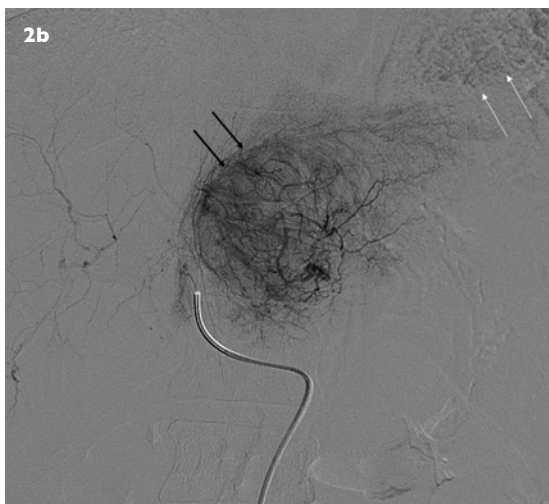
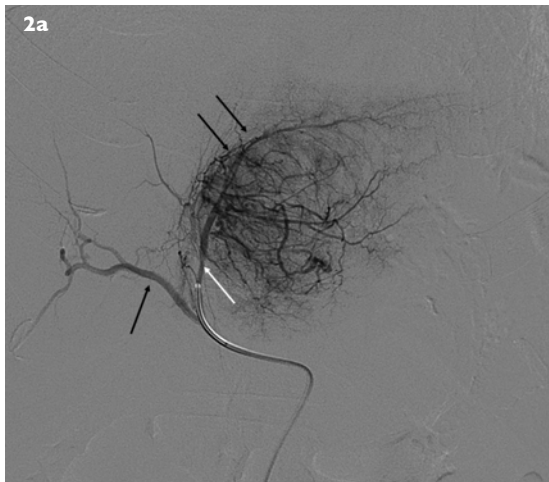
Pan JY, MBBS,  
MRCP  
Medical Officer

Wai CT, MBBS,  
MMed, MRCP  
Consultant  
Hepatologist and  
Gastroenterologist

Department of  
Diagnostic Imaging

Seto KY, MBBS,  
FRCR  
Consultant

**Correspondence to:**  
Dr Chun-Tao Wai  
Asian Centre for  
Liver Diseases and  
Transplantation,  
6A Napier Road,  
#02-37,  
Annexe Block,  
Gleneagles Hospital,  
Singapore 258500  
Tel: (65) 6476 2088  
Fax: (65) 6476 3088  
Email:  
dr\_desmond\_wai@  
yahoo.com.sg



**Fig. 2 (a)** Hepatic angiogram (early phase) shows a tumour blush (double black arrows) from the left hepatic artery (white arrow). No abnormality was noted in the right hepatic artery angiogram (single black arrow). **(b)** Hepatic angiogram (later phase) shows the tumour blush (double black arrows) from the left hepatic artery, and extravasation from the tumour into the peritoneum (double white arrows). No tumour blush was noted in the right hepatic angiogram (single black arrow).

### IMAGE INTERPRETATION

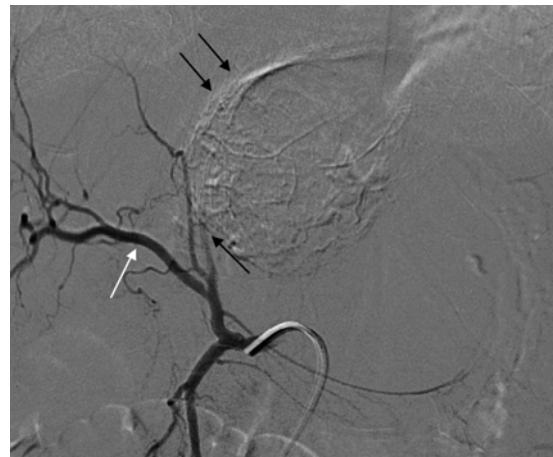
CT of the abdomen (Fig. 1) showed a heterogeneously-enhancing nodular soft tissue mass involving the left lobe of the liver, measuring approximately 60 mm × 52 mm in its maximum diameter (triple white arrows). This was suspicious of hepatocellular carcinoma (HCC). There was marked intraperitoneal fluid (white asterisks) around the liver and spleen, extending to the pelvis. No focal lesion was noted in the right lobe (black asterisks).

### DIAGNOSIS

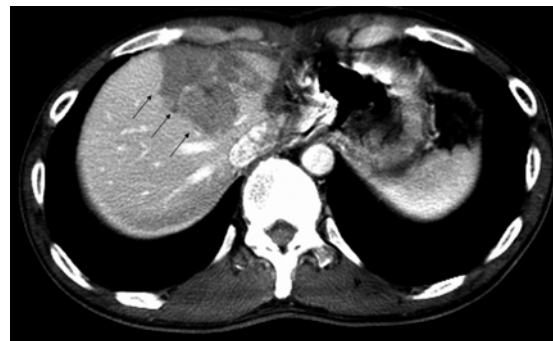Ruptured hepatocellular carcinoma.

### CLINICAL COURSE

The patient's alpha-fetoprotein (AFP) level was markedly elevated at 43,000 (normal < 15) µg/L, liver



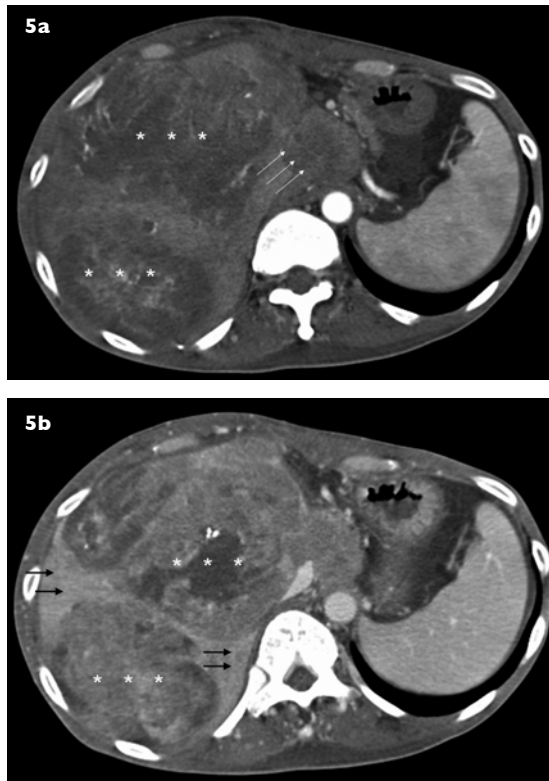
**Fig. 3** Hepatic angiogram shows successful gelfoam embolisation of the left lobe tumour. There was abrupt termination of the left hepatic artery (single black arrow), adjacent to an area of embolised tumour (double black arrows). There was no tumour blush from tributaries of the right hepatic artery (white arrow).



**Fig. 4** CT of the abdomen done two months post-surgery shows new lesions in the right lobe of the liver during portal venous phase (triple black arrows).

panel showed mild elevation of transaminases with both alanine transaminase and aspartate transaminase at 39 (normal < 35) U/L, but albumin and bilirubin levels were normal. His electrocardiogram, acute coronary screen, and serum amylase were normal. This patient had a known history of HBeAg positive chronic hepatitis B infection with recurrent episodes of acute exacerbation since year 2000. He was initially treated with lamivudine since 2000, with good initial virological and biochemical response. However, he developed lamivudine resistance in 2004, with rtM204I mutation in the hepatitis B virus, and was switched to adefovir therapy since. However, due to work commitment, he was non-compliant on follow-up. His last abdominal ultrasonography (US) that was done a year ago was normal.

During his acute presentation, he was first resuscitated with intravenous fluid. An urgent hepatic angiogram showed a tumour blush in the left lobe of the liver with contrast extravasation, consistent with the diagnosis of ruptured HCC (Fig. 2). The left hepatic artery was



**Fig. 5** Follow-up axial CT of the abdomen done five months after surgery and two months after TACE. **(a)** Arterial phase image shows multifocal recurrence in the right lobe and the caudate lobe (triple white arrows). Arterial enhancement is marked by white asterisks. **(b)** Portal venous phase image shows multifocal HCC recurrence in the right lobe. Portal venous washout is marked by white asterisks. Most of the liver was infiltrated with HCC, with little normal liver left (black arrows).

then selectively catheterised, and embolisation with gelfoam was performed. No tumour blush was seen in the right hepatic angiogram. Successful embolisation was confirmed on the subsequent repeat left hepatic angiogram (Fig. 3).

Semi-elective hepatectomy was scheduled two days later. Intraoperatively, a 5 cm × 6 cm exophytic tumour was seen arising from segment III (left lobe), bordering the falciform ligament, with rupture into the lesser sac and peritoneum. There was about one litre of blood with blood clots in the peritoneal cavity. No tumour was noted in the right lobe of liver. Subsequent histopathology of the resected specimen showed a moderately-differentiated HCC with a 2-mm margin in a non-cirrhotic liver. HCC tumour cells were seen in the peritoneal fluid and blood clots. The patient recovered well and was discharged on the seventh postoperative day, with his AFP dropping to 13,726 µg/L at the time of his discharge.

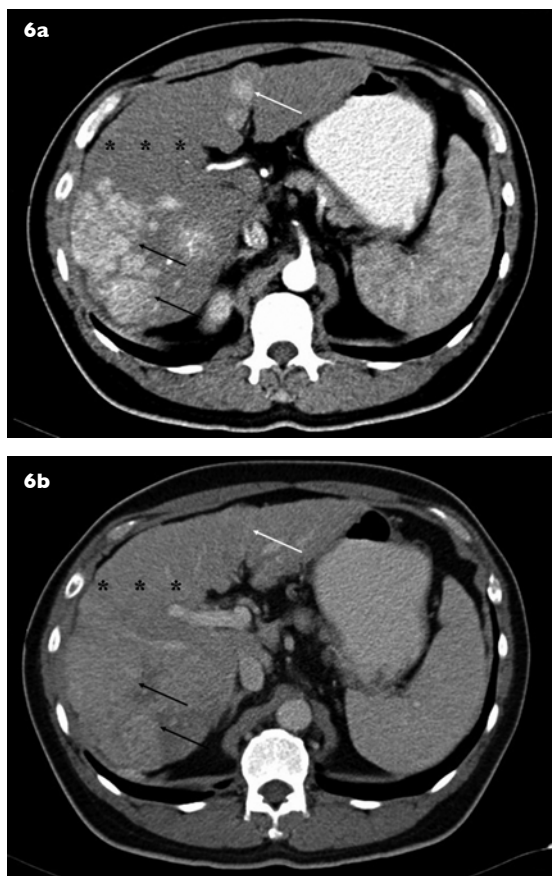
However, follow-up CT of the abdomen done two months later showed new hypodense lesions in the right lobe of the liver (Fig. 4). His AFP level also increased to 22,835 µg/L. Two sessions of transarterial

chemoembolisation (TACE), each with 100 mg of adriamycin, mixed with gel-foam and lipiodol administered selectively through the right hepatic angiogram were performed over the next three weeks. Despite the TACE treatment, his AFP continued to rise to 166,500 µg/L two weeks after his second TACE. There was also a new development of right-sided pleural effusion, and aggressive recurrence in the right lobe two months after TACE (Fig. 5). He eventually passed away five months after his initial presentation.

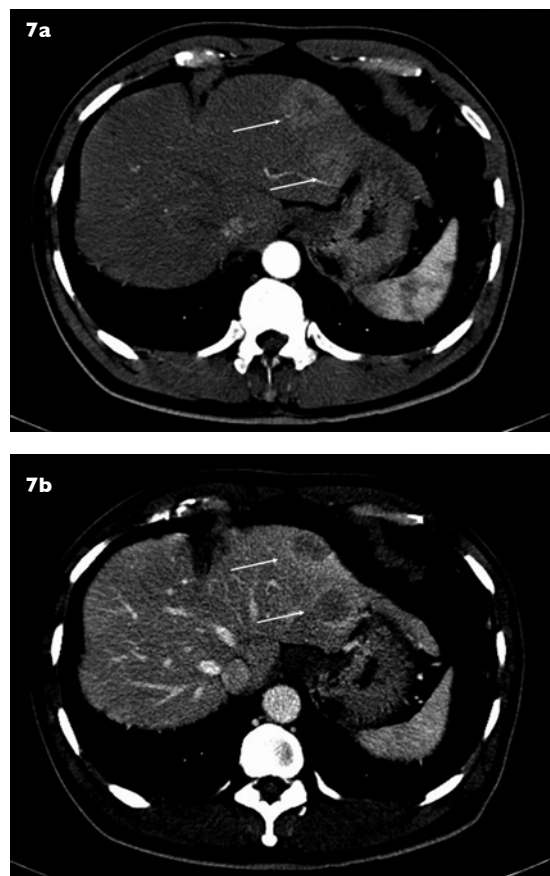## DISCUSSION

The mechanism of HCC rupture is presumed to be venous congestion, caused by tumour invading and obstructing the hepatic vein; central necrosis from rapid tumour growth; coagulopathy and thrombocytopenia; slight trauma or diaphragmatic compression.<sup>(1,2)</sup> The clinical spectrum of intra-abdominal rupture is protean, ranging from slight abdominal pain, haemorrhagic shock requiring massive transfusion, to liver failure. Early mortality for a spontaneously-ruptured HCC differs markedly, depending on the residual liver function, pre-rupture disease state, and severity of intra-abdominal bleeding.<sup>(3)</sup> The immediate management of a ruptured HCC is fluid resuscitation, with correction of coagulopathy or thrombocytopenia as appropriate, and blood transfusion. It should be followed closely by confirming the diagnosis, and staged management for the HCC. In patients who are haemodynamically unstable, transarterial embolisation (TAE) should be performed urgently to secure haemostasis. Emergency surgical haemostasis is indicated for patients who fail TAE or develop features of peritonitis. Ligation of the ipsilateral or common hepatic artery, suturing of the bleeding tumour, perihepatic packing, or laparoscopic haemostasis are some of the surgical treatment modalities.<sup>(1-4)</sup> After stabilisation, patients should be evaluated for definitive treatment. Depending on liver function, Child-Pugh's score, stage of the tumour and patients' overall performance status, therapies like hepatic resection, TACE, radiofrequency ablation or systemic chemotherapy, could be selected.

Prognosis of patients with ruptured HCC is controversial. While some studies suggested that a history of spontaneous rupture would not affect survival results after curative resection of HCC, a more recent study from Hong Kong showed otherwise.<sup>(3,5,6)</sup> It was postulated that intraperitoneal tumour cell spillage during rupture could be responsible for the high incidence of extrahepatic intraperitoneal recurrence, leading to a worse prognosis.<sup>(7)</sup> In one series from Hong Kong, which evaluated long-term survival of 63 patients with ruptured HCC treated with either hepatectomy or TACE, median survival were 25.7 months and 9.7 months for the hepatectomy and TACE groups, respectively.<sup>(3)</sup> In another series from Taiwan,



**Fig. 6** Axial CT of the abdomen of a 52-year-old man with cirrhosis from chronic hepatitis B infection and elevated AFP of 823 ng/ml. **(a)** Arterial phase image shows a large right HCC with arterial enhancement (black arrows), and a metachronous lesion in the left lobe (white arrow). Non-cancerous liver parenchyma (asterisks) appears relatively less perfused, or “darker”, as compared to the cancerous areas. **(b)** Portal venous phase image shows washout in the portal venous phase in both the left lobe (white arrow) and right lobe (black arrows) lesion. During the portal venous phase, the non-cancerous liver parenchyma (asterisks) appears relatively more perfused, or “brighter”, as compared to the cancerous areas. These vascular characteristics are typical of HCC.



**Fig. 7** Axial CT of the abdomen in a 55-year-old man with no history of chronic viral hepatitis, nor clinical evidence of cirrhosis. **(a)** Arterial phase image shows two arterially-enhancing lesions in the left lobe (white arrows). Note the adjacent liver parenchyma appears relatively underperfused during the arterial phase, as liver parenchyma is mainly perfused by the portal vein. **(b)** Portal venous phase image shows washout, with the two left lobe lesions (white arrows) appearing relatively underperfused in this phase. The adjacent liver parenchyma now appears more perfused. However, as this patient was non-cirrhotic, did not have chronic viral hepatitis, and had normal AFP levels, HCC was deemed less likely. Biopsy of the lesion was done, which showed metastatic carcinoid tumours.

which evaluated 60 patients with ruptured HCC treated with resection, one-, three-, and five-year survival rates were 54%, 35%, and 21%, respectively.<sup>(6)</sup> We are unsure of the reasons for the rapid progression of HCC in our patient, though we speculate that it could possibly be due to tumour spillage from intraperitoneal rupture.

The American Association for the Study of Liver Diseases and the Singapore Ministry of Health recommend that surveillance be carried out in all hepatitis B carriers with cirrhosis, a family history of HCC, Asian men older than 40 years of age and Asian women older than 50 years of age, and those with high hepatitis B viral DNA titres or ongoing hepatic inflammation.<sup>(8,9)</sup> Recommended screening tests are AFP level measurements and hepatic US, with a surveillance interval of six to 12 months. Although HCC diagnosed at screening have a higher

chance of receiving curative treatment and better survival than symptomatic HCC, local studies have showed that compliance of HCC screening is poor at only 33%.<sup>(10,11)</sup>

HCC is usually diagnosed clinically, based on either histology or imaging studies. Imaging characteristics are based on the differential vascular features between HCC and non-cancerous liver parenchyma.<sup>(12)</sup> Liver parenchyma is mainly perfused by the portal vein, while HCC tend to be perfused mainly by the hepatic artery. This differentiating vascular feature allows HCC to be differentiated from non-cancerous liver parenchyma by multi-phasic CT or magnetic resonance imaging, where HCC typically appears as an enhancing nodule during the arterial phase, but become “washed-out”, or underperfused during the portal venous phase. On the contrary, non-cancerous liver parenchyma appears

underperfused compared to an HCC nodule during the arterial phase, but become better perfused during the portal venous phase (Fig. 6). However, physicians have to be aware that other lesions besides HCC could have a similar vascular pattern as HCC, such as arteriovenous shunts, which are commonly found in cirrhotics, or hypervascular metastasis, which may show similar patterns. In lesions with equivocal vascular pattern or in a non-cirrhotic setting, a biopsy may be required to confirm the diagnosis of HCC (Fig. 7).<sup>(9)</sup>

Hepatitis B carriers with cirrhosis, high viral titres or active disease, should have regular liver function tests, AFP levels and abdominal imaging performed to survey for complications of chronic hepatitis B. Compliance to follow-up is essential to ensure that diagnosis of HCC is made at an early stage where therapy is curative. Ruptured HCC is a feared life-threatening complication. There should be a high index of suspicion in patients with cirrhosis or chronic hepatitis presenting with unexplained severe abdominal pain, drop in haemoglobin level, or hypotension. Timely resuscitation with fluids and blood products followed by angiographical embolisation are the main modalities of acute treatment.

#### ABSTRACT

**A 37-year-old Chinese man with chronic hepatitis B, who frequently defaulted past follow-up appointments, was admitted for acute abdomen and shock. Computed tomography of the abdomen revealed a ruptured hepatocellular carcinoma involving the left lobe. After fluid resuscitation, gelfoam embolisation was performed to arrest the bleeding, followed by segmental resection of the hepatic lesion. There was aggressive recurrence following left segmental hepatectomy, and despite two**

**courses of transarterial chemoembolisation, the patient died of local and pulmonary recurrences five months after his initial presentation. The management of hepatocellular carcinoma rupture is discussed.**

**Keywords: chemoembolisation, hepatectomy, hepatitis B, hepatocellular carcinoma, liver tumour, ruptured hepatocellular carcinoma**

*Singapore Med J 2007; 48(5):469-474*

#### REFERENCES

1. Nakashima T, Kojiro M. Pathologic characteristics of hepatocellular carcinoma. *Semin Liver Dis* 1986; 6:259-66.
2. Sato Y, Fujiwara K, Furui S, et al. Benefit of transcatheter arterial embolization for ruptured hepatocellular carcinoma complicating liver cirrhosis. *Gastroenterology* 1985; 89:157-9.
3. Liu CL, Fan ST, Lo CM, et al. Management of spontaneous rupture of hepatocellular carcinoma: single-center experience. *J Clin Oncol* 2001; 19:3725-32.
4. Lang BH, Poon RT, Fan ST, Wong J. Influence of laparoscopy on postoperative recurrence and survival in patients with ruptured hepatocellular carcinoma undergoing hepatic resection. *Br J Surg* 2004; 91:444-9.
5. Lai EC, Ng IO, Ng MM, et al. Long-term results of resection for large hepatocellular carcinoma: a multivariate analysis of clinicopathological features. *Hepatology* 1990; 11:815-8.
6. Yeh CN, Lee WC, Jeng LB, Chen MF, Yu MC. Spontaneous tumour rupture and prognosis in patients with hepatocellular carcinoma. *Br J Surg* 2002; 89:1125-9.
7. Yunoki Y, Takeuchi H, Makino Y, et al. Intraperitoneal seeding of ruptured hepatocellular carcinoma: case report. *Abdom Imaging* 1999; 24:398-400.
8. Bruix J, Sherman M; Practice Guidelines Committee, American Association for the Study of Liver Diseases. Management of hepatocellular carcinoma. *Hepatology* 2005; 42:1208-36. Comment in: *Hepatology* 2006; 43:373.
9. Singapore Ministry of Health. Clinical Practice Guidelines: Chronic Hepatitis B. 4/2003. Available at: [www.moh.gov.sg/cmaweb/attachments/publication/cpg\\_hep\\_b.pdf](http://www.moh.gov.sg/cmaweb/attachments/publication/cpg_hep_b.pdf). Accessed August 28, 2006.
10. Wai CT, Mak B, Chua W, Lim SG. The majority of hepatitis B carriers are not on regular surveillance in Singapore. *Singapore Med J* 2004; 45:423-6.
11. Wai CT, Wong ML, Ng S, et al. Utility of the Health Belief Model in predicting compliance of screening in patients with chronic hepatitis B. *Aliment Pharmacol Ther* 2005; 21:1255-62.
12. Kim TK, Jang HJ, Wilson SR. Imaging diagnosis of hepatocellular carcinoma with differentiation from other pathology. *Clin Liver Dis* 2005; 9:253-79.

**SINGAPORE MEDICAL COUNCIL CATEGORY 3B CME PROGRAMME**  
**Multiple Choice Questions (Code SMJ 200705A)**

	True	False
<b>Question 1.</b> The following are high-risk groups in which screening of hepatocellular carcinoma should be carried out:		
(a) Patients with chronic hepatitis B.	<input type="checkbox"/>	<input type="checkbox"/>
(b) Patients with chronic hepatitis C.	<input type="checkbox"/>	<input type="checkbox"/>
(c) Patients with stage II primary biliary cirrhosis.	<input type="checkbox"/>	<input type="checkbox"/>
(d) Patients with non-alcoholic fatty liver disease.	<input type="checkbox"/>	<input type="checkbox"/>
<b>Question 2.</b> In cirrhotic patients with elevated alpha-fetoprotein level, diagnosis of hepatocellular carcinoma can be confirmed by the following investigations:		
(a) Real-time ultrasonography.	<input type="checkbox"/>	<input type="checkbox"/>
(b) Magnetic resonance imaging.	<input type="checkbox"/>	<input type="checkbox"/>
(c) Monophasic CT.	<input type="checkbox"/>	<input type="checkbox"/>
(d) Hepatic angiogram.	<input type="checkbox"/>	<input type="checkbox"/>
<b>Question 3.</b> The following are potential diagnoses in a 50-year-old male patient admitted for upper acute abdominal pain:		
(a) Acute pancreatitis.	<input type="checkbox"/>	<input type="checkbox"/>
(b) Acute myocardial infarct.	<input type="checkbox"/>	<input type="checkbox"/>
(c) Pneumothorax.	<input type="checkbox"/>	<input type="checkbox"/>
(d) Ruptured abdominal viscus.	<input type="checkbox"/>	<input type="checkbox"/>
<b>Question 4.</b> Features of hepatocellular carcinoma, namely, arterial enhancement and portal venous washout, on CT can also be found in the following conditions:		
(a) Haemangioma.	<input type="checkbox"/>	<input type="checkbox"/>
(b) Hypervascular metastasis.	<input type="checkbox"/>	<input type="checkbox"/>
(c) Arteriovenous shunts in the liver.	<input type="checkbox"/>	<input type="checkbox"/>
(d) Colonic carcinoma metastasis.	<input type="checkbox"/>	<input type="checkbox"/>
<b>Question 5.</b> Treatment of hepatocellular carcinoma includes the following:		
(a) Liver transplantation.	<input type="checkbox"/>	<input type="checkbox"/>
(b) Transarterial chemoembolisation.	<input type="checkbox"/>	<input type="checkbox"/>
(c) Total hepatectomy.	<input type="checkbox"/>	<input type="checkbox"/>
(d) Percutaneous radiofrequency ablation.	<input type="checkbox"/>	<input type="checkbox"/>

---

**Doctor's particulars:**

Name in full: \_\_\_\_\_

MCR number: \_\_\_\_\_ Specialty: \_\_\_\_\_

Email address: \_\_\_\_\_

**SUBMISSION INSTRUCTIONS:**

(1) Log on at the SMJ website: [www.sma.org.sg/cme/smj](http://www.sma.org.sg/cme/smj) and select the appropriate set of questions. (2) Select your answers and provide your name, email address and MCR number. Click on "Submit answers" to submit.

**RESULTS:**

(1) Answers will be published in the SMJ July 2007 issue. (2) The MCR numbers of successful candidates will be posted online at [www.sma.org.sg/cme/smj](http://www.sma.org.sg/cme/smj) by 15 July 2007. (3) All online submissions will receive an automatic email acknowledgment. (4) Passing mark is 60%. No mark will be deducted for incorrect answers. (5) The SMJ editorial office will submit the list of successful candidates to the Singapore Medical Council.

**Deadline for submission: (May 2007 SMJ 3B CME programme): 12 noon, 25 June 2007**