

Clinically-relevant variations of the carotid arterial system

Anu V R, Pai M M, Rajalakshmi R, Latha V P, Rajanigandha V, D'Costa S

ABSTRACT

Introduction: Developmental anomalies in the origin and branching pattern of the external carotid artery are not common. The level of the bifurcation of the common carotid artery and also the variations in the origin/branching pattern of the external carotid artery are well known and documented.

Methods: The variations in the level of bifurcation of the common carotid artery and the branching pattern of the external carotid artery were studied on 95 cadavers (52 male and 43 female). The common, external and internal carotid arteries were dissected on both sides. The level of carotid bifurcation was determined by comparison with the cervical vertebrae. Branching patterns of the carotid arteries were examined.

Results: Apart from the textbook description of the arteries, we came across several interesting variations. The bifurcation level of the common carotid artery was determined to be 50 percent at the C3 level, 40 percent at the C4 level and ten percent at the C2 level on the right side, and 55 percent at the C3 level, 35 percent at the C4 level, one percent at the C5 level and nine percent at the C2 level on the left side.

Conclusion: Anatomical knowledge of the origin, course, and branching pattern of the external carotid artery, as well as the level of bifurcation of the common carotid artery, will be useful to surgeons when ligating the vessels in the head and neck regions during surgery and to avoid unnecessary complications during carotid endarterectomy.

Keywords: carotid artery variants, carotid endarterectomy, common carotid artery,

external carotid artery

Singapore Med J 2007; 48(6):566–569

INTRODUCTION

The common carotid arteries (CCA) are the largest bilateral arteries of the head and neck. The right CCA is exclusively cervical and originates from the brachiocephalic trunk. The left CCA arises directly from the aortic arch immediately posterolateral to the brachiocephalic trunk. The CCAs of both sides divide at the upper border of the thyroid cartilage at intervertebral disc level between the third and fourth cervical vertebrae into external and internal carotid arteries.⁽¹⁾ The external carotid artery (ECA) extends from the level of upper border of the lamina of thyroid cartilage to a point behind the neck of the mandible, providing altogether eight branches of which the superficial temporal and maxillary are the two terminal branches.⁽²⁾ The CCAs may bifurcate higher or lower than the usual levels; a high bifurcation is more common. The bifurcation can occur as high as the hyoid bone or even the styloid process, or as low as the cricoid cartilage or within 3.7 cm of its origin. Variations are of importance for surgical approaches in the head and neck region.⁽³⁾ It is essential to be aware of anatomical vascular variations, to ensure these anomalies are not overlooked in the differential diagnosis. The variation in the present case was studied and compared with those reported before.

METHODS

During dissection of the head and neck regions by undergraduate students for the past eight years, 95 cadavers of both sexes (52 male and 43 female) have been observed for any variations in the carotid arterial system. Bilateral CCAs, ECAs and internal carotid arteries were dissected. The level of carotid bifurcation was determined by comparison with the cervical vertebrae. Branching patterns of the carotid arteries were examined.

RESULTS

The present study showed that the CCA bifurcated usually at the level of the C3 vertebra (50% right side and 55% left side) and C4 vertebra (40% right side and 35% left side). However, in 10% of the cases, the bifurcation of the CCA was at the level of C2, and in one case (1%), it was at

Department of Anatomy, Kasturba Medical College, Mangalore, Karnataka 575004, India

Anu VR, MSc, PhD
Senior Lecturer

Pai MM, MBBS, MD
Assistant Professor

Rajalakshmi R, MSc
Senior Lecturer

Latha VP, MBBS, MS
Professor

Rajanigandha V,
MBBS, MD
Assistant Professor

D'Costa S, MSc
Senior Lecturer

Correspondence to:
Dr Anu V Ranade
Tel: (91) 988 611 7221
Fax: (91) 824 242 8183
Email: anuranade@gmail.com

the C5 level on the left side. The branching pattern of the ECA showed many variations, of which a few interesting variations are enumerated below.

Case 1: In this case the level of bifurcation of the CCA was normal. On the right side, the superior thyroid artery

was seen arising from the CCA. The lingual artery and the maxillary artery were highly looped near their origin. In addition to the named branches, the ECA also gave two glandular branches which supplied the parotid gland (Fig. 1).

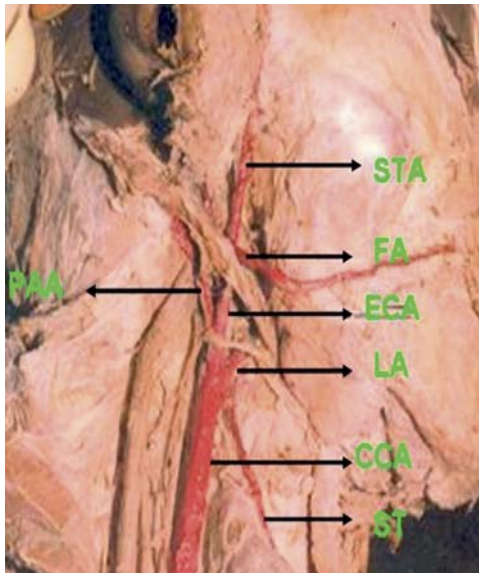


Fig. 1 Photograph of the right side of the face shows the course of the facial artery. STA: Superficial temporal artery; FA: Facial artery; ECA: External carotid artery; LA: Lingual artery; ST: Superior thyroid artery; CCA: Common carotid artery; PAA: Posterior auricular artery.

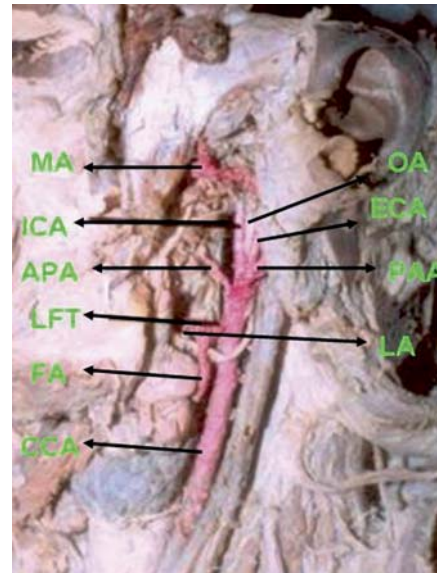


Fig. 2 Photograph of the left side of the face shows the absence of superior thyroid artery. MA: Maxillary artery; FA: Facial artery; ECA: External carotid artery; LA: Lingual artery; CCA: Common carotid artery; PAA: Posterior auricular artery; OA: Occipital artery; ICA: Internal carotid artery; APA: Ascending pharyngeal artery; LFT: Linguofacial trunk.

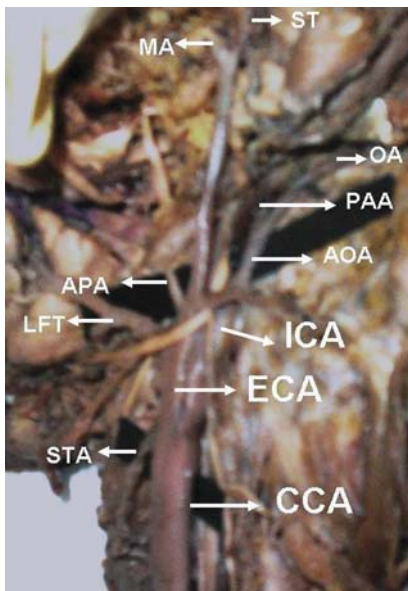


Fig. 3 Photograph of the left side of the face and neck shows the course of the external carotid artery. ST: Superficial temporal artery; MA: Maxillary artery; OA: Occipital artery; PAA: Posterior auricular artery; AOA: Auriculo-occipital artery; APA: Ascending pharyngeal artery; LFT: Linguofacial trunk; STA: Superior thyroid artery; ECA: External carotid artery; CCA: Common carotid artery; ICA: Internal carotid artery.

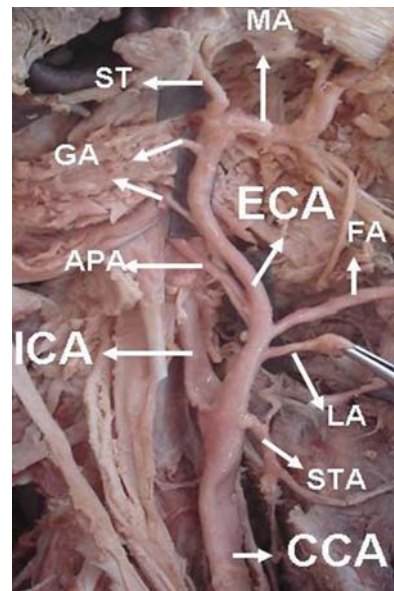


Fig. 4 Photograph of the right side of the face and neck shows the course of the external carotid artery. ST: Superficial temporal artery; MA: Maxillary artery; APA: Ascending pharyngeal artery; FA: Facial artery; LA: Lingual artery; STA: Superior thyroid artery; GA: Glandular arteries to the parotid gland; ECA: External carotid artery; CCA: Common carotid artery; ICA: Internal carotid artery.

Case 2: The level of bifurcation of the CCA was at the C2 vertebral level. The right lingual artery and superior thyroid artery arose from the CCA. One of the notable variations was in the origin and course of the facial artery. The right facial artery arose from the ECA just above the angle of the mandible and passed directly on to the face crossing the posterior border of the mandibular ramus and along the posterior pole of the superficial part of the submandibular salivary gland. On the left side, the superior thyroid artery was absent and a common linguofacial trunk was seen arising from the CCA (Fig. 2). The course of the facial artery on the left side was normal and the occipital, ascending pharyngeal and posterior auricular arose from the ECA at the level of bifurcation of CCA.

Case 3: The CCA bifurcated at the level of C3. On the left side, the superior thyroid artery was arising just below the bifurcation of the CCA and also showed a long curved course. The occipital and posterior auricular arteries arose as a common trunk from the ECA and gave a muscular branch to the sternocleidomastoid. The ECA gave the linguofacial trunk which divided into the lingual and facial arteries (Fig. 3).

Case 4: The bifurcation of the CCA and branching pattern of the ECA were normal, except for the left superior thyroid artery which arose as a branch of the CCA just before it bifurcated (Fig. 4).

DISCUSSION

Among variations in the level of bifurcation of the CCA as reported in the past, the most common was at the level of the hyoid bone⁽⁴⁾ or just below the inferior border of the ramus of the mandible in 63% of the cases, right and left sides combined.⁽⁵⁾ According to Gluncic et al, the right CCA bifurcated at the level between the second and third cervical vertebrae, giving rise to the ascending pharyngeal artery just below the bifurcation.⁽⁶⁾ An unusual case of peripheral hypoglossal nerve palsy caused by the lateral position of the ECA and an abnormally high carotid bifurcation has been reported by Ueda et al.⁽⁷⁾ According to Bergman et al, the ECA may be absent unilaterally or bilaterally.⁽⁸⁾ In the present study, the level of bifurcation of CCA was usually at the C3 or C4 level. Only in 10% of the cases, the bifurcation level was higher at the C2 level, and very rarely at the lower C5 level (1%). Surgeons performing procedures in this area should be aware of the various levels of bifurcation of CCA, so that inadvertent vascular injuries could be prevented.

In a study by Prendes et al, an anatomic variant for the position of the ECA was noted in 5.3% of patients studied by Doppler ultrasonography and contrast angiography.⁽⁹⁾ The ECA was lateral to and posterior to the internal carotid artery in these patients. Consideration of this important variation is mandatory for accurate ultrasonographical correlation. In the studies on origin anomalies, it was

reported by Koneko et al that the superior thyroid, lingual and facial arteries commonly originated from the CCA.⁽¹⁰⁾ However, the posterior auricular, maxillary and superficial temporal arteries formed a common trunk. They also observed that the occipital artery arose from the internal carotid artery together with the sternocleidomastoid branch. In his angiographical studies, Takenoshita reported that the superior thyroid, lingual and facial arteries commonly originated from the ECA while the maxillary, superficial temporal and occipital arteries arose from the internal carotid artery.⁽¹⁾ Zumre et al observed a linguofacial trunk in 20% of the cases, a thyrolingual trunk in 2.5%, a thyrolinguofacial trunk in 2.5%, and an occipitoauricular trunk in 12.5% of the cases in the human foetuses he studied.⁽¹¹⁾ Moreover, the right ECA branched directly at its origin into the superior thyroid, lingual and occipital arteries, and the distal part of the external carotid artery.⁽⁶⁾ Eretter et al reported an anomaly of the carotid system having bilateral maxillofacial trunks.⁽¹²⁾ According to Anil et al, the right ascending pharyngeal artery was observed arising from the carotid bifurcation instead of the posterior aspect of the ECA.⁽¹³⁾ The clinically-relevant variations to be noted in the present study are the high origin and anomalous course of the facial artery, superior thyroid artery arising as a branch of CCA, and direct glandular branches to the parotid gland.

The anomalous course of the lingual and facial arteries, as well as the variations in the origin of the superior thyroid artery, could be of interest to head and neck surgeons. Normally, the CCA does not give any branches except the external and internal carotid arteries.⁽²⁾ Therefore, the knowledge of such variations is vital for the exact identification of the neck vessels during surgery to avoid a fatal mix-up with the internal carotid artery.⁽¹⁴⁾ A thorough knowledge of vascular anatomy is essential for the understanding and interpretation of diagnostic and interventional vascular procedures, as well as performing surgical procedures. The analysis of angiographies is still the best way to understand normal vascular anatomy and to confirm minute anatomical variations.

REFERENCES

1. Takenoshita H. [Case of hypoplasia of the internal carotid artery associated with persistent primitive hypoglossal artery]. *Kaibogaku Zasshi* 1983; 58:533-50. Japanese.
2. Dutta AK. *Essentials of human anatomy In: Head and Neck*. 2nd ed. Calcutta: Current Books International, 1994:127-32.
3. Poynter CWN. *Congenital anomalies of the arteries and veins of the human body with bibliography*. Lincoln: The University Studies of the University of Nebraska, 1992; 22:1-106.
4. Bannister LH, Berry MM, Cellins P, et al. *Gray's anatomy. The Anatomical Basis of Medicine and Surgery*. 38th ed. New York: ELBS Churchill Livingstone, 1995:1513-4.
5. Anson BV, Chester BM. *Lateral Regions of the Head and Neck in Surgical Anatomy*. 5th ed. Philadelphia: WB Saunders, 1971: 287-313.
6. Gluncic V, Petanjek Z, Marusic A, Gluncic I. High bifurcation of common carotid artery, anomalous origin of ascending pharyngeal artery and anomalous branching pattern of external carotid artery.

- Surg Radiol Anat 2001; 23:123-5.
7. Ueda S, Kohyama Y, Takase K. Peripheral hypoglossal nerve palsy caused by lateral position of the external carotid artery and an abnormally high position of bifurcation of the external and internal carotid arteries – a case report. *Stroke* 1984; 15:736-9.
 8. Bergman RA, Thompson SA, Afifi AK, Saadeh FA. *Compendium of Human Anatomic Variations*. Baltimore: Urban and Schwarzenberg, 1988: 65.
 9. Prendes JL, McKinney WM, Buonanno FS, Jones AM. Anatomic variations of the carotid bifurcation affecting Doppler scan interpretation. *J Clin Ultrasound* 1980; 8:147-50.
 10. Kaneko K, Akita M, Murata E, Imai M, Sowa K. Unilateral anomalous left common carotid artery; a case report. *Ann Anat* 1996; 178:477-80.
 11. Zumre O, Salbacak A, Cicekcibasi AE, Tuncer I, Seker M. Investigation of the bifurcation level of the common carotid artery and variations of the branches of the external carotid artery in human fetuses. *Ann Anat* 2005; 187:361-9.
 12. Eretter K, Lieber MN, Krammar EB, Mayr RA. A bilateral maxillofacial trunk in man: an extraordinary anomaly of the carotid system of arteries. *Acta Anat (Basel)* 1991; 141:206-11.
 13. Anil A, Turgut HB, Peker T, Pelin C. Variations of the branches of the external carotid artery. *Gazi Med J* 2000; 11:81-3.
 14. Issing PR, Kempf HG, Lenarz T. [A clinically relevant variation of the superior thyroid artery]. *Laryngorhinootologie*. 1994; 73:536-7. German.

THE 2ND EDITION OF THE **BEDSIDE ICU HANDBOOK** IS NOW AVAILABLE!

Comes in 21 chapters by 56 authors with 191 topics on the essentials of many diagnostic and therapeutic principles currently practised in Singapore and the four intensive care units in Tan Tock Seng Hospital.

Now sold at S\$30 per copy from TTSH The Health Shoppe, ResearchBooks Asia Pte Ltd, Yunan Bookstore and other leading medical bookstores.

For enquiries on bulk (5 copies & above) and overseas purchase, please e-mail ttsh_icuhandbook@ttsh.com.sg or call (65) 6357-7772.

