

Gastric variceal bleed in a patient without liver cirrhosis: an unusual cause of haematemesis

Ismail F W, Mumtaz K, Chawla T, Jafri W

ABSTRACT

Tumours of the pancreas presenting as haematemesis are rare entities, with scarce documentation in literature. We report a 50-year-old woman who presented with haematemesis secondary to gastric fundal variceal bleeding due to splenic vein occlusion by a large mucinous cystadenoma of the pancreas. We also review the literature pertaining to unusual pathologies presenting as haematemesis.

Keywords: haematemesis, mucinous cystadenoma, pancreatic tumours

Singapore Med J 2007;48(6):e171-e173

INTRODUCTION

While most of the cases of haematemesis presenting to hospitals are mainly due to oesophageal variceal or peptic ulcer, it is useful to remember that there are other rare, yet important and treatable causes of haematemesis. We report one such case and also review the literature pertaining to unusual pathologies presenting as haematemesis.

CASE REPORT

Our patient, a 50-year-old woman from the north of Pakistan, came to the emergency room with a history of four episodes of haematemesis and two episodes of melaena over the last four hours. Each episode of haematemesis was about half a cupful. She had been diagnosed with hypertension three months ago, and was taking verapamil 40 mg thrice a day along with aspirin 75 mg once a day. Apart from this, she had no medical or surgical history of note, and she had no known allergies or addictions. On examination, she was alert and oriented, with a blood pressure of 110/60 mmHg and heart rate of 96/minute. On physical examination, she was anaemic, without any jaundice, lymphadenopathy, or pedal oedema. Abdominal examination revealed a 6 cm enlarged, soft spleen palpable below the left costal margin, which was an important sign of possible portal hypertension. A digital rectal examination revealed melaena, and

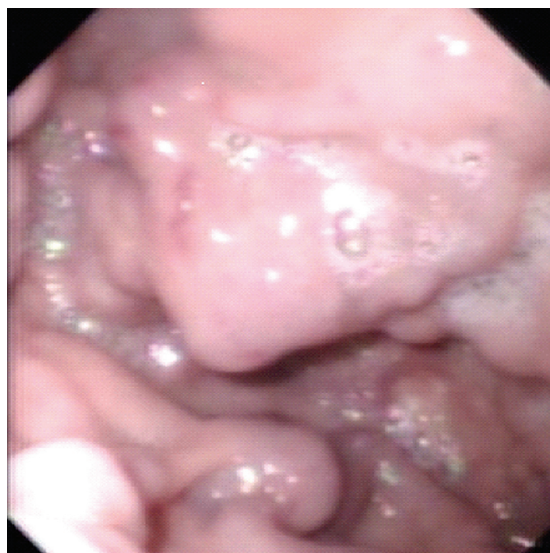

Fig. 1 Endoscopic photograph shows a large fundal varix with the red mark of recent bleed.

a nasogastric lavage demonstrated coffee ground aspirate. The rest of the systemic examination was unremarkable, and all peripheral stigmata of chronic liver disease were absent.

She had a haemoglobin level of 6.5 g/dL, white cell count of $11.6 \times 10^9/L$, and platelets were $140,000/mm^3$. Her liver function tests, including prothrombin time, were normal, but her albumin level was 3.0 g/dL. An assessment of upper gastrointestinal (GI) bleed was made, secondary to either aspirin use or oesophageal variceal bleed, keeping in mind her low platelet and albumin levels. She was resuscitated with crystalloid solutions and packed red cells. She was also started on intravenous omeprazole and octreotide infusions. Once stable, she was subjected to an oesophago-gastro-duodenoscopy (OGD) which revealed a large gastric fundal varix with a red spot, indicating the site of bleeding (Fig. 1). The rest of the OGD was unremarkable. A mixture of N-butyl cyanoacrylate 0.5 ml, diluted in 0.8 ml of lipoidal, was injected into the gastric fundal varix. The intervention was uneventful.

Department of
Medicine,
The Aga Khan
University Hospital,
Stadium Road,
Karachi,
Pakistan

Ismail FW, MBBS,
FCPS
Fellow

Mumtaz K, MBBS,
FCPS
Senior Instructor

Jafri W, MRCP,
FRCP, FACC
Professor

Department of
Surgery

Chawla T, MBBS,
FRCSG
Assistant Professor

Correspondence to:
Dr Faisal W Ismail
Tel: (92) 21 486 4671
Fax: (92) 21 493 4294
Email: faisal.ismail@
aku.edu

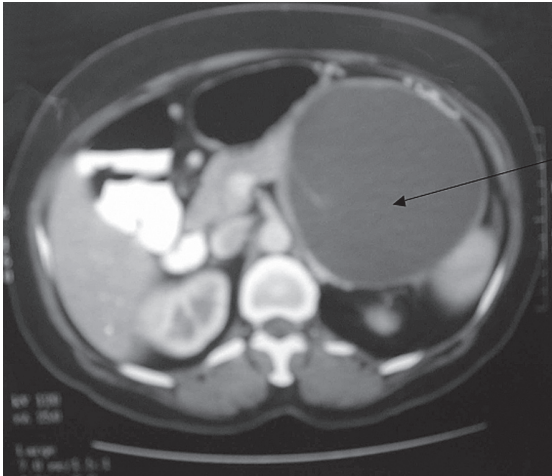


Fig. 2 Axial CT image shows a large cystic lesion in the tail of the pancreas.

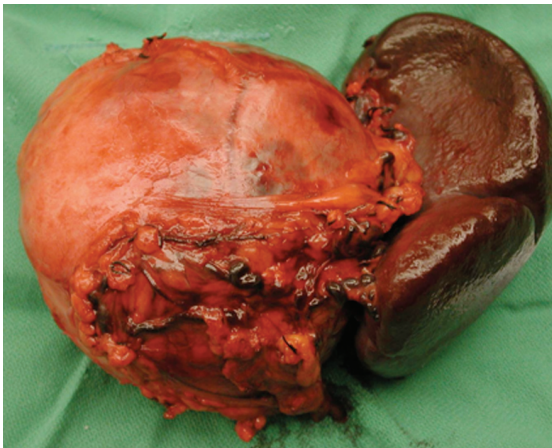


Fig. 3 Specimen photograph shows the cystic pancreatic mass and spleen.

Subsequently, her hepatitis B and C serology was confirmed to be negative. Abdominal ultrasonography (US) revealed a large cystic mass present in the tail of the pancreas, extending to the splenic hilum. Enhanced computed tomography (CT) of the abdomen confirmed the US findings of a 10 cm × 8 cm cyst, without the presence of dilated veins to suggest portal hypertension (Fig. 2). A provisional diagnosis of either hydatid cyst disease or a pancreatic cystadenoma was made. Her subsequent Echinococcus antibody titre was < 1:16, which excluded the possibility of a hydatid cyst. After a surgical review, the patient underwent surgical exploration. The peritoneal cavity was entered through a left subcostal incision, while the lesser sac was entered by dividing the gastrocolic omentum. Operative findings were a mass with cystic and solid components in the tail of the pancreas,

which was compressing the splenic vein. A distal pancreatectomy and splenectomy were performed. (Fig. 3). The patient had an uneventful postoperative course. Histopathology confirmed the diagnosis of a benign mucinous cystadenoma. She has had no further episodes of upper GI bleeding, and was doing well on follow-up.

DISCUSSION

Patients with presinusoidal portal hypertension frequently form varices. When a segment of the portal venous bed is obstructed, varices develop only in areas that decompress the blocked segment. As an example, segmental portal hypertension within the splenic vein (splenic vein thrombosis) is associated with the formation of isolated gastric varices in the fundus of the stomach. Cirrhotic patients may present with variceal bleeding in the absence of the usual stigmata of chronic liver disease in up to 15% of cases.⁽¹⁾ Isolated gastric varices may be observed in up to 5% of patients with cirrhosis, and up to 10% of patients with non-cirrhotic portal hypertension.⁽²⁾

Mucinous cystic neoplasms (MCNs) of the pancreas are uncommon, and their diagnosis, treatment and prognosis are yet to be completely determined. They account for 10% of cystic lesions of the pancreas and 1% of pancreatic neoplasms. MCNs and serous cystadenomas account for more than 90% of primary cystic neoplasms of the pancreas.^(3,4) There has been a case report of echinococcal cystic lesions of the pancreas causing GI bleeding by compressing the splenic vein, and causing the formation of gastric varices.⁽⁵⁾ Apart from cystadenomas of the pancreas, choledochal cysts, pseudo-tumours, and abscesses of the pancreas have all been reported in literature as causes of left-sided portal hypertension and bleeding.⁽⁶⁻⁸⁾ Splenic vein thrombosis due to pancreatitis or malignant obstruction has also resulted in the formation of gastric fundal varices resulting in haematemesis,^(9,10) as could cases of idiopathic splenic vein stenosis.^(11,12) Polycystic disease of the liver and pancreas may also result in formation of gastric varices, by compression of the portal vein.⁽¹³⁾

Congenital hepatic fibrosis, Bantus syndrome, and Indian childhood cirrhosis may all present with variceal bleeding, without evidence of chronic liver disease, as there is presence of portal hypertension without evidence of liver failure in these patients. Such cases should prompt a search for these conditions, and a liver biopsy is usually diagnostic.^(14,15) Other unusual causes of haematemesis include Dieulafoy's lesions of the stomach, gastric polyposis and duodenal varices. Hereditary haemorrhagic telangiectasia, connective tissue disorders like pseudoxanthoma elasticum,

and bleeding disorders like haemophilia, are usually recognised based on history and physical examination.⁽¹⁴⁾ Other rarer causes of haematemesis include swallowed blood from the oropharynx or the pulmonary tract, which is regurgitated as haematemesis. Case reports exist of a base of the skull fracture, presenting as haematemesis.⁽¹⁶⁾ Angiodysplasias in the stomach may also present as a cause of upper GI haemorrhage. A high index of suspicion is required to diagnose these disorders. If the common risk factors, such as NSAID use or cirrhosis, are not present on history and examination, then OGD and imaging of the abdomen using US or CT are usually required. These tests will diagnose most cystic lesions of the liver and pancreas. In some cases, when the bleeding has subsided, such as in gastric angiodysplasias or Dieulafoy's lesions, the index OGD may be non-rewarding, and repeated examination at a later date may be beneficial.

As a surgical tip, it is useful to remember that a patient with a thrombosed splenic vein may have left-side portal hypertension and multiple collateral vessels leading from the spleen to the stomach via the short gastric vessels. In such cases, it is usually preferable to ligate and divide the splenic artery early in the procedure. There is usually no need to drain the splenic bed.⁽¹⁷⁾ In conclusion, haematemesis is a life-threatening condition, and determining the cause is of vital importance. In the Asian setting, the usual causes of haematemesis are variceal bleeding in a cirrhotic patient and peptic ulcer disease. When characteristic risk factors for haematemesis are not present on history and physical examination, then unusual causes of haematemesis need to be investigated. These unusual causes of upper GI bleed are usually curable, if diagnosed in time.

REFERENCES

1. Sarin SK, Chari S, Sundaram KR, et al. Young v adult cirrhotics: a prospective, comparative analysis of the clinical profile, natural course and survival. *Gut* 1988; 29:101-7.
2. Sarin SK, Jain AK, Lamba GS, Gupta R, Chowdhary A. Isolated gastric varices: prevalence, clinical relevance and natural history. *Dig Surg* 2003; 20:42-7.
3. Tibayan F, Vierra M, Mindelzun B, et al. Clinical presentation of mucin-secreting tumors of the pancreas. *Am J Surg* 2000; 179:349-51.
4. Anderson MA, Scheiman JM. Nonmucinous cystic pancreatic neoplasms. *Gastrointest Endosc Clin N Am* 2002; 12:769-79.
5. Klompmaker IJ, Haagsma EB, Slooff MJ. Splenic vein obstruction due to a solitary echinococcal splenic cyst, resulting in gastric fundus varices: an unusual cause of variceal bleeding. *HPB Surg* 1993; 6:229-32.
6. Rao KL, Chowdhary SK, Kumar D. Choledochal cyst associated with portal hypertension. *Pediatr Surg Int* 2003; 19:729-32.
7. Harnar T, Johansen K, Haskey R, Barker E. Left-sided portal hypertension from pancreatic pseudotumor. *Am J Gastroenterol* 1982; 77:639-41.
8. Snidow JJ, Pollak JS, Lagarde S. Gastric variceal bleeding cured with percutaneous abscess drainage. *J Vasc Interv Radiol* 1995; 6:84-6.
9. Jain A, Jain S, Chowdhury V, et al. Profuse variceal hemorrhage as a presenting feature of pancreatic adenocarcinoma in a young non-icteric patient. *J Assoc Physicians India* 1999; 47:730-2.
10. Mullan FJ, McKelvey ST. Pancreatic carcinoma presenting as bleeding from segmental gastric varices: pitfalls in diagnosis. *Postgrad Med J* 1990; 66:401-3.
11. Suhocki PV, Berend KR, Trotter JF. Idiopathic splenic vein stenosis: a cause of gastric variceal hemorrhage. *South Med J* 2000; 93:812-4.
12. Sato T, Yamazaki K, Toyota J, et al. Gastric varices with splenic vein occlusion treated by splenic arterial embolization. *J Gastroenterol* 2000; 35:290-5.
13. Srinivasan R. Polycystic liver disease: an unusual cause of bleeding varices. *Dig Dis Sci* 1999; 44:389-92.
14. Waqar SN, Jindani S, Baig NS, et al. Banti's syndrome: case report and review of literature. *J Pak Med Assoc* 2004; 54:99-101.
15. Okuda K. Non-cirrhotic portal hypertension versus idiopathic portal hypertension. *J Gastroenterol Hepatol* 2002; 17 suppl 3:S204-S213.
16. Cruise AS, Bryson J, Solomons N. A base of skull fracture presenting as haematemesis. *J Laryngol Otol* 2002; 116:1055-6.
17. Nakeeb A, Lillemoe KD, Cameron JL. Gastrointestinal Tract and Abdomen. Procedures for Benign and Malignant Pancreatic Disease. In: Dale DC, Federman DD, eds. *ACS Surgery*. New York: WebMD Inc, 2000.