

# Follicular thyroid carcinoma presenting as axial skeletal metastases

Sreedharan S, Pang C E, Chan G S W, Soo K C, Lim D T H

## ABSTRACT

**Introduction:** Common modes of presentation of follicular thyroid carcinoma include a solitary thyroid nodule and cervical lymphadenopathy. We report four patients who presented with axial skeletal metastases rather than the usual neck lumps.

**Methods:** A review of a database of 389 cases of thyroid cancer, managed by our department from 1990 to 2003, was performed. Based on each patient's presenting clinical feature, patients for the case series were selected.

**Results:** Four of the 389 patients presented with axial skeletal metastases – three were in the scalp while the fourth was in the sacral region. The histology of all four cases was that of follicular thyroid carcinoma. Despite widespread metastases at presentation, the overall survival rates of these patients remained relatively good.

**Conclusion:** Patients presenting with lesions suspicious of secondary malignancy in the axial skeleton should be clinically evaluated for thyroid cancer. This is especially important if the patient belongs to a high risk age group and has highly vascular lesions.

**Keywords:** axial skeletal metastasis, follicular thyroid carcinoma, papillary thyroid carcinoma,

sacral metastasis, scalp metastasis, thyroid carcinoma

*Singapore Med J 2007; 48(7):640–644*

## INTRODUCTION

Thyroid carcinoma is the commonest endocrinological malignancy. After papillary thyroid carcinoma (PTC), follicular thyroid carcinoma (FTC) is the second most common histological subtype. Common modes of initial presentation include a solitary thyroid nodule, a dominant nodule in a multinodular goitre and cervical lymphadenopathy. Rarely, patients with FTC initially present to the clinician with distant metastases. Despite the presence of metastatic disease, these patients do relatively well, especially when considering the poor prognoses seen in other forms of disseminated malignancies.<sup>(1,2)</sup> In this paper, we present a case series of four patients with FTC whose initial presentations were due to their axial skeletal metastases.

## METHODS

A detailed review of a database of 389 cases of thyroid cancer, managed by three head and neck surgeons in our department from 1990 to 2003, was performed. This database, which included information on the presenting clinical features of all the patients, was used to select the patients for our series. Further clinical information and diagnostic images of these four patients were obtained from their case notes and the hospital's online patient records.

## RESULTS

The distribution of our patients, with FTC and PTC, having distant metastases at presentation, is shown

Department of  
General Surgery,  
Singapore General  
Hospital,  
Outram Road,  
Singapore 169608

Sreedharan S, MBBS  
Medical Officer

Pang CE, MBBS  
House Officer

Chan GSW, MBBS,  
MMed, MRCSE  
Registrar

Department of  
Surgical Oncology,  
National Cancer  
Centre,  
11 Hospital Drive,  
Singapore 169610

Soo KC, MD,  
FRACS, FACS  
Clinical Professor  
and Senior  
Consultant

Lim DTH, MMed,  
FRCSE, FAMS  
Senior Consultant  
(Head and Neck  
Surgery)

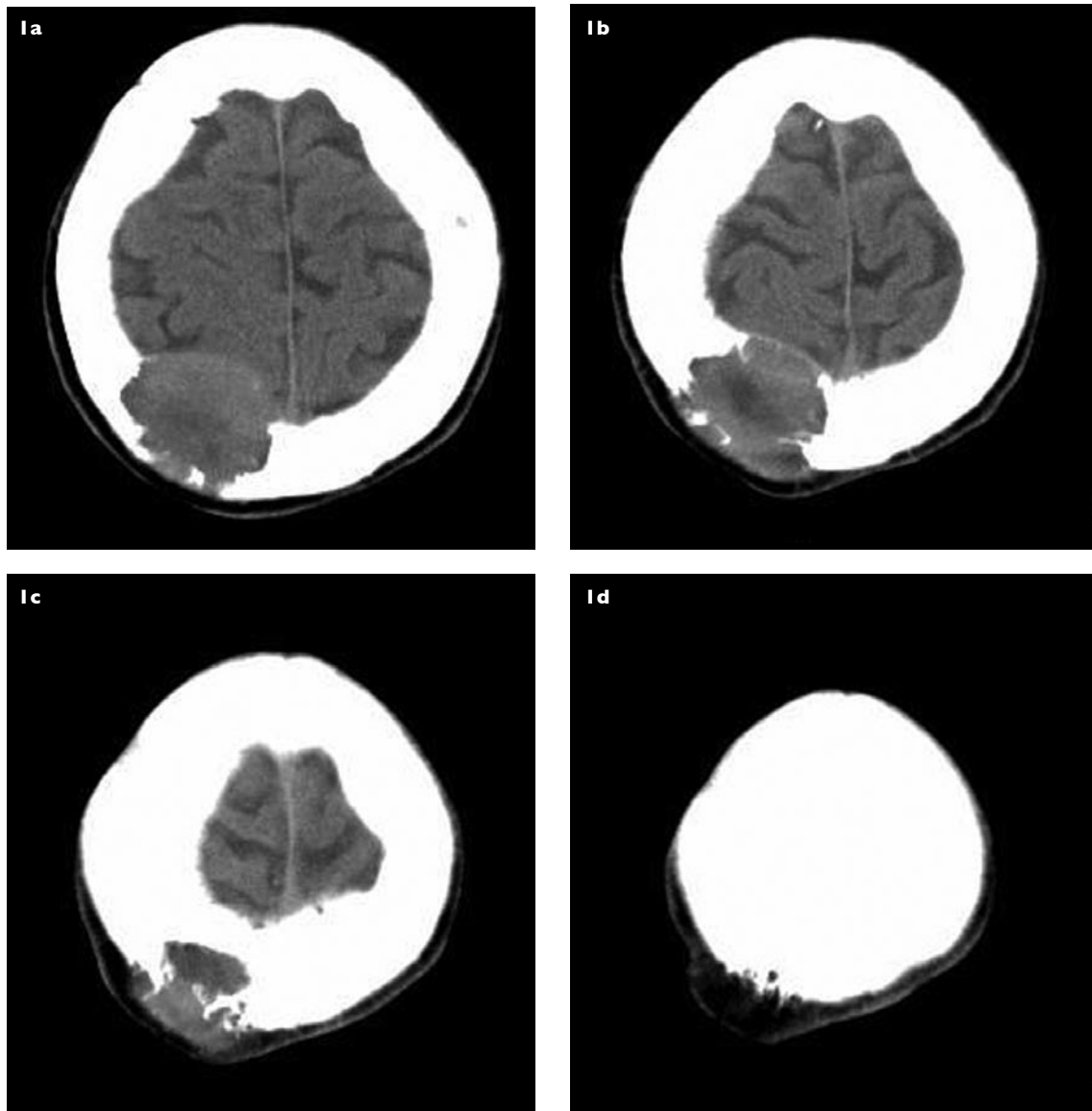
Correspondence to:  
Dr Sreedharan S  
Tel: (65) 6321 4051  
Fax: (65) 6220 9323  
Email: sreedharan.  
sechachalam@  
singhealth.com.sg

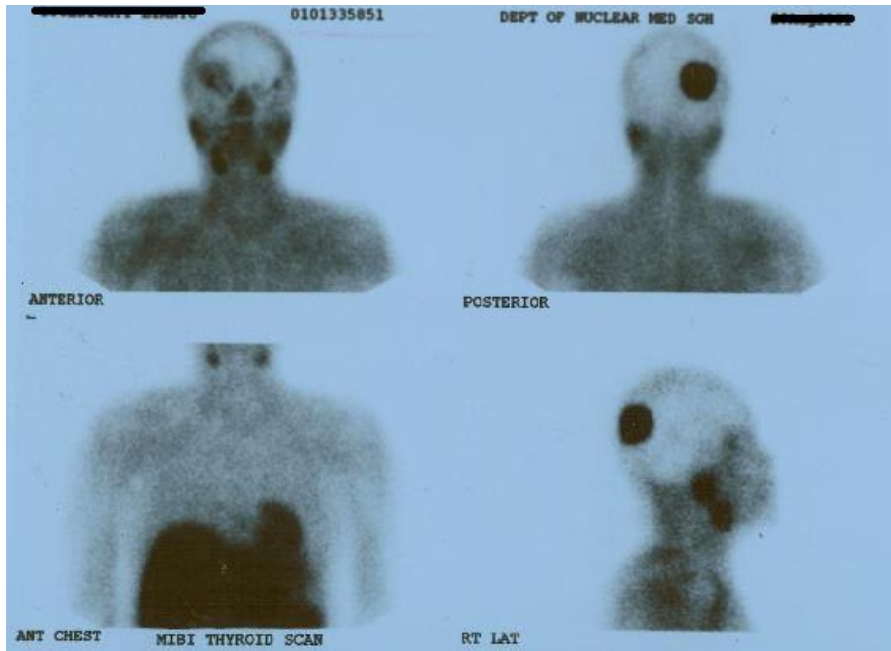
**Table I. Distribution of our patients (with FTC and PTC) and their presentation.**

	FTC No. of cases (%)	PTC No. of cases (%)
Patient cases	77 (19.9)	290 (74.6)
Distant metastases on presentation	10 (13.0)	11 (3.8)
Location of the distant metastases on presentation	6 skeletal, 3 lung, 1 sellar	8 lung, 3 brain
Initial presentation due to distant metastases	5 (6.5)	0 (0)
Initial presentation due to axial skeletal metastases	4 (5.2)	0 (0)

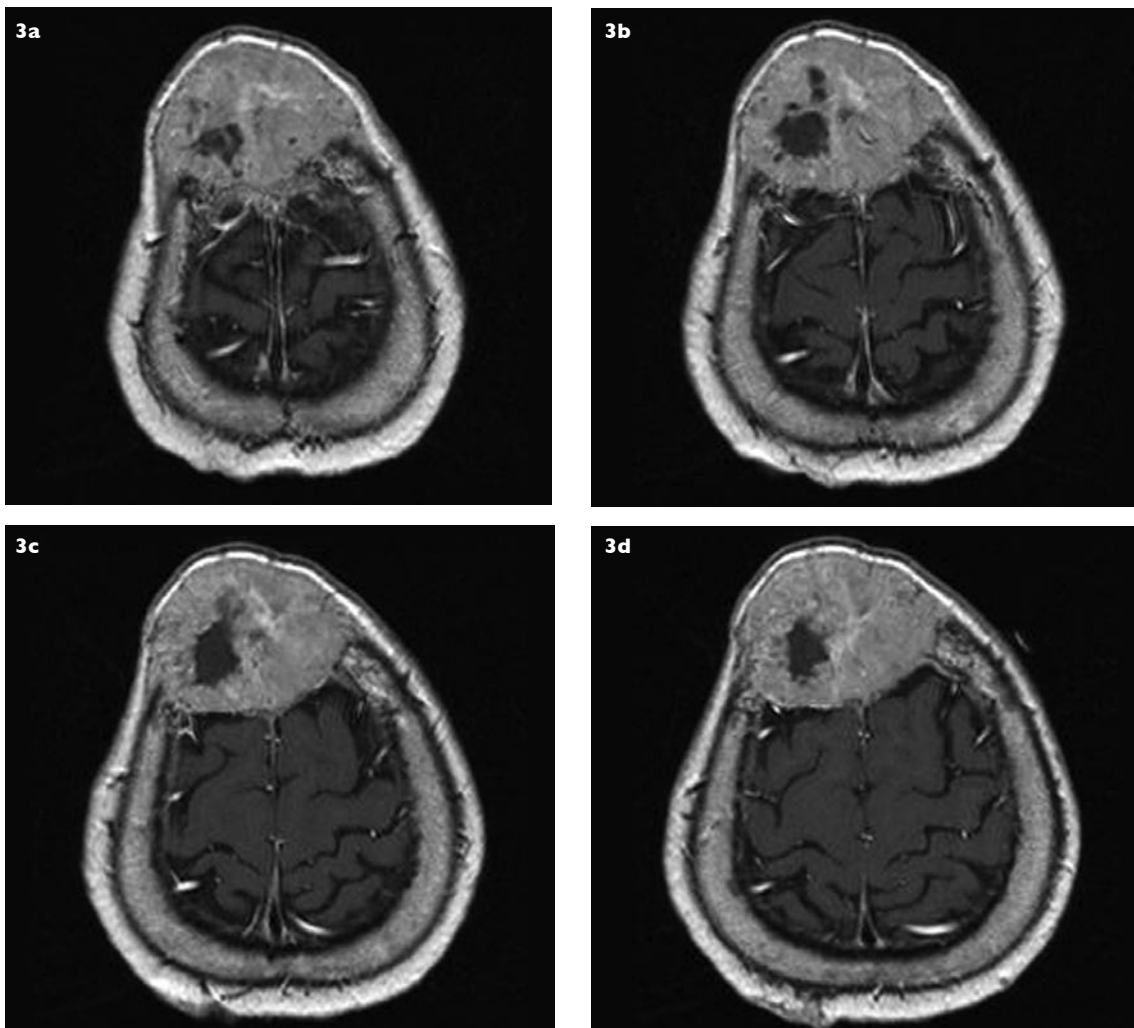
**Table II. Summary data of FTC patients with initial presentation due to axial skeletal metastases.**

Case no.	Age at diagnosis (years)	Site and description of axial skeletal metastasis	Treatment	Length of survival (months)
1	57	<ul style="list-style-type: none"> <li>• Involving scalp, overlying subcutaneous tissue and extending into intracranial cavity</li> <li>• Soft and pulsatile</li> </ul>	<ul style="list-style-type: none"> <li>• Total thyroidectomy</li> <li>• Radiotherapy to scalp metastasis</li> <li>• Postop RAI</li> </ul>	> 57 Still on follow-up
2	75	<ul style="list-style-type: none"> <li>• Involving scalp, overlying subcutaneous tissue and extending into intracranial cavity</li> <li>• Soft and pulsatile</li> </ul>	<ul style="list-style-type: none"> <li>• Total thyroidectomy</li> <li>• Excision of scalp metastasis</li> <li>• Postop RAI</li> </ul>	12 Deceased
3	59	<ul style="list-style-type: none"> <li>• Involving both scalp and sagittal sinus</li> <li>• Soft and pulsatile</li> </ul>	<ul style="list-style-type: none"> <li>• Total thyroidectomy</li> <li>• Excision of scalp metastasis</li> <li>• Postop RAI</li> </ul>	> 25 Still on follow-up
4	65	<ul style="list-style-type: none"> <li>• Involving lumbosacrum and overlying subcutaneous tissue</li> <li>• Soft and pulsatile</li> </ul>	<ul style="list-style-type: none"> <li>• Total thyroidectomy</li> <li>• Radiotherapy to sacral metastasis</li> <li>• Postop RAI</li> </ul>	> 68 Still on follow-up

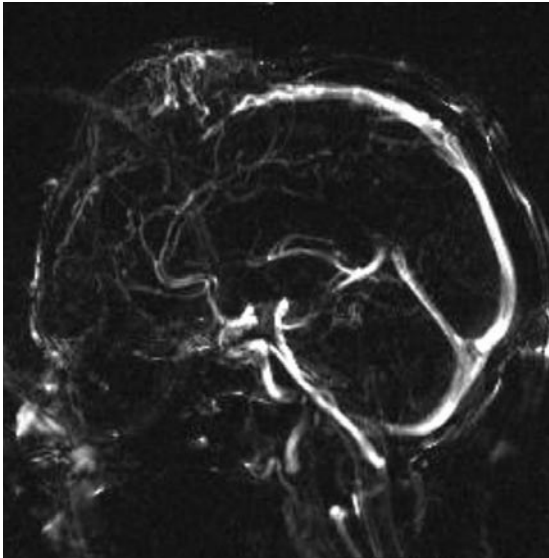
**Fig. 1** Case 1. Axial CT images show a metastatic soft tissue mass extending into the scalp and internally into the cranial cavity, compressing the right parietal lobe.



**Fig. 2** Case 1. Technetium-99m sestamibi thyroid scans show metastatic thyroid tissue in the right parietal scalp and skull.



**Fig. 3** Case 2. Contrast-enhanced axial T1-W MR images show a large vault metastasis, with extensions both intracranially and to the overlying subcutaneous tissue.



**Fig. 4** Case 3. Cranial MR venography shows the metastatic lesion on the frontal bone with involvement of the anterior aspect of the superior sagittal sinus.

in Table I. Of 77 patients with FTC, 13% of them had distant metastases at presentation, and skeletal metastases constituted the majority. In comparison, only 3.8% of our 290 patients with PTC had distant metastases at presentation, and pulmonary metastases constituted the majority in this histological subtype.

In our group of patients with FTC, 6.5% of the patients' initial presentations were due to their distant metastases – the reason for their surgical consultations were the metastases rather than the primary tumours. Four of these patients had axial skeletal metastases as their presenting features. A summary of these four patients' clinical features, histology and treatment is shown in Table II.

#### Case 1

A 57-year-old Chinese man presented with a three-month history of a right parietal lump, which was 4 cm in diameter, soft and pulsatile. A left thyroid nodule, 5 cm in diameter, was also noted. Fine needle aspiration cytology (FNAC) of the thyroid nodule showed scattered atypical thyroid follicular epithelial cells as well as large sheets of papillary clusters. Non-enhanced computed tomography (CT) of the head revealed a 4.5 cm × 4 cm diameter soft tissue mass extending into the scalp and internally into the cranial cavity, compressing the right parietal lobe (Fig. 1). A Technetium-99m sestamibi thyroid scan (Fig. 2) showed metastatic thyroid tissue in the right parietal scalp and bone.

The patient underwent a total thyroidectomy. Histology was confirmatory for minimally invasive

follicular carcinoma. Postoperatively, he received radioactive iodine (RAI) therapy as well as radiotherapy to his scalp metastases. 57 months postoperatively, the patient had had no local recurrence of the tumour clinically although positive emission tomography still demonstrated vertebral and skull metastases.

#### Case 2

A 78-year-old Chinese woman, presented with a one-year history of an enlarging midline forehead lump. This lump was soft and pulsatile. CT of the head showed a 4.8 cm × 6.6 cm × 5.6 cm expanded frontal vault lesion. Magnetic resonance (MR) imaging of this lesion (Fig. 3) showed a large vault metastasis with extensions both intracranially, and to the overlying subcutaneous tissue. Apart from indenting the frontal lobe, the intracranial extension also invaded the frontal aspect of the superior sagittal sinus.

Histology of this subcutaneous lump, obtained via an incisional biopsy, was that of metastatic follicular thyroid carcinoma. CT of the neck revealed a 2.7 cm × 2.6 cm right thyroid nodule with no enlarged neck nodes. A subsequent bone scintiscan showed no other bony metastasis. The patient underwent a total thyroidectomy with excision of the forehead tumour. This was followed by RAI therapy. She succumbed to the disease 12 months postoperatively.

#### Case 3

A 59-year-old Indian man presented with a three-month history of an enlarging forehead lump. On MR imaging, this lump appeared to be a highly vascular mass, 10.7 cm × 5.7 cm, arising from, and eroding, the frontal bone with involvement of the anterior aspect of the superior sagittal sinus (Fig. 4). This mass was excised and histology showed a metastatic follicular carcinoma. He subsequently underwent a total thyroidectomy after CT of the neck showed a 4 cm diameter left thyroid nodule. Postoperatively, the patient received RAI therapy and is now in remission.

#### Case 4

A 65-year-old Chinese woman, with a history of RAI ablation therapy for multinodular goitre nine years ago, presented with a six-month history of an enlarging cutaneous sacral swelling. This soft pulsatile lump was causing persistent rest pain. Clinically, she also had a 7 cm diameter right dominant nodule in a multinodular goitre with bilateral cervical lymphadenopathy.

CT of the pelvis showed destruction of the posterior elements of the S1 and S2 segments associated with a soft tissue mass measuring 6.6 cm × 6.1 cm, and showing rim enhancement with central low attenuation, consistent with necrosis. A Technetium-99m sestamibi

thyroid scan confirmed the diagnosis of metastatic thyroid carcinoma in the lower lumbar spine and sacrum. She underwent total thyroidectomy with bilateral radical neck dissection. Histology showed a follicular thyroid carcinoma. The patient received postoperative RAI treatment and radiotherapy to the sacrum. Five years postoperatively, although asymptomatic, she was found to have pulmonary and bony metastases.

## DISCUSSION

FTC has a higher propensity to have distant metastases at presentation compared to PTC.<sup>(2)</sup> Our results indicate a three-fold higher likelihood of FTC having distant metastases at presentation than PTC. While skeletal metastases accounted for the majority of the distant metastases at presentation in FTC, pulmonary metastases accounted for the majority in PTC. Other than pulmonary metastases, only brain metastases were seen at presentation in our patients with PTC.

It has been noted that 80% of patients with FTC were seen initially with a solitary thyroid nodule.<sup>(3)</sup> Of our patients with FTC, five of them presented due to their distant metastases rather than due to their thyroid lumps. Four of these five patients presented initially with axial skeletal metastases. Shaha et al noted that the highest incidence of presentation with distant metastases in differentiated thyroid carcinoma occurs in the age group of above 45 years<sup>(2)</sup> – all four patients in our case series belong to this age group.

The scalp is the commonest site of cutaneous metastases for thyroid carcinoma.<sup>(4,5)</sup> In our series, two patients presented with metastases of the skull, involving the scalp. Hence, the presence of a metastatic lesion in the scalp, with or without the involvement of the skull, should alert one to the possibility of a primary thyroid tumour.

In two similar studies on axial skeletal metastases from thyroid carcinoma, the iliolumbosacral angle was noted to be a common site of metastasis from thyroid carcinoma.<sup>(1,5)</sup> Our fourth case, which presented with a lumbosacral metastasis, adds weight to the fact that the iliolumbosacral metastases may be particular to disseminated thyroid carcinoma.

Fukunari et al have utilised colour Doppler imaging to demonstrate that 86.3% of thyroid glands with FTC, to have moderate to high vascularity.<sup>(6)</sup> This would explain the pulsatile nature of the skeletal lesions in three of our patients. The fourth skeletal lesion, though not reported clinically as pulsatile, was described as soft and is secondary to a high underlying vascularity, as reported on the MR imaging (Case 3).

Only about 4% of patients with differentiated thyroid carcinoma have distant metastases at presentation.<sup>(2)</sup> However, in a patient presenting with a skeletal lesion,

with disseminated malignancy as a differential diagnosis, it is vital to rule out thyroid cancer clinically, especially if the following features are present:

- Age of patient more than 45 years
- Site of lesion either the skull or lumbosacral region
- Soft, pulsatile lesion.

This will enable the clinician to diagnose a primary thyroid malignancy based on FNAC of a palpable thyroid nodule, and confirm the metastatic nature of the skeletal lesions using a radioisotope-labelled thyroid scan. Such a method will eliminate the need for a more invasive procedure, like an incisional biopsy of the skeletal lesion, for the purpose of diagnosis.

In patients without a clinically-palpable thyroid nodule, diagnosis often requires either a FNAC or a biopsy of the skeletal lesion. An additional investigation that may be useful is measurement of serum anti-thyroid transcription factor-1 antibodies. These antibodies have been useful in differentiating lung and thyroid cancers from other types of cancers.<sup>(7-10)</sup>

Metastatic disease is the primary cause of death in FTC.<sup>(11)</sup> However, despite disseminated malignancy, with appropriate management, long-term survival rates of up to 43% have been quoted.<sup>(2)</sup> Based on Table II, the average length of survival of our patients presenting with axial skeletal metastases is higher than 40.5 months. Appropriate initial evaluation and treatment, including an aggressive surgical approach by our head and neck team, have contributed to a good survival rate in the patients in our series.

## REFERENCES

1. Court C, Noun Z, Gagey O, Nordin JY. [Surgical treatment of metastases from thyroid cancer in the axial skeleton. A retrospective study of 18 cases]. *Acta Orthop Belg* 2000; 66:345-52. French.
2. Shaha AR, Shah JP, Loree TR. Differentiated thyroid cancer presenting initially with distant metastasis. *Am J Surg* 1997; 174:474-6.
3. Emerick GT, Duh QY, Siperstein AE, Burrow GN, Clark OH. Diagnosis, treatment, and outcome of follicular thyroid carcinoma. *Cancer* 1993; 72:3287-95.
4. Koller EA, Tourtelot JB, Pak HS, et al. Papillary and follicular thyroid carcinoma metastatic to the skin: a case report and review of the literature. *Thyroid* 1998; 8:1045-50.
5. Saillant G, Enkaoua EA, Aimard T, Roy-Camille R. [Spinal metastases of thyroid origin. Apropos of a series of 37 cases]. *Rev Chir Orthop Reparatrice Appar Mot* 1995; 81:672-81. French.
6. Fukunari N, Nagahama M, Sugino K, et al. Clinical evaluation of color Doppler imaging for the differential diagnosis of thyroid follicular lesions. *World J Surg* 2004; 28:1261-5.
7. Alwaheeb S, Ghazarian D, Boerner SL, Asa SL. Cutaneous manifestations of thyroid cancer: a report of four cases and review of the literature. *J Clin Pathol* 2004; 57:435-8.
8. Lau SK, Luthringer DJ, Eisen RN. Thyroid transcription factor-1: a review. *Appl Immunohistochem Mol Morphol* 2002; 10:97-102.
9. Ordóñez NG. Thyroid transcription factor-1 is a marker of lung and thyroid carcinomas. *Adv Anat Pathol* 2000; 7:123-7.
10. Katoh R, Miyagi E, Nakamura N, et al. Expression of thyroid transcription factor-1 in human C cells and medullary thyroid carcinomas. *Hum Pathol* 2000; 31:386-93.
11. Hoelting T, Zielke A, Siperstein AE, Clark OH, Duh QY. Aberrations of growth factor control in metastatic follicular cancer in vitro. *Clin Exp Metastasis* 1994; 12:315-23.