

Myelolipoma within a non-functional adrenal cortical adenoma

Ong K, Tan K B, Putti T C

ABSTRACT

Myelolipoma within an adrenal cortical adenoma is a very rare cause of adrenal incidentaloma, and only nine cases have been reported in the English and Japanese literature. We report a 66-year-old Chinese man, with a history of hypertension and hyperlipidaemia, who presented with lower limb oedema and had a computed tomography (CT) of the abdomen done to exclude intra-abdominal mass. His lower limb symptoms resolved after switching his antihypertensive medication. CT of the abdomen showed a large heterogeneously-enhancing mass in the left suprarenal region, measuring 72 mm by 55 mm. Clinical history, physical examination and laboratory results did not show any evidence to suggest metabolic disorder such as Cushing's syndrome, hyperaldosteronism or catecholamine hypersecretion. The patient underwent a left adrenalectomy, and a histopathological study confirmed the mass to be a non-functional adrenal cortical adenoma containing myelolipoma. The patient was well postoperatively and was discharged uneventfully. To the best of our knowledge, this is the first non-functional adrenal cortical adenoma reported; in the nine cases of myelolipoma within an adrenal cortical adenoma reported previously, all the patients had Cushing's syndrome. The literature on synchronous myelolipoma with adrenal adenoma, and myelolipoma within functional adrenal adenoma, is reviewed.

Keywords: adrenal adenoma, adrenal carcinoma, adrenal incidentaloma, myelolipoma

Singapore Med J 2007;48(7):e200–e202

INTRODUCTION

Myelolipoma within an adrenal cortical adenoma is rare. To the best of our knowledge, only nine cases have been

reported in the English and Japanese literature. We present a 66-year-old Chinese man who had a non-functional adrenal cortical adenoma containing myelolipoma. The literature on synchronous myelolipoma with adrenal adenoma, and myelolipoma within functional adrenal adenoma, is reviewed.

CASE REPORT

A 66-year-old Chinese man, with a history of hypertension and hyperlipidaemia, was referred by a private general practitioner (GP) to the hospital specialist clinic, for lower limb oedema. Computed tomography (CT) was done to exclude intra-abdominal mass, and showed an incidental finding of left adrenal mass, described as a large, heterogeneously enhancing mass in the left suprarenal region, measuring 72 mm × 55 mm in the maximum axial dimension. There were also small focal areas of high attenuation noted, which were consistent with calcification. While waiting for the CT appointment, the patient's antihypertensive medication was switched by the private GP, and the oedema in his lower limbs resolved spontaneously a few days thereafter. The patient did not have metabolic syndrome, which was defined as the presence of three or more of the following abnormalities: waist circumference > 101.6/88.9 cm (male/female), triglyceride levels ≥ 150 mg/dL, high density lipoprotein (HDL) cholesterol level < 40/50 mg/dL (male/female), blood pressure ≥ 130/85 mmHg, and fasting glucose ≥ 110 mg/dL. These criteria were established by the National Cholesterol Education Program Adult Treatment Panel III. The patient's pre-medicated serum levels for triglyceride and HDL were 155 mg/dL (1.74 mmol/L) and 47 mg/dL (1.20 mmol/L), respectively. His waistline was 83.8 cm, and he did not have a history of impaired glucose tolerance or diabetes mellitus.

The patient was subsequently admitted to the hospital for preoperative workup of the left adrenal mass. At admission, on physical examination, the patient was alert and comfortable, with a blood pressure of 130/70 mmHg and heart rate of 68 beats/min. Other physical examination was unremarkable. The laboratory tests showed that the cortisol level

Department of Pathology,
National University Hospital,
5 Lower Kent Ridge Road,
Singapore 119074

Ong K, MBBS
Medical Officer

Department of Pathology,
Yong Loo Lin School of Medicine,
National University of Singapore,
5 Lower Kent Ridge Road,
Singapore 119074

Tan KB, MBBS,
MRCPATH, FRCPA
Consultant

Putti TC, MBBS,
MD, DipAMB
Senior Consultant and
Clinical Director

Correspondence to:
Dr Keith Ong
Tel: (65) 6772 4002
Fax: (65) 6778 0671
Email: quyang77@singnet.com.sg

Table I. Results of the pheochromocytoma screen test.

Urine volume (2,030 ml)	At 0 hr (nmol/L)	At 24 hr (nmol/day)
Urine adrenaline	< 10	Value out of detection limit. Calculation not performed.
Urine noradrenaline	102	207 (expected range 72–505)
Urine metanephrine	278	564 (expected range 264–1,729)
Urine normetanephrine	356	723 (expected range 480–2,424)
Urine vanillylmandelic acid	< 5000	Value out of detection limit. Calculation not performed

and aldosterone level were well within the normal range. The serum aldosterone was 144 pmol/L (normal range, supine 28–445, erect 110–860) and the 8 am serum cortisol was 186 nmol/L (normal range 171–536). A dexamethasone suppression test was not done. The serum potassium and sodium were within the normal range. The pheochromocytoma screen was done and the results are shown in Table I.

From the clinical history, physical examination and laboratory results, there was no evidence to suggest that the patient had a metabolic disorder commonly associated with adrenal tumours, like Cushing's syndrome, hyperaldosteronism or catecholamine hypersecretion. Hence, the patient had a clinically non-functional adrenal incidentaloma. Subsequently, the patient had a left total adrenalectomy performed. Postoperatively, the patient was well and was discharged uneventfully. The patient remained well in the one-year postoperative follow-up.

An encapsulated, oval adrenal mass measuring 12.0 cm × 4.5 cm × 4.0 cm, and weighing 116 g, was found in the left adrenal region. The cut surface showed a golden yellow appearance, with multiple areas of small, brownish lesions varying from 0.2 cm to 1.0 cm in maximum dimension, and multiple cystic degenerative areas ranging from 0.4 cm to 1.5 cm in maximum dimension. A remnant of the normal adrenal gland measuring 1.5 cm × 1.0 cm × 1.0 cm was located at one end of the mass (Fig. 1).

Histologically, the tumour was well encapsulated by a layer of connective tissue. The tumour was predominantly composed of clear and compact cells forming cords and nests. There were small foci of oncocytic changes and atypia with infrequent mitosis. Areas of cystic degeneration were also seen. There was no necrosis, vascular or capsular invasion.

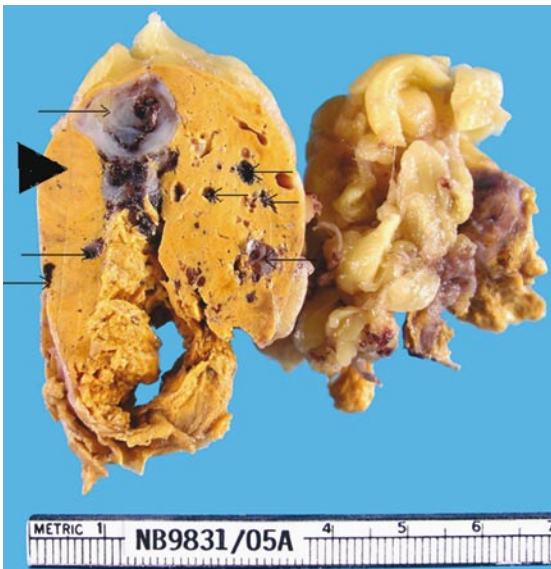

Fig. 1 Photograph of the adrenal cortical adenoma shows the largest cross section (arrowhead) and multiple foci of myelolipoma (arrows). The normal adrenal gland is not shown.

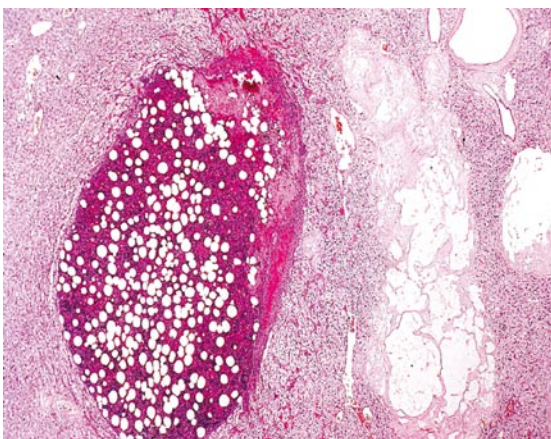


Fig. 2 Photomicrograph of the adrenal cortical adenoma and the adjacent myelolipoma (Haematoxylin & eosin, × 20).

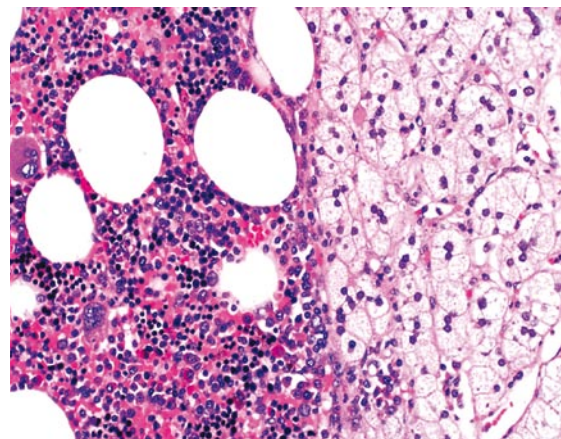


Fig. 3 Photomicrograph of the myelolipoma within the adrenal cortical adenoma (Haematoxylin & eosin, × 300).

Immunohistochemical stain for Ki 67 showed minimal proliferative activity (< 1%). Within this tumour mass, there were multiple foci of adipose tissue containing haematopoietic cells (Fig. 2), ranging from 0.2 cm to 1.0 cm in maximum dimension. These foci were recognised as myelolipomas (Fig. 3). The myelolipomas made up about 10%–15% of the total tumour volume. The cortex and medulla of the adjacent normal adrenal tissue were compressed and atrophic. Based on the histological features and the clinical findings, a diagnosis of myelolipoma within a non-functional adrenal cortical adenoma was made.

DISCUSSION

Adrenal myelolipoma was first described in 1905 by Gierke, and later given the name myelolipoma by Oberling. It is essentially an adrenal mass composed of lipoid and haematopoietic elements in varying proportions, where the reticulum is present only in the fatty areas. The haematopoietic components are not situated in the reticular sinusoids, hence these cells cannot enter the systemic circulation, thus making myelolipoma a biochemically non-functional tumour. Autopsy studies have reported the incidence of myelolipomas as 0.2% in the general population.⁽¹⁾ However, with the increased usage of CT and magnetic resonance imaging, resulting in improved sensitivity in picking up adrenal incidentaloma, the incidence of myelolipoma should be higher in further studies.

Adrenal myelolipoma by itself is uncommon. Thus, the synchronous occurrence of two separate tumours, adrenal myelolipoma and adrenal adenoma, within the same adrenal gland, is very unusual. Goetz and Pasimeni reported five cases and one case, respectively, of such synchronous myelolipoma with functional adenoma,^(2,3) but all six patients showed either Cushing's or Conn's syndrome. Two cases of synchronous myelolipomas with non-functional adrenal adenoma had also been reported.^(4,5)

Myelolipoma within an adrenal cortical adenoma is rare, and to the best of our knowledge, only nine cases have been reported in the Japanese and English literature. All the patients in the reported cases had Cushing's syndrome, hence these myelolipomas were found within the functional adrenal cortical adenomas.⁽⁶⁻⁸⁾ Non-functional adrenal cortical adenoma containing myelolipoma is very rare, and based on a PubMed search at the time of this study, none has been

reported so far. We report the first case of myelolipoma within a non-functional adrenal adenoma.

Besides its rare occurrence, we also note that, to the best of our knowledge, this is the largest and heaviest cortical adenoma (measuring 12.0 cm × 4.5 cm × 4.0 cm and weighing 116 g) that is associated with myelolipoma. In fact, some authors believe that increased tumour mass correlates with malignancy.⁽⁹⁾ An adenoma with a sizable myelolipomatous component may have an increased weight contributed by the latter, and this should be taken into consideration when using gland weight for histopathological prognostication. Other adverse pathological features, such as broad fibrous bands, necrosis, a diffuse pattern of growth, clear cells constituting less than 25% of tumour, vascular and capsular invasion, nuclear hyperchromasia, increased or atypical mitoses, should also be used in predicting behaviour of adrenal cortical neoplasms, histologically.⁽⁹⁻¹¹⁾ In conclusion, this case highlights the relatively large size and weight of the adrenal adenoma, possibly contributed by the myelolipoma, and their implications in the histological prognostication.

ACKNOWLEDGEMENT

We would like to thank Mr TC Tan for the photography.

REFERENCES

1. Abecassis M, McLoughlin MJ, Langer B, Kudlow JE. Serendipitous adrenal masses: prevalence, significance and management. *Am J Surg* 1985; 149:783-8.
2. Goetz SP, Niemann TH, Robinson RA, Cohen MB. Hematopoietic elements associated with adrenal glands; a study of the spectrum of change in nine cases. *Arch Pathol Lab Med* 1994; 118:895-6.
3. Pasimeni G, Rossi F, Ragazzo M, et al. Adrenal adenoma and myelolipoma in an elderly patient with Conn's syndrome. *Recenti Prog Med* 2000; 91:116-8.
4. Manassero F, Pomara G, Rappa F, et al. Adrenal myelolipoma associated with adenoma. *Int J Urol* 2004; 11:326-8.
5. Weiner SN, Bernstein RG, Lowy S, Karp H. Combined adrenal adenoma and myelolipoma. *J Comput Assist Tomogr* 1981; 5:440-2.
6. Matsuda T, Abe H, Takase M, et al. Case of combined adrenal cortical adenoma and myelolipoma. *Pathol Int* 2004; 54:725-9.
7. Vyberg M, Sestoft L. Combined adrenal myelolipoma and adenoma associated with Cushing's syndrome. *Am J Clin Pathol* 1986; 86:541-5.
8. Vrezas I, Wentworth P, Bornstein SR. Myelolipomatous foci in an adrenal adenoma causing Cushing's syndrome? *Endocr Res* 2003; 29:67-71.
9. Weiss LM. Comparative histologic study of 43 metastasizing and nonmetastasizing adrenocortical tumors. *Am J Surg Pathol* 1984; 8:163-9.
10. Medeiros LJ, Weiss LM. New developments in the pathologic diagnosis of adrenal cortical neoplasms. *Am J Clin Pathol* 1992; 97:73-83.
11. Hough AJ, Hollifield JW, Page DL, Hartmann WH. Prognostic factors in adrenal cortical tumors. A mathematical analysis of clinical and morphologic data. *Am J Clin Pathol* 1979; 72:390-9.