

# Single stage craniofacial reconstruction for fronto-nasal encephalocele and hypertelorism in an adult

Agrawal A, Rao K S, Krishnamoorthy B, Shetty R B, Anand M, Jain H

## ABSTRACT

The fronto-nasal type of fronto-ethmoidal encephalocele is one of the more common subtype of anterior encephaloceles. We discuss different aspects and difficulties in the management of fronto-nasal encephalocele in a 30-year-old woman. Fronto-nasal encephaloceles present a difficult scenario in adults, mainly due to large gliotic herniating brain tissue, large bony and dural defect, increase in the size of paranasal sinuses, and scars from previous surgeries. However, all difficulties can be overcome after applying the principles of craniofacial reconstructions, i.e. correction of bone defect with autologous split calvarial graft, dural closure with autologous pericranial graft and correction of hypertelorism.

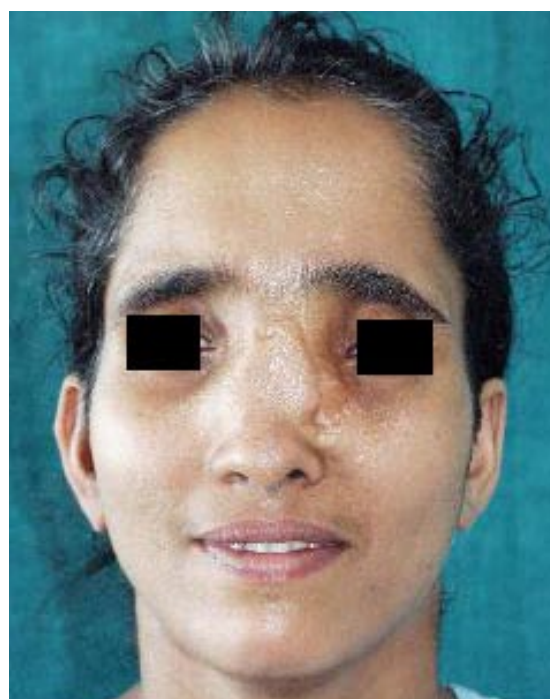**Keywords:** anterior cranial fossa, calvarial graft, craniofacial reconstruction, fronto-nasal encephalocele, hypertelorism, single stage craniofacial reconstruction

*Singapore Med J 2007;48(8):e215–e219*

## INTRODUCTION

Encephaloceles are congenital lesions. They can be anatomically classified into: (a) sincipital or frontal encephalomeningocele; (b) posterior or occipital encephalocele; (c) basal encephalocele; and (d) parietal encephalocele.<sup>(1)</sup> In the sincipital or fronto-ethmoidal type, the posterior limit of the skull defect is the crista galli. Sincipital or fronto-ethmoidal type can be further sub-classified into:<sup>(1)</sup>

- a. Fronto-ethmoidal encephalocele
  - i. Naso-frontal
  - ii. Naso-ethmoidal
  - iii. Naso-orbital
- b. Interfrontal encephalocele
- c. Craniofacial cleft



**Fig. 1** Preoperative photograph show the deformity, previous surgery scar and obvious hypertelorism.

The fronto-nasal type of fronto-ethmoidal encephalocele is one of the more common subtypes.<sup>(1-3)</sup> In children, experienced cranio-facial teams equipped with good paediatric intensive care unit backups routinely perform single stage craniofacial reconstruction.<sup>(4-6)</sup> In this case, we discuss different aspects and difficulties in the management of fronto-nasal encephalocele in an adult.

## CASE REPORT

A 30-year-old woman presented with swelling over her nose, cosmetic deformity of the mid-face, and increased distance between both eyes since childhood. She had a scar over the swelling following an attempted surgery in her childhood (at the age of eight years) and it had increased in size over time. The wound healed without complications (i.e. cerebrospinal fluid leak) except for a scar (Fig. 1). On examination, she had widely-set eyes with increased intercanthal

Department of Surgery,  
BP Koirala Institute of Health Sciences,  
Dharan,  
Nepal

Agrawal A, MCh  
Assistant Professor in Neurosurgery

Department of Cranio-Maxillofacial Surgery,  
Nitte Meenakshi Institute of Craniofacial Surgery,  
Mangalore,  
India

Rao KS, MDS  
Professor

Krishnamoorthy B,  
MDS  
Professor

Anand M, MDS  
Fellow

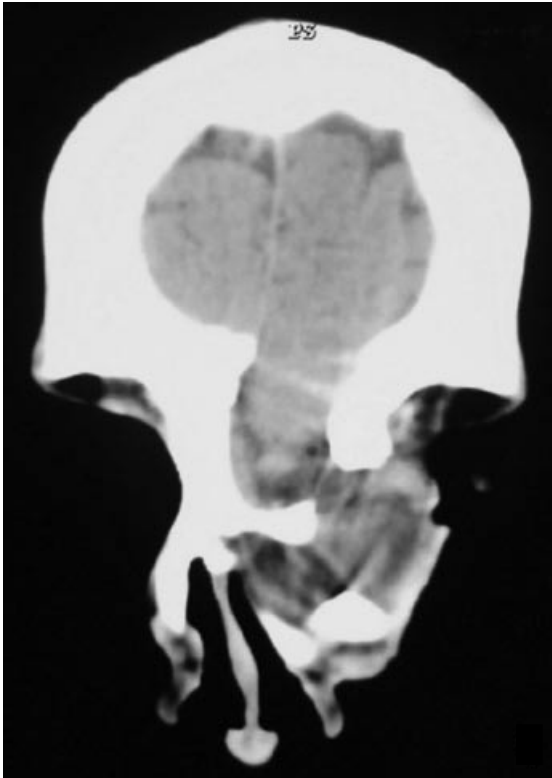
Department of Radiology,  
KS Hegde Medical Academy,  
Mangalore,  
India

Shetty RB, MD  
Associate Professor

AB Shetty Memorial Institute of Dental Sciences,  
Mangalore,  
India

Jain H, MDS  
Senior Resident in Maxillofacial Surgery

**Correspondence to:**  
Dr Amit Agrawal  
Datta Meghe Institute of Medical Sciences,  
Department of Surgery,  
Sawangi (Meghe),  
Wardha 442005,  
Maharashtra,  
India  
Tel: (91) 7152 395 6552  
Fax: (91) 7152 224 5318  
Email: dramitagrawal@gmail.com

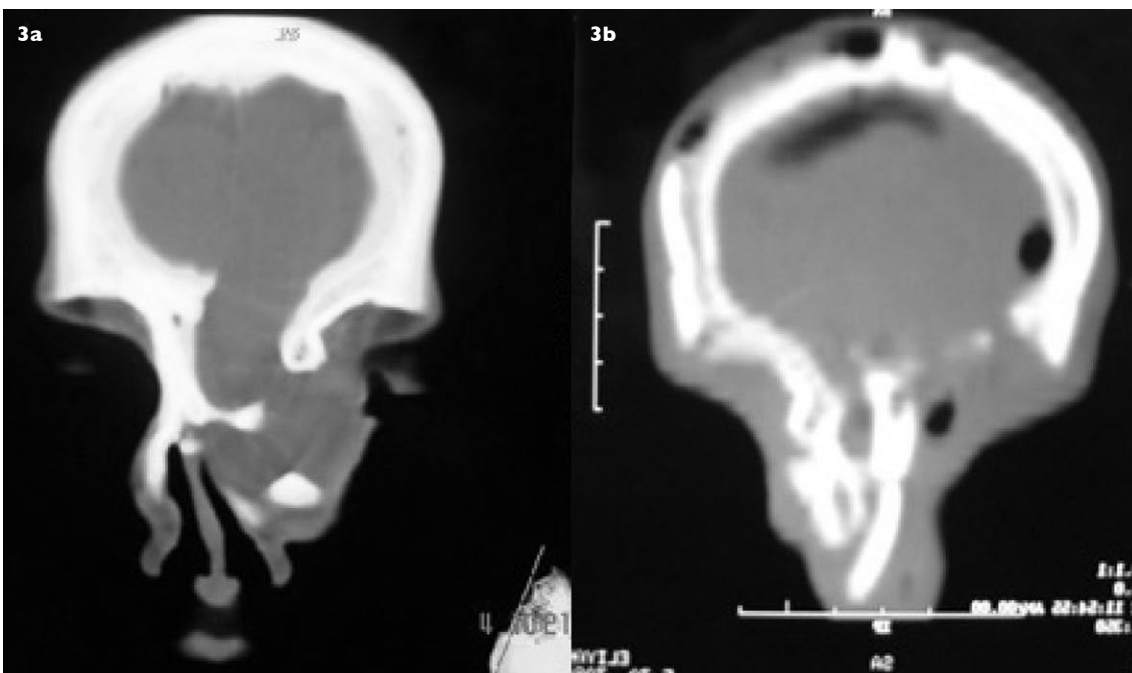


**Fig. 2** Coronal CT image shows the defect in the cranial base and herniating brain tissue in the nasal cavity.

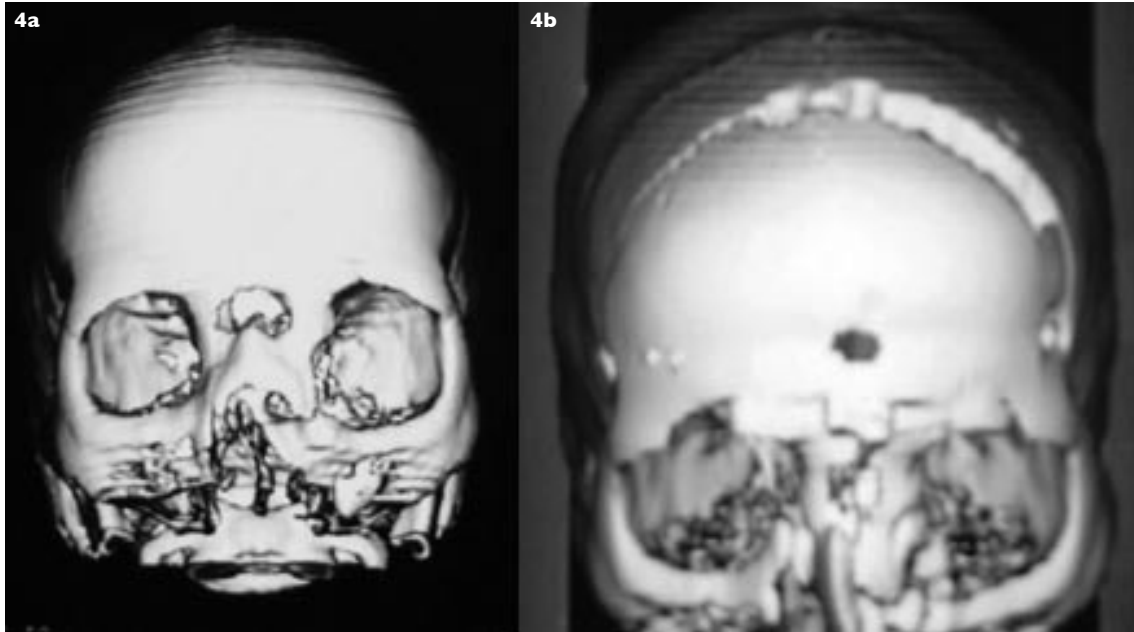
investigated with computed tomography (CT) with three-dimensional (3D) reconstruction that showed a defect in the anterior cranial base, through which herniated brain could be seen extending into the nasal cavity (Figs. 2 & 3a). 3D reconstruction also showed a defect in the nasion (Fig. 4a). All these features were suggestive of anterior encephalocele of the fronto-nasal type with hypertelorism. She was scheduled for a single stage surgery to correct hypertelorism and repair of dural and anterior cranial fossa defects.

A bicoronal skin incision was marked to gain wide exposure (Fig. 5). A scalp flap was raised and at the same time, a pericranial graft was also harvested to repair the dural defect. The scalp was reflected to expose frontal bone, both supraorbital rims, and the nasal bridge with bony defect (Fig. 6). The frontal sinus was not well developed in our case and did not pose much of a problem in performing the craniotomy. A bifrontal craniotomy (with Hudson's brace and burrs) and bilateral supraorbital orbitotomy (with high speed electric drill) were performed (Fig. 6). The frontal bone flap was removed and a midline piece of frontal bone was removed separately, leaving the lateral part of the nasal bones intact with supraorbital ridges on both sides (Fig. 7). The frontal sinus was rudimentary and did not pose much difficulty. A thin rim of frontal bone was left attached on both sides to the cranium in order to facilitate the fixation of bone flaps. Both supraorbital ridges with lateral part of nasal bones were removed separately (Fig. 8). The basal dura was separated all around the herniating gliotic brain, and

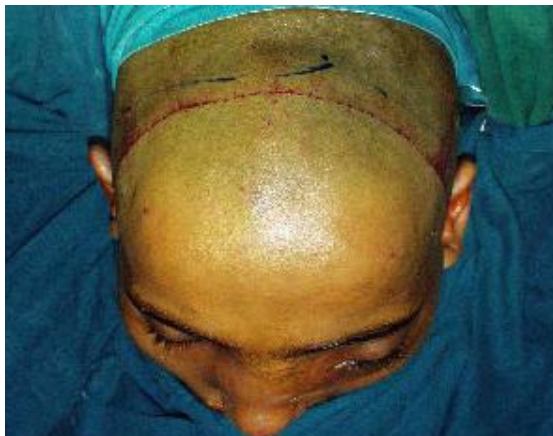distance. She also had a small pulsatile swelling with palpable bony defect and a well-healed scar on the nose, more on the left side, with widening of the nose (Fig. 1). Preoperatively, she was



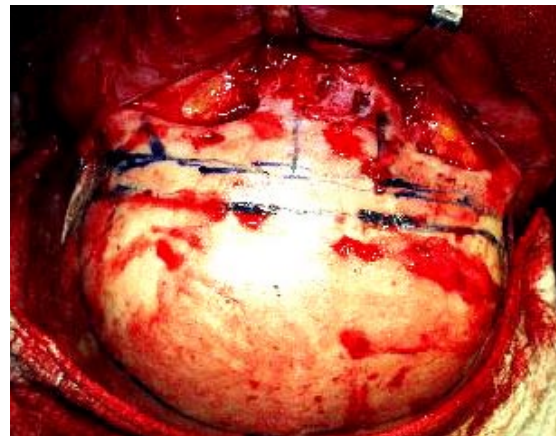
**Fig. 3** Comparative (a) pre- and (b) postoperative coronal CT images shows the graft at the level of the cranial



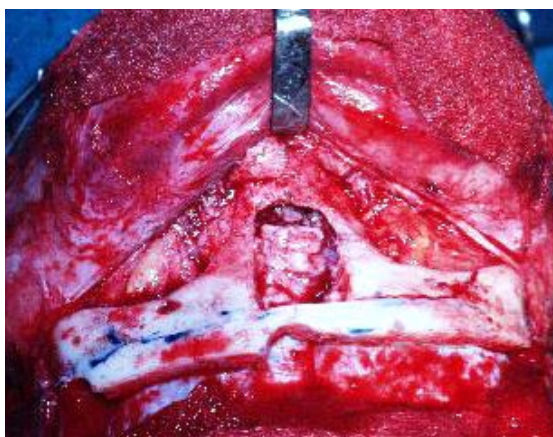**Fig. 4** 3D (a) pre- and (b) postoperative CT images. Preoperative image shows the defect in the nasion that is covered in the postoperative image.



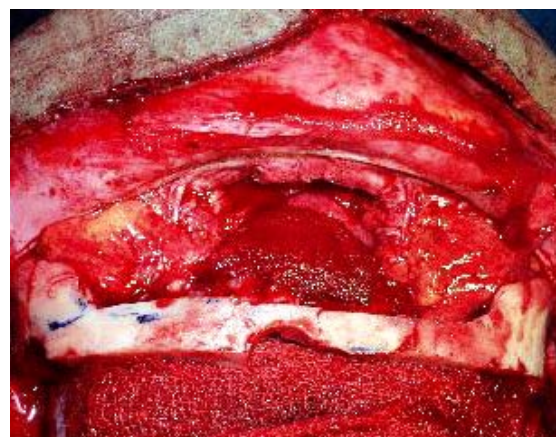**Fig. 5** Clinical photograph shows bicoronal skin incision to gain wide exposure.



**Fig. 6** Clinical photograph shows a widely-exposed frontal bone, bilateral supraorbital rims and defect in the nasal bone. It also shows marking for frontal craniotomy, bilateral orbitotomy and midline frontal calvarial graft.

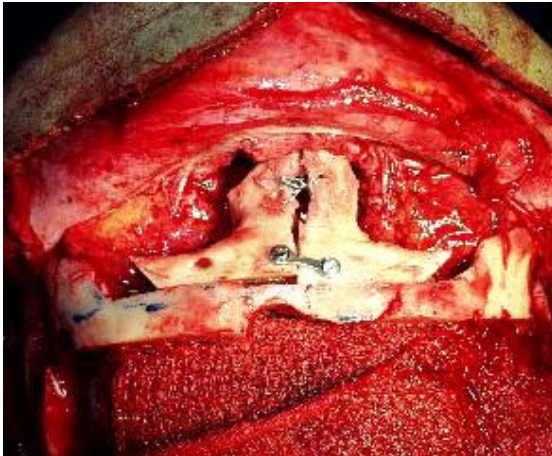

**Fig. 7** Clinical photograph shows part of the frontal bone is removed (later on used as split calvarial graft to reconstruct the cranial base) to expose the herniating brain.

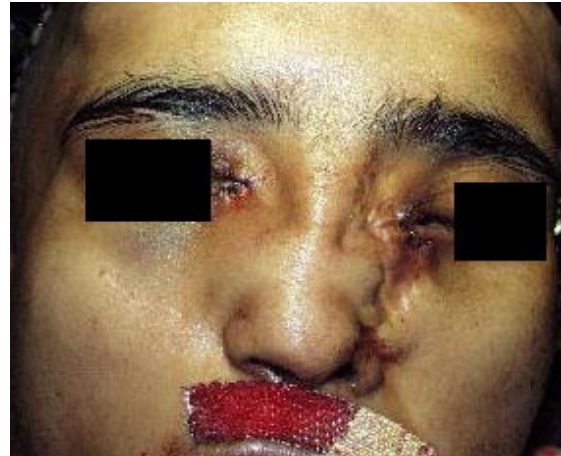

**Fig. 8** Clinical photograph shows rim of the frontal bone attached on both sides to the cranium after removal of the frontal bone and both supraorbital rims.





**Fig. 9** Clinical photograph shows both supraorbital rims with lateral part of nasal bones fixed together with miniplates.



**Fig. 10** Immediate postoperative photograph shows decreased intercanthal distance after medial canthotomy.

the defect was defined through brain tissue that was herniating in the nasal cavity as seen on CT (Figs. 2 & 7). Redundant brain tissue was excised and dural margins were freed all around.

The dural defect was closed with free pericranial graft using prolene 5-0 in a water-tight manner, as it was not possible to put a pedicled pericranial graft deeply. A piece of midfrontal bone, which was removed separately, was used as a split graft to reconstruct the anterior cranial fossa floor as seen in postoperative CT (Fig. 3b). Correction of hypertelorism was performed by shifting both the supraorbital ridges medially and fixing with miniplates (Fig. 9). To provide a firm and immobile skeleton, the supraorbital ridges and frontal bone flap were fixed to the bar of the frontal bone which was left attached to the cranium (Fig. 9). Both medial canthi were repositioned with prolene 3-0 stay sutures (Fig. 10). After achieving haemostasis, the incision was closed in layers. Postoperatively, she recovered uneventfully. There was no cerebrospinal fluid leak and CT with 3D reconstruction showed good positioning of bone fragments (Fig. 3b) and reconstruction of the anterior cranial fossa base (Fig. 4b).

## DISCUSSION

Repair of fronto-nasal encephaloceles in the neonatal period may simplify the required operative procedures,<sup>(7)</sup> even in the large lesions.<sup>(8)</sup> Extracranial pathological findings of interest include herniating brain tissue, facial deformities, and fronto-nasal bone morphology.<sup>(9)</sup> The aim of surgical treatment is to restore the functional brain tissue in the cranial cavity, perform dural repair, correct bone deficiency and restore aesthetic facial appearance safely and successfully in a single stage.<sup>(3,10,11)</sup> In addition to clinical examination, appropriate preoperative imaging will determine the

type of lesion, extent of the lesion (both intracranial and extracranial), and severity of the associated bone defect and cosmetic deformity.<sup>(12,13)</sup> CT with 3D reconstruction will show the extent of the bone defect and will help in surgical planning and repair of these large lesions.<sup>(13,14)</sup> In this case, clinically, the lesion was mainly situated over the bridge of the nose, which was represented by the healed scar of the previous surgery with obvious hypertelorism and cosmetic deformity, which grew over the years with the patient's age (Fig. 1).

In the present case, CT showed details of the bony defect and extent of brain herniation (Figs. 2, 3a & 4a). Repair of these defects involved a multidisciplinary approach, encompassing neurosurgery, plastic surgery, maxillofacial surgery and anaesthesiology.<sup>(10,15)</sup> In comparison to children, management of fronto-nasal encephalocele is a difficult and challenging task in adults. As the age advances, the defect enlarges in size (this could be due to continuous pulsations of the brain), and there will be more gliotic brain tissue herniating into the defect and also an increase in the size of paranasal sinuses (i.e. frontal, in present case). In this case, it was further complicated by the facial scar (from the previous surgery) that had also increased in size over the years. The operative approach utilises a bifrontal craniotomy with resection of the encephalocele intradurally, repair of the anterior cranial fossa dura and osteoplastic repair of the bony defect. Cranial flap with orbital osteotomies permits correction of the hypertelorism and of the orbital dystopia associated with this malformation.<sup>(7,16,17)</sup> Surgery should provide a proper reconstruction to separate the sterile extradural space from the nasal cavity, correction of bony defects including anterior cranial fossa base, resection of gliotic brain tissue and correction of hypertelorism to restore aesthetics. We

used a bicoronal incision to gain wide bifrontal exposure (Fig. 5).

As in the present case, a watertight and durable closure of the dural defect can be achieved by an autologous pericranial graft harvested while reflecting the scalp to prevent complications, such as meningitis, epidural abscess, cerebrospinal fluid leak, and brain herniation.<sup>(18-20)</sup> This can be further reinforced by reconstructing the anterior cranial fossa base with an autologous bone graft.<sup>(21)</sup> We used split calvarial graft from the frontal bone to bridge the defect in the anterior cranial fossa. Bilateral orbital osteotomies were performed to reduce the degree of hypertelorism with canthoplasty. Bone fragments were fixed to the arch of the frontal bone with micro/mini plates to gain rigid support (Fig. 9).<sup>(22)</sup> In bone reconstructions, titanium miniplates can be used safely in adults, but resorbable devices are required in children because of growing tissues.<sup>(10)</sup> A restoration of craniofacial malformations with good aesthetic and functional results can be achieved with early surgery.<sup>(10)</sup> In summary, fronto-nasal encephaloceles present a difficult scenario in adults and is mainly due to large gliotic herniating brain tissue, large bony and dural defect, thick calvarial bones, and scars from previous surgeries. However, all difficulties can be overcome after applying the principles of cranio-facial reconstructions, i.e. correction of bone defect with autologous split calvarial graft, dural closure with autologous pericranial graft and correction of hypertelorism.

## REFERENCES

1. Suwanwela C, Suwanwela N. A morphological classification of sincipital encephalomeningoceles. *J Neurosurg* 1972; 36:201-11.
2. Boonvisut S, Ladpli S, Sujatanond M, et al. Morphologic study of 120 skull base defects in frontoethmoidal encephalomeningoceles. *Plast Reconstr Surg* 1998; 101:1784-95.
3. Mahatumarat C, Rojvachiranonda N, Taecholarn C. Frontoethmoidal encephalomeningocele: surgical correction by the Chula technique. *Plast Reconstr Surg* 2003; 111:556-65.
4. David DJ, Sheffield L, Simpson D, White J. Fronto-ethmoidal meningoencephaloceles: morphology and treatment. *Br J Plast Surg* 1984; 37:271-84.
5. Holmes AD, Meara JG, Kolker AR, Rosenfeld JV, Klug GL. Frontoethmoidal encephaloceles: reconstruction and refinements. *J Craniofac Surg* 2001; 12:6-18.
6. Sargent LA, Seyfer AE, Gunby EN. Nasal encephaloceles: definitive one-stage reconstruction. *J Neurosurg* 1988; 68:571-5.
7. Gussack GS, Schlitt M, Hurley D. Craniofacial approach for the neonatal management of frontonasal encephaloceles. *Int J Pediatr Otorhinolaryngol* 1988; 16:225-35.
8. Satyarthee GD, Mahapatra AK. Craniofacial surgery for giant frontonasal encephalocele in a neonate. *J Clin Neurosci* 2002; 9:593-5.
9. Rojvachiranonda N, David DJ, Moore MH, Cole J. Frontoethmoidal encephalomeningocele: new morphological findings and a new classification. *J Craniofac Surg* 2003; 14:847-58.
10. De Ponte FS, Pascali M, Perugini M, et al. Surgical treatment of frontoethmoidal encephalocele: a case report. *J Craniofac Surg* 2000; 11:342-5.
11. Mahapatra AK. Anterior encephaloceles. *Indian J Pediatr* 1997; 64:699-704.
12. Schlosser RJ, Faust RA, Phillips CD, Gross CW. Three-dimensional computed tomography of congenital nasal anomalies. *Int J Pediatr Otorhinolaryngol* 2002; 65:125-31.
13. Phillips CD. Neuroradiologic imaging in craniofacial surgery. In: Lin KY, Ogle RC, Jane JA, eds. *Craniofacial Surgery: Science and Surgical Technique*. Philadelphia: Saunders, 2002: 153-60.
14. Zinreich SJ, Mattox DE, Kennedy DW, et al. 3-D CT for cranial facial and laryngeal surgery. *Laryngoscope* 1988; 98:1212-9.
15. Georgantopoulou A, Hodgkinson PD, Gerber CJ. Cranial-base surgery: a reconstructive algorithm. *Br J Plast Surg* 2003; 56:10-3.
16. Kraus DH, Shah JP, Arbit E, Galicich JH, Strong EW. Complications of craniofacial resection for tumors involving the anterior skull base. *Head Neck* 1994; 16:307-12.
17. Richtsmeier WJ, Briggs RJ, Koch WM, et al. Complications and early outcome of anterior craniofacial resection. *Arch Otolaryngol Head Neck Surg* 1992; 118:913-7.
18. Antworth MV, Beck RW. Traumatic orbital encephalocele. *Can J Ophthalmol* 1989; 24:129-31.
19. Deschler DG, Gutin PH, Mamelak AN, McDermott MW, Kaplan MJ. Complications of anterior skull base surgery. *Skull Base Surg* 1996; 6:113-8.
20. Koç RK, Kurtsoy A, Oktem IS, Akdemir H. Growing skull fracture of the orbital roof. *Case Report. Pediatr Neurosurg* 1999; 30:35-8.
21. Antonelli V, Cremonini AM, Campobassi A, et al. Traumatic encephalocele related to orbital roof fractures: report of six cases and literature review. *Surg Neurol* 2002; 57:117-25.
22. Chang DW, Robb GL. Microvascular reconstruction of the skull base. *Semin Surg Oncol* 2000; 19:211-7.