

# Stenting before laparoscopic common bile duct exploration: a helpful strategy

Tan T W, Khor C J L, Chang S K Y

## ABSTRACT

We describe a 43-year-old man who had a difficult endoscopic retrograde cholangiopancreatography, allowing only placement of a stent without removal of the common bile duct stone. He subsequently underwent laparoscopic cholecystectomy with laparoscopic common bile duct exploration and primary closure after laparoscopic choledochotomy.

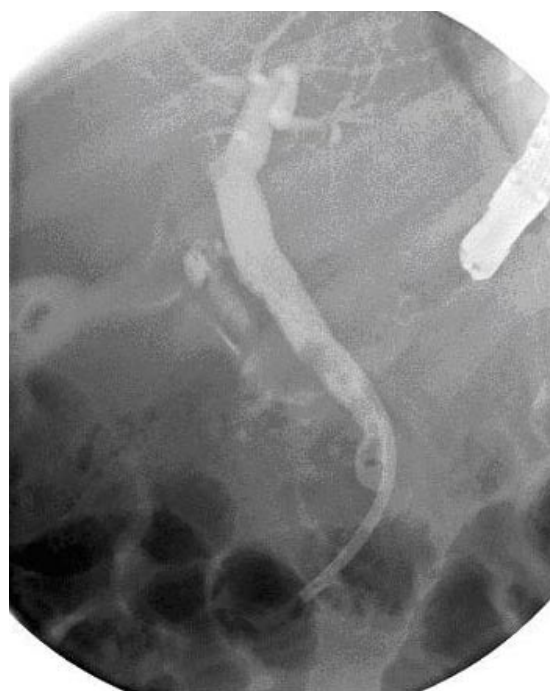**Keywords:** biliary stenting, common bile duct stone, laparoscopic cholecystectomy, laparoscopic common bile duct exploration

*Singapore Med J 2007;48(8):e224–e226*

## INTRODUCTION

In 1987, Mouret performed the first laparoscopic cholecystectomy (LC),<sup>(1)</sup> and since then, it has become the standard operative procedure for gallbladder disease. With the advent of endoscopic retrograde cholangiopancreatography (ERCP), patients with secondary common bile duct (CBD) stone are usually managed with endoscopic stone extraction followed by LC, avoiding open CBD exploration, thereby benefiting from the advantages of the laparoscopic approach. However, an alternative single-stage laparoscopic treatment option, i.e. laparoscopic CBD exploration and cholecystectomy at the same sitting, is gaining prominence.

Numerous studies, including the European Association of Endoscopic Surgery (EAES) multicentre prospective randomised trial by Cuschieri et al, have shown equal efficacy in terms of ductal stone clearance for these two management options.<sup>(2,3)</sup> The latter option is especially attractive in cases of difficult choledocholithiasis (which refers to cases of failed endoscopic stone retrieval), where common bile duct exploration during cholecystectomy is required. Causes of failed endoscopic stone retrieval can be divided into two main groups: (1) failure of cannulation (difficult anatomy due to previous gastrectomy, or due to periampullary diverticulum), and (2) failure of extraction (due to reasons such as impacted stone, CBD stricture).



**Fig. 1** ERCP shows several filling defects within a prominent CBD, suggestive of ductal calculi.

In patients where laparoscopic choledochotomy have to be performed for CBD exploration, contention arises with regard to the traditional practice of T-tube placement; laparoscopic placement of a T-tube is technically more challenging and prolongs hospitalisation. We describe a patient who had failed endoscopic stone retrieval and subsequently underwent LC with laparoscopic common bile duct exploration (LCBDE) without T-tube placement.

## CASE REPORT

A 43-year-old Chinese man with cholelithiasis, which was diagnosed one year ago on ultrasonography of the hepatobiliary system, presented with symptoms of cholangitis. His conjugated bilirubin and alkaline phosphatase were raised at 34  $\mu\text{mol/L}$  and 163 U/L, respectively. Repeat ultrasonography revealed fatty liver and a non-tender non-oedematous gallbladder with an 8 mm gallstone. The CBD was mildly dilated; otherwise the biliary tree was normal. After discussion

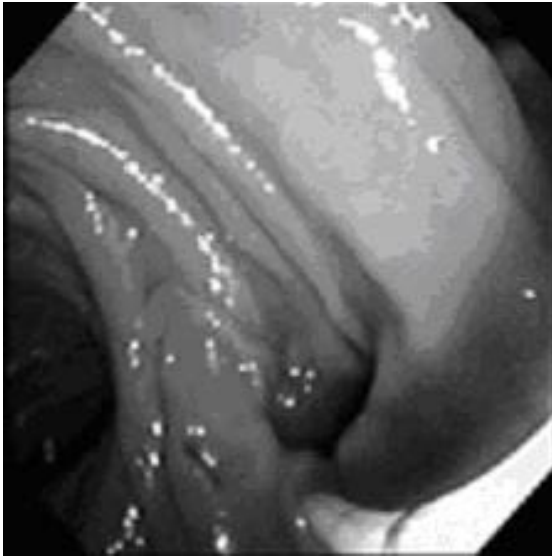
Department of  
Surgery,  
National University  
Hospital,  
5 Lower Kent  
Ridge Road,  
Singapore 119074

Tan TW, MBBS  
Medical Officer

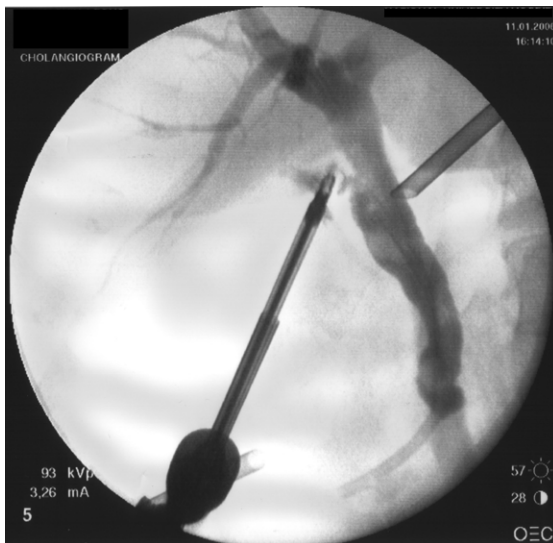Khor CJL, MBBS,  
MRCP  
Consultant

Chang SKY, MBBS,  
MMed, FRCSE  
Consultant

**Correspondence to:**  
Dr Stephen Chang  
Tel: (65) 6772 4225  
Fax: (65) 6777 8427  
Email: surv7@  
nus.edu.sg



**Fig. 2** ERCP shows a perampullary diverticulum.



**Fig. 3** IOC shows multiple filling defects in the CBD.

between the endoscopist and the surgeon, ERCP was performed. This showed a very distally sited major papilla (Fig. 1), inside a small diverticulum (Fig. 2), resulting in difficult biliary access. Cholangiogram revealed filling defects in a mildly-dilated CBD. A plastic biliary stent (10Fr 9 cm) was placed with good drainage but sphincterotomy could not be safely performed to allow stone removal.

The patient improved clinically and underwent LC five days after the ERCP. Intraoperative cholangiography (IOC) was performed (Fig. 3). The CBD was noted to be 12 mm in size with two

stones seen. The cystic duct was long and tortuous. LCBDE was done via an incision in the CBD followed by choledochoscopy. Two pigment stones were retrieved with a Dormia basket. The CBD was further trawled with a Fogarty balloon. A T-tube was then placed and a check cholangiogram confirmed that the CBD was clear of stone, ERCP stent was in-situ, and the contrast was passing through into the duodenum. The T-tube was then removed and the defect in the CBD repaired primarily. The gallbladder was removed and a drain placed in the subhepatic space. The patient made a good recovery and was well when discharged on the third postoperative day. He returned as an outpatient for removal of the biliary stent via a gastroscope eight weeks after the operation.

## DISCUSSION

The incidence of perampullary diverticulum has been reported to be 11.5%. Attempted ERCP cannulation failed in 79.2% of these patients, compared to 9.7% among those without diverticulum.<sup>(4)</sup> It is not common to have a patient with a perampullary diverticulum and who has an ampulla that can be cannulated, and yet having an anatomy that is dangerous for sphincterotomy. Our case therefore illustrates that even if removal of stone cannot be achieved through ERCP, leaving a stent behind will help the surgeon who will be operating on the patient subsequently. As far as we know, this method has not been published in the English literature before.

However, we note that there are other methods to tackle our patient's problem of difficult choledocholithiasis. They include:

- 1) Leaving the stent in-situ for a few weeks before re-attempting ERCP. This is a feasible technique where in some cases the stones may even fragment and be allowed passage through into the duodenum. This method will however require at least one further procedure prior to the eventual LC.
- 2) Performing CBD exploration without stenting. This procedure has been well-tried. This, however, risks developing a leak at the CBD repair site especially when sphincterotomy cannot be done.
- 3) Endonasobiliary drainage is another way to stent the traumatised bile duct, but this adds to the discomfort of the patient, and in most cases, will still require the patient to stay in the hospital during the period when the drainage tube is still in-situ.

Tai et al reported 100% stone clearance rate with laparoscopic exploration of the CBD (LCBDE) in difficult choledocholithiasis.<sup>(5)</sup> They also found that the complication rate, rate of stone clearance, and hospital stay, was comparable to patients with LCBDE

for non-difficult stones, although a longer operation time was required. The traditional practice of T-tube drainage after CBD exploration was first described by Deaver in 1904.<sup>(6)</sup> The advantages of using a T-tube include: (1) decompression of the CBD to reduce the chances of a postoperative bile leak; (2) providing access for cholangiography for the detection of retained stones; and (3) providing access for removal of retained stones. As early as 1917, Halsted had already described the use of primary closure after exploration of the CBD.<sup>(7)</sup> Primary closure helps circumvent the numerous associated disadvantages of T-tube placement. These include: inconvenience, discomfort, longer hospital stay, mechanical problems (dislodgement of T-tubes, etc), duct stenosis after T-tube removal, and risk of cholangitis from an external source via the T-tube.

Through the years, there have been much debate between the options of primary closure and T-tube drainage. However, many recent studies have shown that primary closure may be better. Ha et al described a retrospective study of 38 patients who underwent successful laparoscopic choledochotomy.<sup>(8)</sup> 12 (32%) of them underwent primary closure and 26 (68%) patients underwent closure with T-tube drainage. The median operation time, as well as the median hospital stay, were significantly shorter in the group who underwent primary closure. The postoperative complication rate was also lower in the primary closure group compared to the T-tube group, though this was not statistically significant. Some authors have proposed a third method of closure after CBD exploration. Lange et al first reported antegrade CBD stenting with primary closure in 1993.<sup>(9)</sup> Subsequently, many studies have shown the potential advantages of antegrade stenting, including decompression of the CBD, facilitation of ERCP cannulation of the CBD postoperatively, and early return to full activity.<sup>(10,11)</sup> However, it has its own disadvantages – such as being technically challenging and the patient is subjected to an ERCP for stent removal four to six weeks postoperatively.

Our patient was not considered for antegrade stenting after LCBDE since he already had a biliary stent inserted during his prior ERCP. This allowed him to benefit from the decompressive effects of a biliary stent in the CBD, and at the same time avoid the problems of a T-tube. Thus, we recommend that in cases of difficult ERCP in patients with CBD stones, an attempt at placement of a biliary stent is beneficial, if removal of the stone(s) is impossible. However, we will still need further prospective studies with a larger number of cases to help us identify the best management option. In conclusion, ERCP in patients with periampullary diverticulum is often difficult, and LCBDE is a feasible procedure with high success rates in terms of stone clearance. Finally, placement of a biliary stent in cases of difficult ERCP helps to make the current trend of primary closure after laparoscopic choledochotomy more appealing, both to the patient and the surgeon.

## REFERENCES

1. Mouret P. From the first laparoscopic cholecystectomy to the frontiers of laparoscopic surgery: The prospective futures. *Dig Surg* 1991; 8:124.
2. Cuschieri A, Lezoche E, Morino M, et al. E.A.E.S. multicenter prospective randomized trial comparing two-stage vs single-stage management of patients with gallstone disease and ductal calculi. *Surg Endosc* 1999; 13:952-7.
3. Rhodes M, Sussman L, Cohen L, Lewis MP. Randomised trial of laparoscopic exploration of common bile duct versus postoperative endoscopic retrograde cholangiography for common bile duct stones. *Lancet* 1998; 351:159-61.
4. Rajnakova A, Goh PM, Ngoi SS, Lim SG. ERCP in patients with periampullary diverticulum. *Hepatogastroenterology* 2003; 50:625-8.
5. Tai CK, Tang CN, Ha JP, et al. Laparoscopic exploration of common bile duct in difficult choledocholithiasis. *Surg Endosc* 2004; 18:910-4.
6. Deaver JB. The surgery of jaundice. *Ann Surg* 1925; 81: 287-98.
7. Halsted WS. *Surgical Papers*. Vol 2. Baltimore: Johns Hopkins University Press, 1924: 427-72.
8. Ha JP, Tang CN, Siu WT, Chau CH, Li MK. Primary closure versus T-tube drainage after laparoscopic choledochotomy for common bile duct stones. *Hepatogastroenterology* 2004; 51:1605-8.
9. Lange V, Rau HG, Schardey HM, Meyer G. Laparoscopic stenting for protection of common bile duct sutures. *Surg Laparosc Endosc* 1993; 3:466-9.
10. Gersin KS, Fanelli RD. Laparoscopic endobiliary stenting as an adjunct to common bile duct exploration. *Surg Endosc* 1998; 12:301-4.
11. Martin IJ, Bailey IS, Rhodes M, et al. Towards T-tube free laparoscopic bile duct exploration: a methodologic evolution during 300 consecutive procedures. *Ann Surg* 1998; 228:29-34.