

Additional flexor muscles of the forearm: case report and clinical significance

Nayak S R, Ramanathan L, Prabhu L V, Raju S

ABSTRACT

Anomalous muscles usually do not cause symptoms but are of academic interest. They become a surgical problem when they produce symptoms or are difficult to differentiate from soft tissue tumours. During routine cadaveric dissection for the undergraduate students at the Kasturba Medical College, Mangalore, we came across two additional muscles in the deep flexor compartment of the right forearm of a 69-year-old woman. The anomalous muscles were located on the ventral aspect of the proximal forearm, in a plane deep to the flexor digitorum superficialis (FDS). Both the muscles originated from the deep surface of the FDS. The muscle on the radial side was a Gantzer's muscle as it was inserted into the tendon of the flexor pollicis longus. The muscle on the ulnar side formed an independent tendon for the middle finger, 14 cm above the proximal edge of the flexor retinaculum and passed through the carpal tunnel; surprisingly the tendon of the additional muscle and flexor digitorum profundus tendon for the middle finger gave origin to the second lumbrical in the carpal tunnel. The passive traction on the tendon of the additional muscle resulted in flexion of the distal and medial phalanges. The presence of such an additional tendon and origin of lumbrical muscle in the carpal tunnel should be considered in the aetiology of carpal tunnel syndrome.

Keywords: additional flexor muscles, carpal tunnel syndrome, flexor digitorum profundus, Gantzer's muscle, lumbrical muscle

Singapore Med J 2007;48(8):e231–e233

INTRODUCTION

The flexor digitorum superficialis (FDS) muscles have been termed as retrogressive, as they represent remnants of the connections between two sheets of muscles. Thus,

a slip very frequently connects superficialis with the long flexor of the thumb (flexor pollicis longus [FPL]) or flexor digitorum profundus (FDP) as muscular slips occasionally pass between superficialis and deep flexors of the fingers. Sometimes a muscular slip derived but separated from the superficialis, or on a tendon that joins one of the tendons of the deep flexor accessorius profundus digitorum (Gantzer) is found. On the other hand, the occasional separation (up to their origins) of individual muscle bellies has been considered a progressive variation.⁽¹⁾ However, the deep flexors of the fingers usually arise from the medial and anterior surfaces of the upper three-quarters of the body of the ulna and the adjacent interosseous membrane.^(2,3) The presence of a Gantzer's muscle and an additional deep flexor tendon to the middle finger from the FDS, makes the present case unique.

Kopuz et al reported a distal and complete additional FDP muscle to the index finger bilaterally from the distal part of the forearm.⁽⁴⁾ Prescher found an accessory twin-bellied muscle in both forearms. On the right side, the accessory muscle originated from the main muscle belly of the superficial flexor muscle of the fingers and inserted on the index finger tendon of the superficial muscle.⁽⁵⁾ On the left side, the accessory muscle belly originated from the medial epicondyle of the humerus and inserted on the index finger tendon of the superficial muscle. Although the Gantzer's muscle present in a higher percentage, 50%–66%,^(6,7) the presence of an additional deep flexor to the middle finger capable of independent flexion, is vague in the modern literature. The origin of a second lumbrical high up in the carpal tunnel from the additional tendon makes the present case more interesting. The present findings will add to our knowledge of FDS muscle variation and probable cause of carpal tunnel syndrome.

CASE REPORT

During a routine dissection of a 69-year-old female cadaver, we observed two additional muscles arising from the undersurface of the FDS muscle, 2.8 cm distal to its origin from the medial epicondyle. The muscle on the radial side was to be a Gantzer's muscle, as it was extended

Department of Anatomy,
Centre for Basic Sciences,
Kasturba Medical College,
Bejai,
Mangalore 575004,
Karnataka,
India

Nayak SR, MSc
Lecturer

Ramanathan L, MD
Assistant Professor

Prabhu LV, MS
Professor and Head

Raju S, MSc
Postgraduate Student

Correspondence to:
Mr Soubhagya
R Nayak
Tel: (91) 824 221 1746
Fax: (91) 824 242 1283
Email: ranjanbhatana@gmail.com

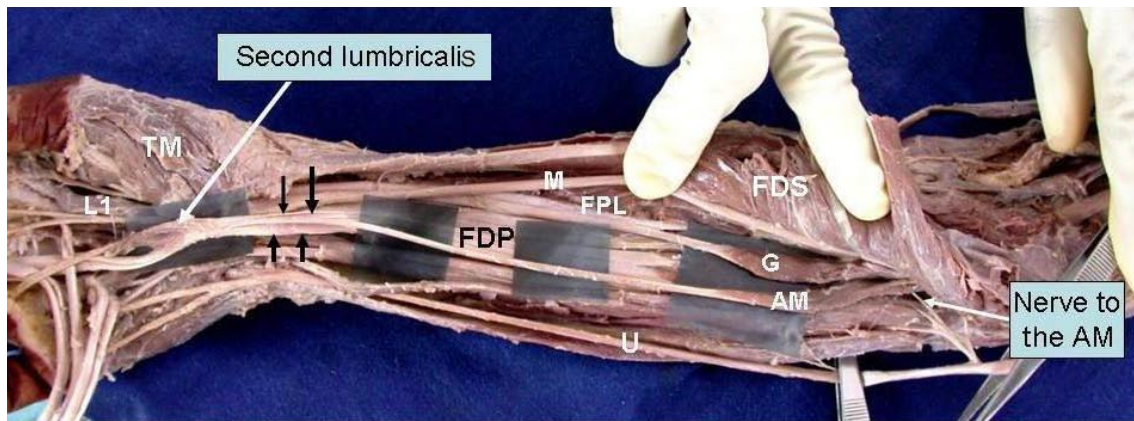


Fig. 1 Photograph shows the ventral view of the right forearm and hand. Superficial muscles are reflected to show the additional muscle and Gantzer's muscle.

G: Gantzer's muscle; AM: Additional flexor muscle; U: Ulnar nerve; FPL: Flexor pollicis longus; FDP: Flexor digitorum profundus; TM: Thenar muscles; FDS: Flexor digitorum superficialis; M: Median nerve; L1: First lumbrical muscle. Downward arrows indicate the tendon of the additional muscle to the middle finger; upward arrows indicate the tendon of flexor digitorum profundus to the middle finger. *Note the high origin of second lumbrical muscle in the carpal tunnel.

to the ulnar side of the FPL, 13.4 cm proximal to the radial styloid process. The muscle was 7.4 cm in length and 0.9 cm in width, and was innervated by a branch from the anterior interosseous nerve. The muscle on the ulnar side took a different course; 8 cm from its origin, the muscle belly converted into a tendon and was accompanied by the median nerve on its radial side. 14 cm above the proximal edge of the flexor retinaculum, the tendon was lying on the radial side of the tendon of FDP muscle in the carpal tunnel. The second lumbrical muscle originated from the tendon, high up in the carpal tunnel. The additional muscle was innervated by a branch from the ulnar nerve, 2.2 cm distal to the medial epicondyle (Fig. 1) and the passive traction on the tendon of the additional muscle resulted in the flexion of the distal and middle phalanges. The tendon then accompanied the profundus tendon to the middle finger on its radial side.

DISCUSSION

The anatomical variations and abnormalities of the muscles on the forearm and hand have become easier to detect because of new imaging techniques, such as computed tomography and magnetic resonance imaging. Also, identifying these variations is important to defining the anatomical features for clinical diagnosis and surgical procedures.⁽⁴⁾ An anomalous muscle may simulate a ganglion^(8,9) or a soft tissue tumour,^(10,11) or if in close proximity to a nerve, it may cause pressure neuritis and produce symptoms such as a carpal tunnel syndrome.⁽¹²⁾ Anomalous muscles in the flexor compartment of the forearm are quite common, but the presence of an additional deep flexor

to the middle finger has not been reported in modern literature. The origin of the second lumbrical muscle from the tendon in the carpal tunnel can be a cause of carpal tunnel syndrome. Compression of the median nerve as it lies in the carpal tunnel can be due to different reasons. Structural compression of the median nerve can cause carpal tunnel syndrome. Possible causes of such a compression include: synovitis and ganglions,⁽¹³⁾ lumbrical muscles originating from the distal part of the forearm,⁽¹⁴⁾ aberrant muscles and tumours,⁽¹⁵⁾ as well as anatomical anomalies, such as a persistent median artery.⁽¹⁶⁾ Entire grouped causes of carpal tunnel syndrome into three categories: those reducing the capacity of the tunnel; those increasing the volume of its contents; and those that form part of a systemic condition.⁽¹⁷⁾ The additional flexor tendon and the second lumbrical muscle found in the carpal tunnel in the present case increase the volume of the carpal tunnel and may cause carpal tunnel syndrome. Furthermore, the presence of additional muscles and their tendons may confuse the surgeons while accessing the forearm and hand. The present findings will supplement our knowledge of muscle variations in the antebrachial and carpal regions and should also be considered in the aetiology of carpal tunnel syndrome.

REFERENCES

- Bergman RA, Afifi AK, Miyauchi R. Illustrated encyclopaedia of human anatomic variation: opus I: muscular system: alphabetical listing of muscles: flexor digitorum superficialis, 2006. Available at: www.Anatomyatlases.org/AnatomicVariants/MuscularSystem/Text/F/17Flexor.shtml. Accessed September, 2006.
- Hollinshead HW. Anatomy for Surgeons. 2nd ed. Vol 3. Hagerstown, MD: Harper and Row, 1969: 408-9.
- Salmons S. Muscle. In: Williams PL, Dyson M, Bannister LH, et al, eds. Gray's Anatomy, 38th ed. London: Churchill Livingstone, 1995: 847-8.

4. Kopuz C, Fidan B, Islam A. An unusually distal and complete additional flexor profundus muscle to the index finger. *J Anat* 1997; 191:465-7.
5. Prescher A. [Rare muscle variations of the forearm]. *Handchir Mikrochir Plast Chir* 1987; 19:210-1. German.
6. al-Qattan MM. Gantzer's muscle. An anatomical study of the accessory head of the flexor pollicis longus muscle. *J Hand Surg* 1996; 21:269-70.
7. Oh CS, Chung IH, Koh KS. Anatomical study of the accessory head of the flexor pollicis longus and the anterior interosseous nerve in Asians. *Clin Anat* 2000; 13:434-8.
8. Jones BV. An anomalous extensor indicis muscle. *J Bone Joint Surg Br* 1959; 41:763-5.
9. Thomas CG. Clinical manifestations of an accessory palmaris muscle. *J Bone Joint Surg Am* 1958; 40:929-30.
10. Lipscomb PR. Duplication of hypothenar muscles simulating soft-tissue tumour of the hand. Report of a case. *J Bone Joint Surg Am* 1960; 42:1058-61.
11. Dunn AW. Anomalous muscles simulating soft-tissue tumors in the lower extremities. Report of three cases. *J Bone Joint Surg Am* 1965; 47:1379-400.
12. Ashby BS. Hypertrophy of the palmaris longus muscle. Report of a case. *J Bone Joint Surg Br* 1964; 46:230-2.
13. Jamadar DA, Jacobson JA, Hayes CW. Sonographic evaluation of the median nerve at the wrist. *J Ultrasound Med* 2001; 20:1011-4.
14. Singh G, Bay BH, Yip GW, Tay S. Lumbrical muscle with an additional origin in the forearm. *ANZ J Surg* 2001; 71:301-2.
15. Ninkovic M, Hefel L, Ohler K. Acute median nerve compression produced by reversed palmaris longus muscle. *Eur J Plast Surg* 1995; 18:129-30.
16. Chalmers J. Unusual cases of peripheral nerve compression. *Hand* 1978; 10:168-75.
17. Entin MA. Carpal tunnel syndrome and its variants. *Surg Clin North Am* 1968; 48:1097-112.