

# Acute pulmonary embolism following Achilles tendon repair

Yusof M I

## ABSTRACT

**Achilles tendon injury is common and surgical procedures related to it are frequently performed and are safe. The incidence of acute pulmonary embolism following these procedures is extremely rare. This case illustrates an incidence of acute pulmonary embolism following Achilles tendon repair in a 35-year-old woman. We discuss the possible causes and the need for thromboprophylaxis.**

**Keywords: Achilles tendon, cast immobilisation, pulmonary embolism, surgical complication, thromboprophylaxis**

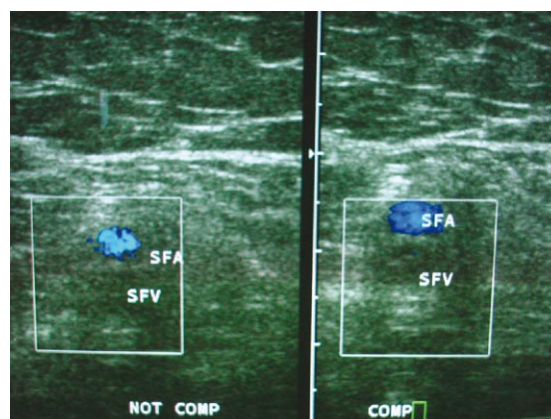
*Singapore Med J 2007;48(8):e234–e236*

## INTRODUCTION

Having a major complication develop following a simple surgical procedure is disastrous. Achilles tendon injury is commonly encountered and surgical repair has long been considered safe. It is a short procedure, with bloodless surgery and requires minimal surgical skills. Postoperative cast immobilisation is necessary to protect the repaired tendon. To our knowledge, there are not many reports on the incidence of symptomatic pulmonary embolism (PE) following this procedure, even though incidence of asymptomatic deep vein thrombosis (DVT) on prolonged cast immobilisation has recently been reported. We report a rare case of a young adult patient, who developed an acute PE after seven days on full length cast following Achilles tendon repair. We discuss the possible contributing causes, precautions and the possible need of thromboprophylaxis in the prevention of DVT and its complications.

## CASE REPORT

A 35-year-old female teacher presented with a painful right heel after a fall. She was able to walk despite the pain and she went to work as usual. She was admitted after two weeks when the pain did not subside. She was asthmatic but was not on any treatment at presentation. The last asthmatic attack was many years before. She was not obese, not on oral contraception, and did not smoke. On examination, she was found to



**Fig. 1** Colour Doppler ultrasonographical images of the patient's right thigh. The right superficial femoral vein (SFV) appears more echogenic, devoid of flow and not fully compressible. It extends from just above the adductor canal to the popliteal vein.

have rupture of her right Achilles tendon. She was fit for general anaesthesia and agreed to have surgical repair. She was operated on the 17th day post-injury. The procedure was done under general anaesthesia with the patient in supine position. A tourniquet was inflated to 300 mmHg after the leg was elevated for five minutes. Esmarquet bandage was not used. Her right leg was put in a figure-of-four position and the tendon repair was performed via a medial incision. The procedure took about 50 minutes. There was no intraoperative problem encountered by both the surgeon and the anaesthetist. She was extubated uneventfully and transferred to a general ward, with an above knee plaster of paris (POP) cast applied to protect the repaired tendon.

She was discharged from the hospital after two days' observation. She did not complain of any calf or leg pain and she had no episode of respiratory distress before discharge. However, she suddenly developed severe dyspnoea at home seven days post-surgery, that required her to be admitted. She was hypoxic and electrocardiography showed tachycardia with evidence of right-sided strain. Doppler ultrasonography of the affected leg showed the presence of a thrombus from just above the adductor canal to the popliteal vein (Fig. 1). Blood investigation showed negative

Department of  
Orthopaedics,  
School of Medical  
Science,  
Universiti Sains  
Malaysia,  
Jalan Raja  
Perempuan Zainab 2,  
Kubang Kerian 16150,  
Kelantan,  
Malaysia

Yusof MI, MMed  
Surgeon and Lecturer

Correspondence to:  
Dr Mohd Imran Yusof  
Tel: (60) 9 766 3000  
ext. 4512  
Fax: (60) 9 766 4510  
Email: drimran@  
kb.usm.my;  
drimran93@  
yahoo.com

antinuclear antibody and non-reactive Venereal Disease Research Laboratory tests. Unfortunately, she refused computed tomography to be performed on her. A diagnosis of acute PE was made, and treatment using a standard regime of anti-coagulant was given. Arterial blood gases and bleeding profiles were monitored closely. The patient became more comfortable and asymptomatic. There was no calf tenderness, difficulty in breathing or bleeding disorder noted during the treatment. Heparin infusion was later changed to oral warfarin. The above-knee POP cast was converted to a lighter below knee fibreglass cast to encourage mobilisation. She was discharged after 12 days with regular follow-up.

## DISCUSSION

The incidence of DVT and PE following orthopaedic procedures, particularly total knee and total hip replacements, are well known. In Malaysia, the incidence is not rare, contrary to common belief. Dhillon et al reported a 64.3%-76.5% incidence of DVT after these procedures and 50% incidence following lower limb fractures.<sup>(1)</sup> The incidence of PE following Achilles tendon rupture and repair is not commonly reported,<sup>(2)</sup> as they might not be included under orthopaedic audit.<sup>(3)</sup> Without known risk factors, the risks to develop DVT and PE are almost unknown. This complication is relatively rare, compared to other complications, like tendon re-rupture or skin breakdown,<sup>(4)</sup> and its occurrence is difficult to predict. Mandelbaum et al reported a 3% incidence of PE following similar procedure among athletes.<sup>(5)</sup> Nestorson et al reported a 4% incidence of DVT among patients above 65 years, even though none developed PE.<sup>(6)</sup> For patients with Achilles tendon injury treated non-operatively, Ingvar et al reported a 3.9% incidence of DVT, with less than 1% incidence of PE during a four-year follow-up period.<sup>(7)</sup>

PE can be a clinical manifestation of unrecognised thrombosis syndromes. A rare case of Achilles tendon injury, complicated with DVT and massive PE associated with antiphospholipid syndrome, has been reported.<sup>(8)</sup> Thus, it is necessary for all patients who develop DVT with or without PE to be investigated further for the possibility of rare underlying causative factors. The causative factor for DVT in our patient could not be ascertained. Although our patient was asthmatic, it is not known to be a risk factor, despite the fact that DVT has been reported in an asthmatic child.<sup>(9)</sup> A possible risk factor for her was the period of cast immobilisation of the affected leg following the surgical procedure. Prolonged leg immobilisation (4-6 weeks) in a cast

has been reported to be associated with DVT, with an incidence of between 4% and 19%.<sup>(10-12)</sup> In another report, from 691 patients who developed PE, 22 patients were identified to have sustained isolated extremity injuries and immobilised in a plaster cast; only one patient had Achilles tendon injury and repair.<sup>(3)</sup> Nevertheless, the combination of general anaesthesia,<sup>(13)</sup> use of a tourniquet<sup>(14)</sup> and a period of immobilisation in a cast can be sufficient for thrombus formation and embolisation. Showers of emboli have been demonstrated following tourniquet deflation.<sup>(15)</sup>

The issue of thromboprophylaxis is controversial, even in patients with total hip replacement, especially in Asian patients. Murray et al, in their meta-analysis involving a total of 130,000 patients, has demonstrated that there is not enough evidence in the literature to conclude that any form of pharmacological thromboprophylaxis decreases the death rate after total hip replacement.<sup>(16)</sup> Probably, PE associated with total hip replacement and prolonged cast immobilisation is different aetiologically, resulting in its relative resistance to antithrombotic prophylaxis. Femoral vein thrombosis occurs frequently in a hip arthroplasty patient, due to intense systemic activation of the clotting cascade, associated with local vessel injury and local stasis in the femoral vein. This condition may not be found in other conditions associated with PE.<sup>(17)</sup> Since reports of DVT associated with cast immobilisation are available and the incidence is considerably high,<sup>(1,10-12)</sup> thromboprophylaxis for patients with lower limb injuries that require cast immobilisation should be considered. The incidence of DVT was found to be two to four times more common in those without thromboprophylaxis, and was significantly reduced in those who received low molecular weight heparin as DVT prophylaxis. It was shown to be effective and safe in reducing risk of DVT in outpatients with plaster cast immobilisation of the leg.<sup>(10-12)</sup>

Patients should be warned before surgery of the risks of postoperative DVT and PE, especially when it involves general anaesthesia, tourniquet use and postoperative cast immobilisation. Thromboprophylaxis for high-risk patients with lower limb injuries requiring cast immobilisation should be considered. These high-risk patients include obese patients, smokers and those who are on oral contraception. Postoperative Doppler ultrasonography should also be considered for these patients, to identify asymptomatic DVT. Given the rarity of DVT and PE following this injury and procedure, it is also prudent to exclude underlying predisposing conditions in the event that DVT is discovered in such patients.

## REFERENCES

1. Dhillon KS, Askander A, Doraisamy S. Postoperative deep-vein thrombosis in Asian patients is not a rarity: a prospective study of 88 patients with no prophylaxis. *J Bone Joint Surg Br* 1996; 78:427-30.
2. Volpicello C. Pulmonary embolism after repair of a traumatic Achilles tendon rupture. *AORN J* 1996; 64:599-601.
3. Clarke AM, Winson IG. Does plaster immobilization predispose to pulmonary embolism? *Injury* 1992; 23:533-4.
4. Kellam JF, Hunter GA, McElwain JP. Review of the operative treatment of Achilles tendon rupture. *Clin Orthop Relat Res* 1985; 201:80-3.
5. Mandelbaum BR, Myerson MS, Forster R. Achilles tendon ruptures. A new method of repair, early range of motion, and functional rehabilitation. *Am J Sports Med* 1995; 23:392-5.
6. Nestorson J, Movin T, Möller M, Karlsson J. Function after achilles tendon rupture in the elderly: 25 patients older than 65 years followed for 3 years. *Acta Orthop Scand* 2000; 71:64-8.
7. Ingvar J, Tägil M, Eneroth M. Nonoperative treatment of Achilles tendon rupture: 196 consecutive patients with a 7% re-rupture rate. *Acta Orthop* 2005; 76:597-601.
8. Spanodimos SG, Antonatos DG, Sotirellos KT, et al. Double thrombolysis with rt-PA in a patient with massive pulmonary embolism and antiphospholipid syndrome. *Hellenic J Cardiol* 2002; 43:253-61.
9. Matthew DJ, Levin M. Pulmonary thromboembolism in children. *Intensive Care Med* 1986; 12:404-6.
10. Kock HJ, Schmit-Neuerburg KP, Hanke J, Rudofsky G, Hirche H. Thromboprophylaxis with low-molecular-weight heparin in outpatients with plaster-cast immobilisation of the leg. *Lancet* 1995; 346:459-61.
11. Kujath P, Spannagel U, Habscheid W. Incidence and prophylaxis of deep venous thrombosis in outpatients with injury of the lower limb. *Haemostasis* 1993; 23 Suppl 1:20-6.
12. Lassen MR, Borris LC, Nakov RL. Use of the low-molecular-weight heparin reviparin to prevent deep-vein thrombosis after leg injury requiring immobilization. *N Engl J Med* 2002; 347:726-30.
13. Davis FM, Laurenson VG, Gillespie WJ, et al. Deep vein thrombosis after total hip replacement. A comparison between spinal and general anaesthesia. *J Bone Joint Surg Br* 1989; 71:181-5.
14. Hofmann AA, Wyatt RW. Fatal pulmonary embolism following tourniquet inflation. A case report. *J Bone Joint Surg Am* 1985; 67:633-4.
15. Berman AT, Parmet JL, Harding SP, et al. Emboli observed with use of transesophageal echocardiography immediately after tourniquet release during total knee arthroplasty with cement. *J Bone Joint Surg Am* 1998; 80:389-96.
16. Murray DW, Britton AR, Bulstrode CJ. Thromboprophylaxis and death after total hip replacement. *J Bone Joint Surg Br* 1996; 78:863-70.
17. Gitel SN, Salvati EA, Wessler S, Robinson HJ, Worth MH. The effect of total hip replacement and general surgery on antithrombin III in relation to venous thrombosis. *J Bone Joint Surg Am* 1979; 61:653-6.