

Intestinal atresia of co-twin after spontaneous cessation of blood flow through an acardiac twin

Wong H F, Tan T Y T, Kwek K, Low Y, Yeo S H

ABSTRACT

A 33-year-old woman was diagnosed at 15 weeks gestation with a twin pregnancy complicated by an acardiac acephalic foetus. The patient opted for expectant management with close foetal surveillance. Serial ultrasonography showed polyhydramnios at 22 weeks gestation. However, subsequent scans over the next two weeks showed cessation of blood flow in the acardiac foetus, decreasing size of the foetal mass, as well as gradual resolution of the polyhydramnios. Subsequent follow-up was rather uneventful and she underwent an uncomplicated elective caesarean section at 35 weeks, resulting in a healthy 2,820 g girl. The baby was found to have intestinal atresia at birth. She underwent surgery successfully and was well when discharged. The possible causes and pathophysiology of intestinal atresia are discussed.

Keywords: acardiac twins, intestinal atresia, monochorionic monoamniotic twin pregnancy, polyhydramnios

Singapore Med J 2007;48(9):862-865

INTRODUCTION

Acardiac twin pregnancy is caused by reversed arterial perfusion through vascular anastomoses between two cord insertions in a monochorionic placenta, characterised by a partial or complete lack of cardiac development in one of the twins.⁽¹⁾ Acardiac twin pregnancies are at risk of miscarriage and preterm labour associated with perinatal morbidity and mortality. The pathophysiology of such complications are mediated through increased blood flow through the acardiac twin, especially when the mass is large, resulting in possible polyhydramnios and hydropic changes in the pump twin. As such, treatment for acardiac twin pregnancy is indicated when poor prognostic signs, such as increased mass of acardiac twin, polyhydramnios and hydrops, are present. In the absence of such poor prognostic signs, it remains

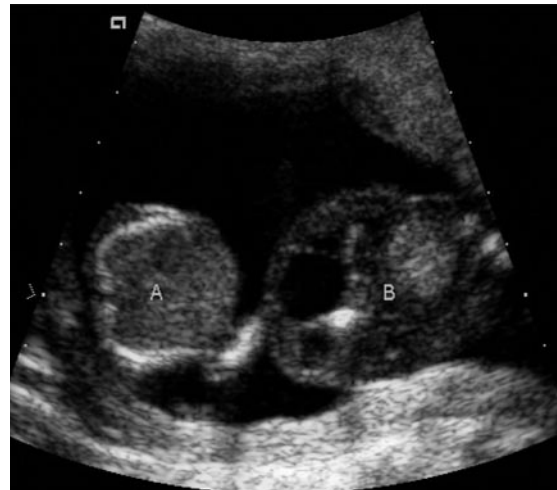

Fig. 1 Antenatal US image taken at 15 weeks gestation shows a cardiac mass (A) and the pump twin (B).

controversial whether prophylactic treatment or expectant management is the better strategy.

A policy of routine early prophylactic treatment aimed at interrupting the vascular anastomoses may be unnecessary in up to 50% of acardiac pregnancies, with rates of procedure-related preterm delivery or premature rupture of membranes from between 23% and 58% (either intrafoetal ablation – 23% or cord occlusion techniques – 58%).⁽²⁾ On the other hand, expectant management may be associated with treatment being indicated at a later gestation during which blood flow cessation may be more difficult to achieve technically. We report a case of acardiac twin pregnancy with spontaneous cessation of blood flow through the acardiac twin, but which was complicated by the postnatal detection of intestinal atresia in the other twin.

CASE REPORT

A 33-year-old woman, with a past obstetrical history of two previous normal pregnancies that culminated in full term vaginal deliveries, had a early dating scan at six weeks showing a viable singleton foetus. Subsequent ultrasonography at 15 weeks showed a viable foetus and an acardiac twin, and was referred

Department of
Maternal-Foetal
Medicine,
KK Women's and
Children's Hospital,
100 Bukit
Timah Road,
Singapore 229899

Wong HF, MBBS,
MRCOG
Registrar

Tan TYT, MBBS,
MMed, MRCOG
Consultant

Kwek K, MBBS,
MMed, MRCOG
Senior Consultant

Yeo SH, MBBS,
FRCOG, FAMS
Associate Professor

Department of
Paediatric Surgery

Low Y, MBBS,
FRCSE, FAMS
Consultant

Correspondence to:
Dr Wong Heng Fok
Tel: (65) 6394 1005
Fax: (65) 6398 6343
Email: hfwong_1972
@yahoo.com

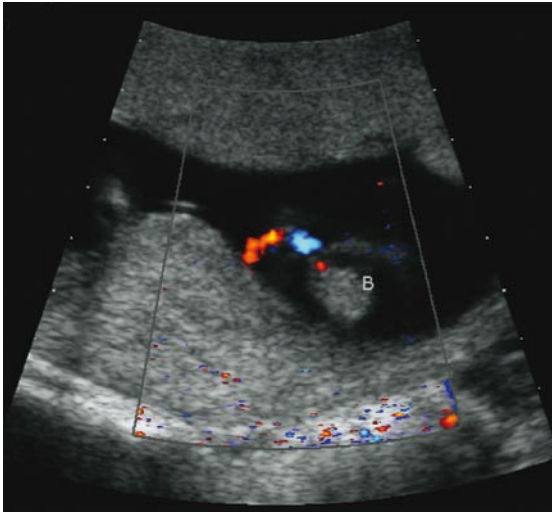


Fig. 2 Colour Doppler US image taken at 15 weeks gestation shows reversed arterial perfusion through Twin B.

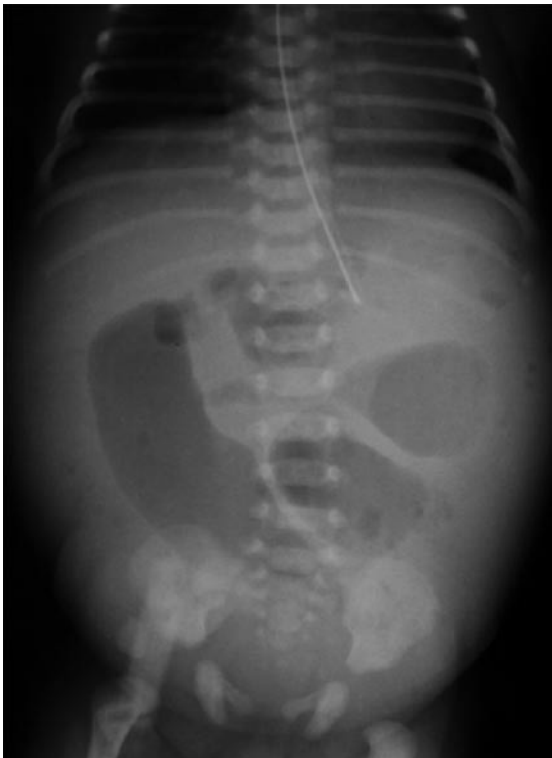

Fig. 3 Abdominal radiograph shows dilated small bowel loops in the neonate.

to the foetal medicine unit in our hospital. Repeat ultrasonography at 15 weeks at our hospital confirmed a monochorionic monoamniotic twin pregnancy, complicated by an acardiac twin with acardiac acephalus malformation, short abnormal limbs and an omphalocele (Fig. 1). There was also reversed perfusion through the umbilical artery towards the

acardiac twin (Fig. 2). The pump twin was normal structurally. The acardiac twin was small, relative to the pump twin. There was no evidence of hydropic changes or polyhydramnios in either twin.

The couple was counselled with regard to the management options: expectant management with treatment indicated when poor prognostic signs were present; invasive treatment aimed at achieving cessation of blood flow through the acardiac twin (either intrafoetal ablation with monopolar diathermy or ultrasound-guided bipolar diathermy cord occlusion); and termination of pregnancy. The couple opted for the first management option. The patient was scanned weekly for the detection of cardiomegaly, hydrops or polyhydramnios. Detailed structural ultrasonography performed at 19 weeks showed a structurally-normal pump twin albeit with a single umbilical artery. Polyhydramnios (AFI 29 cm) was detected at 22 weeks, although there was no cardiomegaly in the pump twin and the Doppler insonation of the ductus venosus showed a positive "a" wave. The acardiac twin measured 79 mm × 48 mm × 53 mm. The need for intervention was discussed and a decision was made for invasive treatment if a subsequent scan continued to show polyhydramnios.

Fortunately, ultrasonography one week later showed cessation of blood flow through the acardiac twin, negating the need for intervention. Subsequent scans confirmed this, with a gradual diminishing size of the acardiac mass and resolution of the polyhydramnios. The last ultrasonographical scan at 30 weeks confirmed that the pump twin was growing along the 50th centile on the nomogram, with a normal Doppler study of the umbilical artery and normal amniotic fluid index. Subsequent monitoring of the pump twin by weekly cardiotocography was uneventful. The timing of delivery was deliberated with the couple. On the one hand, an early delivery may be indicated to prevent complications of cord entanglement in a monochorionic monoamniotic twin pregnancy, although the acardiac twin's cord vessels were probably thrombosed. On the other hand, the thrombosed cord may already be broken away, reducing the risk of cord entanglement, and hence justifying the timing of delivery as a singleton pregnancy.

After discussion with the parents, an elective caesarean section was scheduled. A healthy girl was delivered at 35 weeks and three days gestation, with a birth weight of 2,820 g and Apgar scores of 9 both at one and five minutes. The acardiac twin was delivered next. It was a macerated anencephalic foetus with four rudimentary limbs and an omphalocele. It weighed 53 g and postmortem examination confirmed acardia. Histology confirmed a monochorionic monoamniotic placenta with two

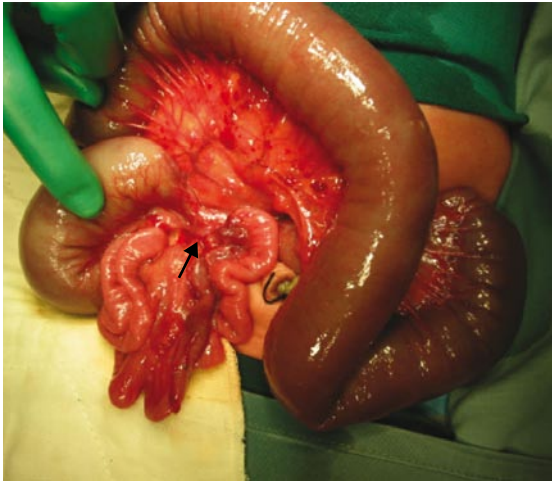


Fig. 4 Operative photograph shows a section of the stenotic ileum with dilated small bowel proximal to it (short arrow denotes segment of atresia).

cords, with thrombosis and break-off of the cord to the acardiac twin. At birth, the normal twin was discovered to have clinical features of intestinal obstruction supported by findings on abdominal radiographs (Fig. 3). She was operated on day one of life. She underwent a laparotomy, resection of bowel with end-to-end anastomoses for segmental volvulus of the ileum, which when untwisted, revealed a localised 10 cm segment of distal stenotic ileum with a sealed perforation (Fig. 4). We felt that a vascular event had caused the atretic bowel, and this in turn resulted in proximal dilatation and thus localised volvulus. Histology showed evidence of a previous old healed ischaemic perforation of the ileum and an ileal fibrotic stricture. She was discharged clinically well 21 days after delivery.

DISCUSSION

This case report is interesting in three aspects. Firstly, it agrees with the observations by others that spontaneous cessation of blood flow in the acardiac twin may occur during expectant management.⁽³⁾ Indeed, a recent paper by Sullivan et al suggested that neonatal mortality of the pump twin in antenatally-diagnosed acardiac twin pregnancies may be less than reported and that expectant management with close antepartum surveillance deserved consideration.⁽⁴⁾ The acardiac twin became extremely small (53 g) in our case, by the time of delivery. Moore et al had shown that the ratio of the estimated weight of the acardiac twin to the pump twin is a good predictor of complications in the pregnancy.⁽⁵⁾ Hence, expectant management may indeed be a management option, especially for an acardiac pregnancy when the mass

of the acardiac twin is relatively small. Another useful test in such a case may include the use of difference in resistive index. Dashe et al reported that greater differences in the resistive index values between the acardiac twin and the pump twin are associated with a more favourable pregnancy outcome as it indicated relatively little flow to the acardiac twin.⁽⁶⁾ Expectant management would have to be terminated once there is evidence of persistent polyhydramnios, cardiomegaly or hydrops.

Secondly, the initial fear of the risk of cord entanglement in a monochorionic monoamniotic twin pregnancy with a thrombosed cord was unfounded by our experience in this case. Monoamniotic twin pregnancies are frequently complicated by umbilical cord entanglement and foetal death, and the prognosis is sombre, with up to 40%–60% mortality. Hence, caesarean section is indicated by 32–34 weeks.⁽⁷⁾ However, the thin thrombosed cord divided spontaneously, as evidenced by intrapartum and postpartum findings. Further observations are required to confirm that thrombosed cords in acardiac twins do not pose cord entanglement risks. Thirdly, the finding of intestinal atresia/stenosis postnatally in the pump twin does bring fresh worries to the approach of expectant management. In the usual midgut volvulus, it is malrotation that predisposes the gut to twist about itself. However, in localised segmental volvulus (as in this case), it was thought that a vascular event had resulted in the atresia with resulting dilatation and volvulus. Ischaemia due to hypotensive episodes during the spontaneous cessation of the umbilical artery blood flow may be such a vascular event, and in addition, may result in microcephaly, porencephalic cysts, aplasia cutis, and limb amputation.⁽⁸⁾ The possibility of such a complication necessitates close monitoring with ultrasonography of the co-twin, even after spontaneous cessation of the umbilical arterial flow in the acardiac twin.

If such an association of vascular complications with spontaneous cessation of blood flow is confirmed with more case reports or case series, expectant management with a possibility of spontaneous cessation of blood flow in the acardiac twin may no longer be acceptable. A policy of routine prophylactic treatment for all acardiac twins from 15 weeks may then be indicated. Treatment at this early stage would also preclude the difficulty in achieving cessation of blood flow in larger and sometimes hydropic acardiac twins. Of the various methods available, intrafoetal ablation with interstitial laser, monopolar diathermy and radiofrequency ablation has recently been demonstrated in a systemic review of minimally

invasive modalities to be safer, simpler and more effective than cord occlusion methods.⁽²⁾

REFERENCES

1. Romero R, Pihu G, Jeanty P, Ghidini A, Hobbins JC. Prenatal Diagnosis of Congenital Anomalies. East Norwalk, CT: Appleton & Lange, 1988: 409-11.
2. Tan TYT, Sepulveda W. Acardiac twin: a systematic review of minimally invasive modalities. Ultrasound Obstet Gynecol 2003; 22:409-19.
3. Søgaard K, Skibsted L, Brocks V. Acardiac twins: pathophysiology, diagnosis, outcome and treatment. Six cases and review of the literature. Fetal Diagn Ther 1999; 14:53-9.
4. Sullivan AE, Varner MW, Ball RH, Jackson M, Silver RM. The management of acardiac twins: a conservative approach. Am J Obstet Gynecol 2003; 189:1310-3.
5. Moore TR, Gale S, Benirschke K. Perinatal outcome of forty-nine pregnancies complicated by acardiac twinning. Am J Obstet Gynecol 1990; 163:907-12.
6. Dashe JS, Fernandez CO, Twickler DM. Utility of Doppler velocimetry in predicting outcome in twin reversed-arterial perfusion sequence. Am J Obstet Gynecol 2001; 185:135-9.
7. Dubecq F, Dufour P, Vinatier D, et al. Monoamniotic twin pregnancies. Review of the literature, and a case report with vaginal delivery. Eur J Obstet Gynecol Reprod Biol 1996; 66:183-6.
8. Schinzel AA, Smith DW, Miller JR. Monozygotic twinning and structural defects. J Pediatr 1979; 95:921-30.



Looking to hit that sales target?

Advertise with the **Singapore Medical Journal.**

The voice of academic medicine in Singapore and Southeast Asia since 1960

To advertise, please contact: **Li Li Loy**, Advertising Executive
Mobile: **9634 9506** Tel: **6223 1264 ext 23** Email: **lili@sma.org.sg**