

# Pharyngomalacia as a cause of severe neonatal stridor

Chan E Y T, Ng D K K, Chow P Y, Kwok K L

## ABSTRACT

**A male neonate presented at 24 hours with stridor and respiratory distress. Flexible bronchoscopy showed pharyngomalacia, i.e. complete pharyngeal wall collapse during inspiration. Assessment of upper airway dynamics is emphasised. Pharyngomalacia seems to be a self-limiting condition in our case.**

**Keywords: flexible bronchoscopy, neonate, pharyngomalacia, respiratory distress, stridor**

*Singapore Med J 2007;48(9):e246–e247*

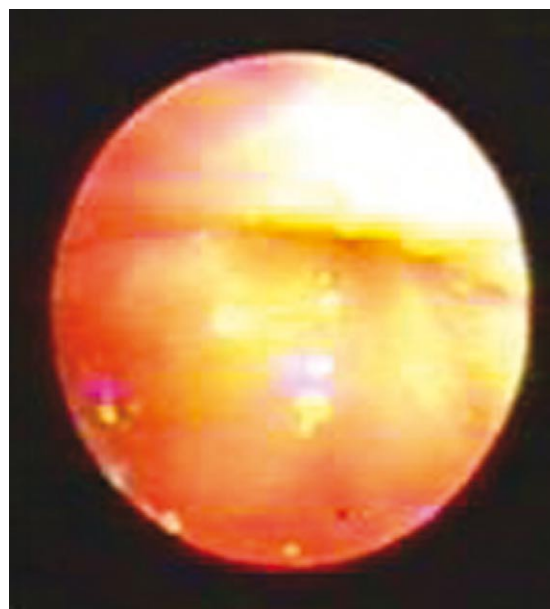
## INTRODUCTION

Neonatal stridor may be potentially serious, and flexible bronchoscopic examination is usually the investigation of choice. Laryngomalacia is the commonest cause. In some cases of neonatal stridor, no specific cause was found.<sup>(1)</sup> We describe a case of symptomatic neonatal stridor due to pharyngomalacia, i.e. complete collapse of pharyngeal wall during inspiration.

## CASE REPORT

A male neonate was delivered by caesarean section because of breech presentation at gestation of 43 weeks. The Apgar scores were eight at one minute, and nine at five minutes. His birth weight was 3.64 kg. He was apparently well and could take 30 ml of milk per feed in the first several hours of life. At 24 hours of life, he was found to have cyanosis and tachypnoea on crying. SpO<sub>2</sub> was 74% in room air. Desaturation responded to oxygen supplement at 2 L/min through a head-box. He was then transferred to a special care baby unit for further management. On admission, respiratory rate was 60/min. Subcostal insucking and stridor were noted. SpO<sub>2</sub> was 95% in room air. Both nostrils were found to be patent by passing an infant feeding tube. Chest radiograph was normal. He was kept nil by mouth and flexible bronchoscopy was done on the next day.

Topical 2% xylocaine gel was applied to both nostrils. In line with the established protocol at the authors' department, a 2.5 mm endotracheal tube was inserted through the left nostril down to the nasopharynx



**Fig. 1** Bronchoscopic photograph shows that the oropharyngeal wall is collapsed on inspiration.

to allow oxygen flow through an Ayres T-piece during the bronchoscopy procedure. Flexible bronchoscope with an outer diameter of 2.8 mm (Olympus XP260F, Japan) was inserted through the right nostril. Examinations of the nasal pyriform aperture, nasal cavity and choana were normal. Complete collapse of oropharyngeal wall was observed. This occurred simultaneously with stridor (Fig. 1). Examination of the vallecula was normal. Epiglottis was tubular in shape but there was no collapse during inspiration. Positive airway pressure of 5 cm water was given via the nasopharyngeal airway by partially occluding the outlet of the anaesthetic bag. This manoeuvre aborted the pharyngeal wall collapse (Fig. 2) and the stridor. Both vocal cords moved normally. Vocal cords were anaesthetised with 0.5 ml 1% lignocaine, followed by intravenous injection of 0.2 mg midazolam. The trachea was examined and found to be normal.

As a trial to decrease the mucosal stickiness of the pharyngeal wall and hence lessen the pharyngomalacia, oral 1.5% NaCl 5 ml was prescribed after each feed. Respiratory distress subsided two days afterwards. Respiratory rate was around 48/min. He tolerated

Department of  
Paediatrics,  
Kwong Wah  
Hospital,  
25 Waterloo Road,  
Hong Kong SAR,  
China

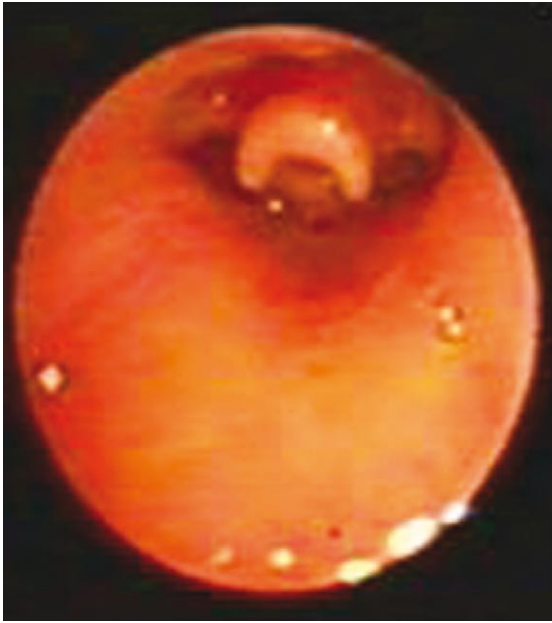Chan EYT,  
MRCPCH, FHKAM  
Medical Officer

Ng DKK, MD,  
MMedSc  
Consultant

Chow PY, FHKAM,  
MRCP  
Specialist Medical  
Officer

Kwok KL, FHKAM,  
FRCP  
Senior Medical  
Officer

**Correspondence to:**  
Dr Daniel K Ng  
Tel: (852) 3517 5471  
Fax: (852) 3517 5261  
Email: dkng@  
ha.org.hk



**Fig. 2** Bronchoscopic photograph shows the oropharynx appearance with positive airway pressure of 5 cm water.

oral feeding well and there was no desaturation. The inspiratory stridor completely subsided at six weeks of age.

## DISCUSSION

Stridor is the most common indication for bronchoscopy in neonates. Laryngomalacia is the most common congenital laryngeal anomaly, accounting for 60%–81% of cases of stridor in newborns.<sup>(1,2)</sup> A case series showed that the prevalence of concomitant malacic lesions, other than laryngomalacia, ranged from 24% for laryngotracheobronchomalacia to 47% for tracheobronchomalacia in children. However, the prevalence of concomitant pharyngomalacia has not been reported.<sup>(3)</sup> Froehlich et al introduced the concept of discoordinate pharyngolaryngomalacia, which was defined as severe laryngomalacia with complete supraglottic collapse during inspiration with associated pharyngomalacia. Surgical procedure was inadequate to reverse the clinical problem in those cases.<sup>(4)</sup> Sichel et al also reported that respiratory distress could be due to pharyngomalacia in post-supraglottoplasty cases.<sup>(5)</sup> In those case series, most cases had severe concomitant laryngomalacia.

The current case demonstrated that pharyngomalacia per se could be the cause of stridor in neonates. Shatz et al showed that pharyngeal wall inspiratory collapse was diagnosed in 46% of infants with symptoms of

upper airway obstruction, although most of their cases had concomitant hypotonia.<sup>(6)</sup> The oropharynx is the most compliant region of the upper airway. Increasing the transmural pressure leads to inward movement of the anterior, posterior, and lateral airway walls of the naso-, oro- and hypopharynx.<sup>(7)</sup> Pharyngeal patency is maintained by pharyngeal muscle activity, which is influenced by cerebral cortex in response to neural and chemical inputs. We postulate that an immature central nervous system leads to depressed pharyngeal dilator muscle activity and results in pharyngomalacia.

We suggest that pharyngomalacia is a cause of neonatal stridor. It is important to evaluate the upper airway dynamics in stridulous neonates. If one performs bronchoscopy under general anaesthesia, one may miss the pharyngomalacia as general anaesthesia or deep sedation suppresses the inspiratory effort. This issue was addressed by Botma et al, who suggested flexible fiberoptic laryngoscopy under local anaesthetics in infants with inspiratory stridor.<sup>(1)</sup> Berkowitz et al also suggested awake laryngoscopy.<sup>(8)</sup> To avoid missing lower airway anomalies in cases of neonatal stridor, the trachea should always be examined by a bronchoscope after intravenous sedatives and local anaesthetics. Secretions adherent to a luminal wall could markedly narrow the lumen.<sup>(7)</sup> Hypertonic saline is effective in mucus thinning. In this case, we gave the patient hypertonic saline by mouth to decrease the mucus over the pharyngeal wall and the patient experienced clinical improvement. In conclusion, isolated pharyngomalacia could cause severe stridor in selected neonates. It may resolve with conservative treatment within days.

## REFERENCES

1. Botma M, Kishore A, Kubba H, Geddes N. The role of fiberoptic laryngoscopy in infants with stridor. *Int J Pediatr Otorhinolaryngol* 2000; 55:17-20.
2. Simon NP. Evaluation and management of stridor in the newborn. *Clin Pediatr (Phila)* 1991; 30:211-6.
3. Masters IB, Chang AB, Patterson L, et al. Series of laryngomalacia, tracheomalacia, and bronchomalacia disorders and their associations with other conditions in children. *Pediatr Pulmonol* 2002; 34:189-95.
4. Froehlich P, Seid AB, Denoyelle F, et al. Discoordinate pharyngolaryngomalacia. *Int J Pediatr Otorhinolaryngol* 1997; 39:9-18.
5. Sichel JY, Dangoor E, Eliashar R, Halperin D. Management of congenital laryngeal malformations. *Am J Otolaryngol* 2000; 21:22-30.
6. Shatz A, Goldberg S, Picard E, Kerem E. Pharyngeal wall collapse and multiple synchronous airway lesions. *Ann Otol Rhinol Laryngol* 2004; 113:483-7.
7. Reed WR, Roberts JL, Thach BT. Factors influencing regional patency and configuration of the human infant upper airway. *J Appl Physiol* 1985; 58:635-44.
8. Berkowitz RG. Neonatal upper airway assessment by awake flexible laryngoscopy. *Ann Otol Rhinol Laryngol* 1998; 107:75-80.