

Third head of biceps brachii in an Indian population

Rai R, Ranade A V, Prabhu L V, Pai M M, Prakash

ABSTRACT

Introduction: The biceps brachii is one of the muscles of the anterior compartment of the upper arm. It is characteristically described as a two-headed muscle that originates proximally by a long head and a short head. The present study was carried out to find the occurrence of a third head of biceps brachii among a sample Indian population from the southern coastal part.

Methods: The arms of 42 cadavers were dissected and observed for variations in the origin and insertion of biceps brachii muscle bilaterally. The cadavers were embalmed and preserved in ten percent formalin.

Results: Among 42 arms studied, three had biceps brachii with three heads on the right side. The third head was of humeral origin, which inserted into the radial tuberosity by a common tendon with the long and short heads. The results of the present study compared with that of previous studies from medical literature shows that the occurrence of a third head of the biceps brachii muscle is relatively rare in Indians.

Conclusion: Knowledge of the existence of the third head of biceps brachii may become significant in preoperative diagnosis and during surgery of the upper limb.

Keywords: accessory head of biceps brachii, anatomical variants, biceps brachii variations, supernumerary head of biceps brachii, third head of biceps brachii

Singapore Med J 2007; 48(10):929-931

INTRODUCTION

The biceps brachii is one of the muscles of the anterior compartment of the upper arm. It is characteristically described as a two-headed muscle that originates proximally by a long head and a short head. The long head originates from the supraglenoid

tubercle of the scapula, and the short head originates from the coracoid process of the scapula.⁽¹⁾ Distally, these two heads join to form a common tendon which inserts into the radial tuberosity, and some aponeurotic fibres form the bicipital aponeurosis which merges with the deep fascia of the forearm. This muscle mainly contributes to flexion and supination of the forearm.⁽¹⁾ Testut has described the biceps brachii muscle as one of the muscles with most frequent anatomical variations.⁽²⁾ These variations may present as a group of accessory fascicles arising from the coracoid process, the pectoralis major tendon, head of the humerus, articular capsule of the humerus or from the shaft of the humerus itself.⁽³⁾ This last variation is also known as the humeral head of the biceps brachii muscle. Several authors have reported the presence of this anomaly with a varying frequency.⁽⁴⁻⁶⁾

METHODS

The upper limbs of 42 cadavers were dissected and observed for variations in the origin and insertion of the biceps brachii muscle bilaterally. All the cadaveric materials were studied in the department of anatomy. A longitudinal incision was made at the anterior aspect of the arm, from the level of acromion process to a point about 2.5 cm below the elbow joint. A horizontal incision was made bilaterally in both proximal and distal ends of the longitudinal incision. The subcutaneous fat and fascia were separated to expose the biceps brachii muscle.

RESULTS

Among the 42 superior extremities studied, three arms were found to have a three-headed biceps brachii muscle. The variation was present in the right arm of two males and one female. The third head of biceps brachii in all three cases was arising from the anteromedial aspect of the lower part of the humeral shaft (Fig. 1). It was comparatively thinner in the female cadaver (Fig. 2). In all three cases, the third head descended and merged with the other two heads to form a common tendon and was inserted onto the radial tuberosity.

DISCUSSION

The incidence of the third head of the biceps brachii muscle has been reported in several articles. The aim

Department of
Anatomy,
Kasturba Medical
College,
Mangalore 575004,
Karnataka,
India

Rai R, MSc
Senior Lecturer

Ranade AV, PhD
Senior Lecturer

Prabhu LV, MD
Professor and Head

Pai MM, MD
Assistant Professor

Prakash, MD
Assistant Professor

Correspondence to:
Mrs Rajalakshmi Rai,
Tel: (91) 98 8650 2036
Fax: (91) 82 4242 8183
Email: rajalakshmirai
@yahoo.co.in

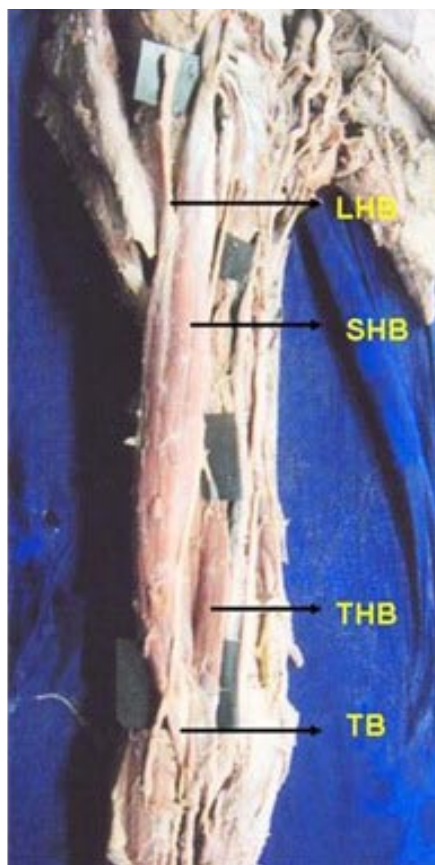


Fig. 1 Photograph of the dissected arm of a male cadaver shows the biceps brachii with its three heads. This specimen shows the origin of the third head of biceps from the anteromedial aspect of the humeral shaft and it appears to be a portion of the brachialis muscle, which is supplied by the musculocutaneous nerve. LHB: long head of biceps; SHB: short head of biceps; THB: third head of biceps; TB: tendon of biceps.

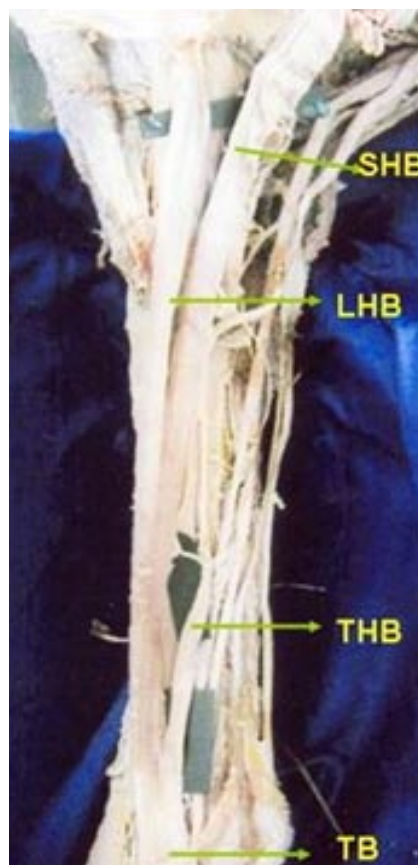


Fig. 2 Photograph of the dissected arm of a female cadaver shows the biceps brachii with its three heads. The third head of biceps is comparatively thinner and originates from the anteromedial aspect of the humeral shaft. It appears to be a part of the brachialis muscle. SHB: short head of biceps; LHB: long head of biceps; THB: third head of biceps; TB: tendon of biceps.

of this study is to report the occurrence of the third head of biceps brachii in a sample Indian population along the southern coast of India, and to compare it with other racial groups from previous studies. Gray's Anatomy reported the incidence of this variation to be as much as 10%,⁽¹⁾ which concurs with the observations of Bergman et al in white Europeans.⁽⁵⁾ Asvat et al reported an incidence of 21.5% in their study group consisting of blacks.⁽⁴⁾ It appears that the incidence varies among ethnic groups. Kopuz et al attributed the appearance of these variants to evolutionary or racial trends.⁽⁶⁾ Santo Neto et al reported an incidence of 9% among blacks, which was significantly lower than the reported incidence for whites in his series.⁽⁷⁾ Khaledpour contradicted Santo Neto et al's results by comparing his series to the results from other authors. He reported that the third head of biceps brachii was rare in whites and relatively high among blacks.⁽⁸⁾ In our study, we have observed the incidence of third head of

biceps brachii in 7.1% of the cases. According to Khaledpour, male cadavers were found to have this variant in 31.2% of the cases he studied.⁽⁸⁾ In our study, 4.81% (two of 42) of male cadavers were found to have the third head of biceps.

Asvat et al observed that the third head of biceps brachii originated from the humeral shaft either inferior to, and in common with, the insertion area for the coracobrachialis, or in common with the brachialis muscle.⁽⁴⁾ They also observed a dual origin in which the medial fibres originated from the short head of biceps and the lateral fibres from the deltoid fascia. According to Kopuz et al, the third head of biceps brachii frequently arose from the anterior surface of the humerus distal to the insertion of the coracobrachialis muscle, which is similar to our results.⁽⁶⁾ Kosugi et al observed that the supernumerary head of biceps arose from the humerus between the insertion of coracobrachialis and the upper part of the origin of brachialis and/or from the medial

intermuscular septum.⁽⁹⁾ The same authors have also reported that in a few cases, the biceps brachii was seen to be arising from the tendon of the pectoralis major, the deltoid, the articular capsule, or the crest of the greater tubercle.⁽⁹⁾ Abu-Hijleh reported that the supernumerary bicipital head originated from the anteromedial surface of the humerus just below the insertion of coracobrachialis.⁽¹⁰⁾ The results of the present study compared with that of previous studies, which show that the occurrence of a third head of the biceps brachii muscle is relatively rare in the Indian population.

Embryological observations by Testut described this variation of the third head of biceps brachii as a portion of the brachialis muscle supplied by the musculocutaneous nerve, in which its distal insertion has been translocated from the ulna to the radius.⁽²⁾ Knowledge of the existence of the third head of the biceps brachii may become significant in preoperative diagnosis and during surgery of the upper limbs. Therefore, surgeons, in particular orthopedic surgeons,

should be aware of this anatomical variation when dealing with some of the clinical syndromes.

REFERENCES

1. Williams PL, Bannister LH, Berry MM, et al, eds. Gray's Anatomy: The Anatomical Basis Of Medicine And Surgery, 38th ed. Edinburgh: ELBS Churchill Livingstone, 1995: 843.
2. Testut L. En: Tratado de Anatomia Humana. Barcelona: Salvat, 1902.
3. Sargon MF, Tuncali D, Celik HH. An unusual origin for the accessory head of biceps brachii muscle. Clin Anat 1996; 9:160-2.
4. Asvat R, Candler P, Sarmiento EE. High incidence of the third head of biceps brachii in South African populations. J Anat 1993; 182:101-4.
5. Bergman RA, Thompson SA, Afifi AK. Compendium of Human Anatomic Variation: Text, Atlas, and World Literature. Baltimore: Urban and Schwarzenburg, 1988.
6. Kopuz C, Sancak B, Ozbenli S. On the incidence of third head of biceps brachii in Turkish neonates and adults. Kaibogaku Zasshi 1999; 74:301-5.
7. Santo Neto H, Camalli JA, Andrade JC, Meciano Filho J, Marques MJ. On the incidence of the biceps brachii third head in Brazilian white and blacks. Ann Anat 1998; 180:69-71.
8. Khaledpour C. [Anomalies of the biceps muscle of the arm]. Anat Anz 1985; 158:79-85. German.
9. Kosugi K, Shibata S, Yamashita H. Supernumerary head of biceps brachii and branching pattern of musculocutaneous nerve in Japanese. Surg Radiol Anat 1992; 14:175-85.
10. Abu-Hijleh MF. Three-headed biceps brachii muscle associated with duplicated musculocutaneous nerve. Clin Anat 2005; 18:376-9.