

# Tuberculous pyomyositis of the thigh masquerading as malignancy with concomitant tuberculous flexor tenosynovitis and dactylitis of the hand

Batra S, Ab Naell M, Barwick C, Kanvinde R

## ABSTRACT

**Multifocal involvement of the skeleton is extremely rare, with tuberculous pyomyositis and tenosynovitis of the wrist being uncommon presentations of skeletal tuberculosis (TB). We present an immunocompetent 68-year-old woman with concomitant presentation of these uncommon forms of extrapulmonary TB heralded by tuberculous pyomyositis. Tuberculous pyomyositis can often masquerade as malignancy, leading to misdiagnosis and patients being mistakenly referred to oncologists for management. This delayed the institution of appropriate drug therapy. Similarly, because of its rarity, tuberculous tenosynovitis may be overlooked as a cause of chronic tenosynovitis. In the absence of pathognomonic imaging findings, the diagnosis ultimately rests on histopathological and microbiological confirmation. This case highlights the importance of maintaining a high index of suspicion of the protean manifestations of extrapulmonary TB, not only in high-risk populations, but in immunocompetent individuals as well. It also illustrates the advantage of a clinically-directed multidisciplinary approach in early recognition and treatment of this entity.**

**Keywords: dactylitis, musculoskeletal tuberculosis, pyomyositis, tenosynovitis, tuberculosis**

*Singapore Med J 2007;48(11):1042-1046*

## INTRODUCTION

A significant rise in the extrapulmonary, and particularly, osteoarticular manifestations of tuberculosis (TB) has been observed worldwide, with the pandemic of the human immunodeficiency virus and emergence

of multidrug resistant strains of *Mycobacterium tuberculosis* (*M. tuberculosis*).<sup>(1)</sup> A similar rise in incidence in immunocompetent individuals has been observed. Skeletal TB accounts for 10%–20% of all tuberculous infections, but multifocal skeletal involvement is seen in less than 5% of these cases.<sup>(2)</sup> Tuberculous pyomyositis is the least frequent location of extraspinal musculoskeletal tuberculosis reported in literature,<sup>(3)</sup> while tuberculous tenosynovitis of the hand accounts for about 1% of cases with musculoskeletal TB.<sup>(3,4)</sup> Extrapulmonary TB remains a difficult diagnosis to make, due to its often nonspecific and protean manifestations. The literature abounds with cases of delayed or wrong diagnoses because of a lack of awareness, particularly among young clinicians and surgeons who have not had much experience with this disease.

We present this rare case of concomitant tuberculous pyomyositis, tuberculous tenosynovitis and dactylitis, initially referred to the musculoskeletal tumour service with a presumptive diagnosis of malignancy in the thigh. We highlight the diagnostic and therapeutic dilemma facing the clinician dealing with these rare manifestations of skeletal TB. We emphasise maintaining a high index of suspicion for the protean manifestations in immunocompetent patients and a clinically-directed multidisciplinary approach in early recognition and treatment of this entity.

## CASE REPORT

A 68-year-old woman presented to the orthopaedic outpatient department with a large swelling over the lateral aspect of the right thigh, extending up to gluteal region. This started eight weeks ago as a painless, egg-sized swelling over the trochanteric region. She denied any history of recent trauma, fever, weight loss, cough or other systemic symptoms. Family history included diagnosis of tuberculous lymphadenopathy in her son six years ago with complete resolution on antituberculous treatment. She experienced pain in the

Department of  
Orthopaedics,  
Gwynedd Hospital,  
North West Wales  
NHS Trust,  
Bangor,  
Gwynedd,  
LL57 2PW,  
The United Kingdom

Batra S, MS, MRCS  
Specialist Registrar

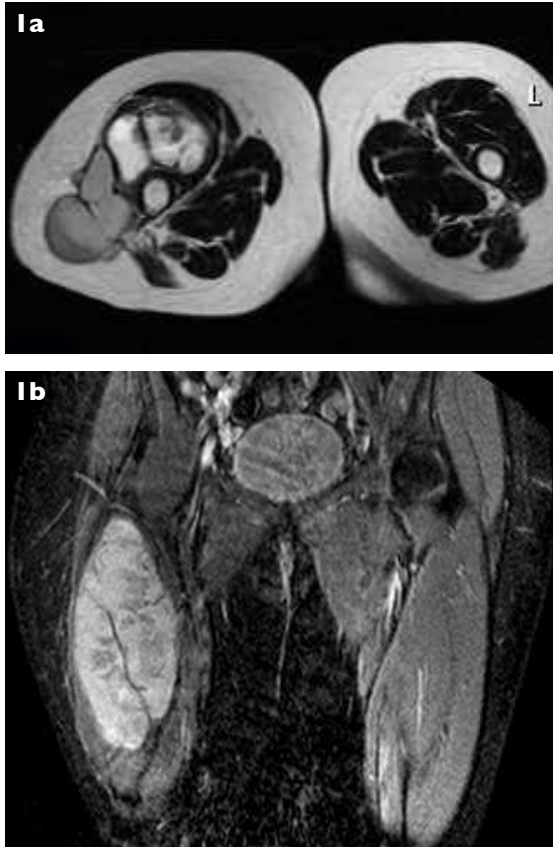
Ab Naell M, MRCS  
Registrar

Kanvinde R, MCh,  
FRCS  
Consultant

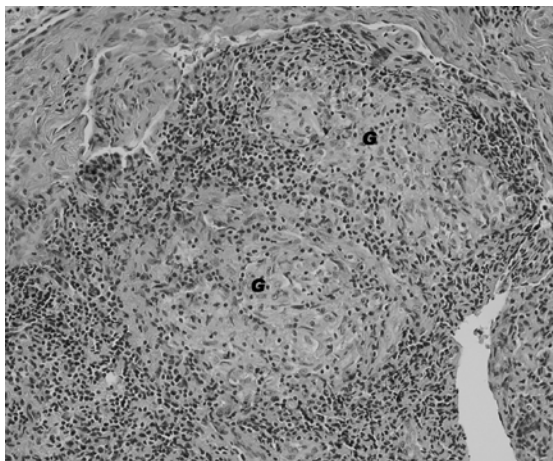
Department Of  
Radiology

Barwick C, FRCS  
Consultant

Correspondence to:  
Mr Sameer Batra  
Department of  
Orthopaedics,  
Royal Gwent  
Hospital,  
New Port,  
NP 20 2UB,  
The United Kingdom  
Tel: (44) 791 505 3576  
Fax: (44) 12 4838 4735  
Email: drbatrasameer  
@yahoo.co.uk



**Fig. 1** (a) Axial T2-W MR image taken at the level of the proximal thigh and (b) coronal STIR MR image show the subcutaneous lesion with its proximal and distal extensions revealing large areas of a mixed, predominantly high signal pattern.



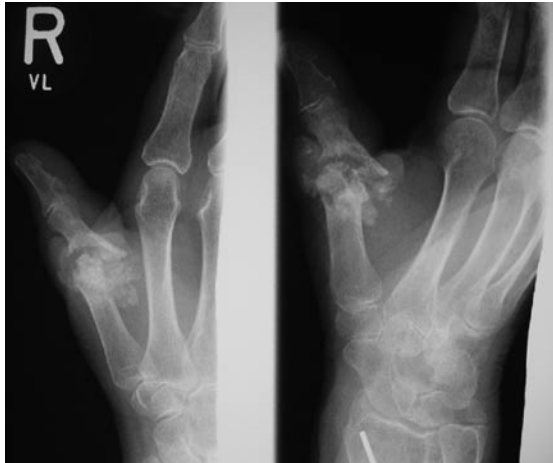**Fig. 2** Photomicrograph of the specimen biopsied from the most affected region overlying the greater trochanter shows infiltration of the muscle tissues with epithelioid granulomas (G) with scattered Langhans-type giant cells (Haematoxylin and eosin,  $\times 540$ ).

trochanteric region for five years. She was diagnosed with bursitis and treated with three steroid injections. Radiographs of the pelvis and thigh taken then did not reveal any bone erosion, lysis or periosteal reaction.

However, it did show a few flecks of calcification in the soft tissue adjacent to the trochanter and some irregularity over the cortical margin of the greater trochanter. Technetium-99m bone scintiscans showed minimally-increased tracer uptake in the region of greater trochanter adjacent to the area of soft tissue calcification, and in the wrist and thumb. Physical examination showed normal overlying skin and a poorly-defined 20 cm  $\times$  10 cm swelling over the lateral aspect of the thigh, extending up to the gluteal area, with normal hip and abdominal examination.

Haematological work-up showed an elevated erythrocyte sedimentation rate of 72 mm/hour and a total leucocyte count of  $9.0 \times 10^9/L$  with a differential of polymorphonuclear cells (58%), lymphocytes (28%), monocytes (1%), and eosinophils (2%). Chest radiograph and skeletal survey did not reveal any abnormality. Magnetic resonance (MR) imaging showed a large mass in the posterolateral aspect of the upper thigh, extending up to the mid-thigh, with a mixed signal on T1- and T2-weighted images. On axial T2-weighted and coronal short-tau inversion recovery (STIR) images, the lesion appeared to be cystic with large areas of low signal within, suspected to be due to the presence of a solid tumour or areas of haemorrhage (Figs. 1a & b). Computed tomography (CT) of the thigh showed some cortical irregularity in the region of greater trochanter but no bony destruction. Overall, the imaging was suspicious of an aggressive mass confined to soft tissues.

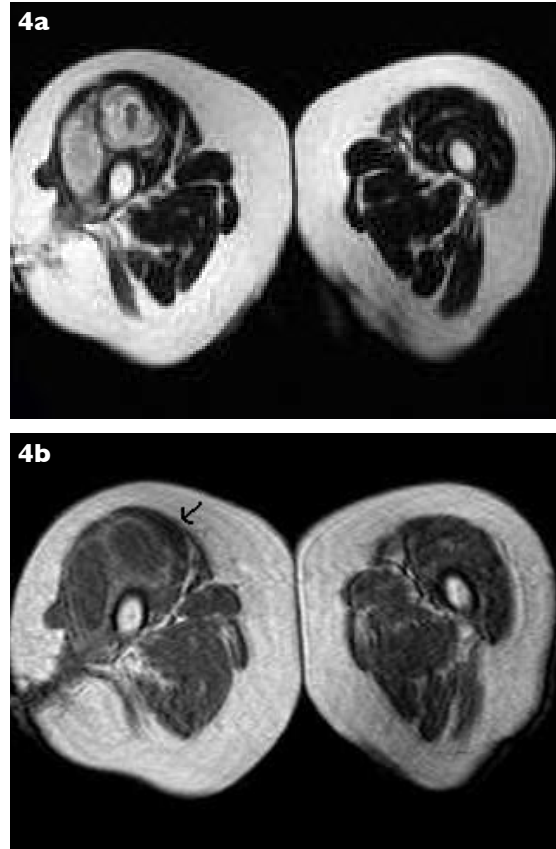
The patient was therefore referred to the musculoskeletal tumour service with a presumptive diagnosis of malignancy. A needle aspiration yielded a large amount of creamy, thick fluid which congealed on cooling. Gram-stained smear, bacterial culture and staining for acid-fast bacilli were negative. The aspirate was positive for mycobacterial-specific gene sequences on polymerase chain reaction analysis. Biopsy demonstrated fibrofatty tissue with chronic inflammation with multiple caseating and noncaseating epithelioid granulomas with scattered Langhans-type giant cells (Fig. 2). Several weeks later, cultures of aspirate grew *M. tuberculosis*, which were later confirmed by DNA probe. It was reported to be susceptible to rifampin, isoniazid, ethambutol, and itraconazole. The patient was started on empirical antibiotics on consultation with a pulmonologist, as soon as a diagnosis of pyomyositis was made. Antituberculous treatment (a four-drug regimen: isoniazid, rifampicin, pyrazinamide, and ethambutol on a daily basis) was initiated. The patient continued to make a slow recovery, but there were recurring flares with persistent discharge from the sinus track despite being on the antituberculous treatment for six months.



**Fig. 3** Radiograph of the hand shows destruction of the thumb MCP joint with extensive bony erosion, lysis and adjacent heterotopic new bone formation.

During this period, she developed increasing pain and swelling over the right wrist and thumb, associated with tingling mainly in the median nerve distribution. She had been evaluated by the hand surgeon a few weeks ago and, with a clinical diagnosis of synovitis causing median nerve compression, was awaiting ultrasonography and MR imaging of the wrist. Clinical examination revealed a diffuse swelling over the palmar aspect of the wrist extending towards the thumb, with hypoaesthesia in the median nerve distribution and gross instability of the first metacarpophalangeal (MCP) joint. Radiographs of the hand revealed destruction of the MCP joint with extensive bony erosion (Fig. 3). Urgent ultrasonography of the hand revealed extensive tenosynovitis in the carpal tunnel, with extensive hypoechoic thickening of flexor tendons and their sheaths, which continued along the flexor pollicis longus. Radiographs of the pelvis showed erosion of the right greater trochanter, and repeat MR imaging revealed an abscess lying mainly in the anterior compartment, replacing predominantly the vastus lateralis. T2- and T1-weighted MR images showed an extensive heterogeneous but predominantly hyperintense soft tissue lesion in the right thigh with peripheral enhancement (Figs. 4a & b).

An incision and drainage with debridement of cold abscess of the right thigh was performed, along with tenosynovectomy of the right wrist and debridement of the flexor tendon of the right thumb. During operative drainage in the thigh, a flocculent mass of fat containing soft tissue, studded with multiple punctate dirty-white lesions, was noted to be adherent to the greater trochanter, and pus was found tracking through the intermuscular planes. The sinus track, and all necrotic tissue, were excised. In the wrist, synovial



**Fig. 4** (a) Axial T2-W MR image shows a multiloculated collection with a sinus track in the subcutaneous tissues. (b) Contrast-enhanced axial T1-W MR image shows peripheral enhancement (arrow) with extension into the subcutaneous tissues.

thickening with fibrinous masses (tubercles) and caseous masses within the wall of the flexor tendon sheaths was noted. Superficial and deep flexor tendons were partially-eroded and adhered to each other. The thickened flexor tendon sheath was sharply debrided of all inflammatory tissue. Distally, the lesion extended through the carpal canal into the palm and thumb along the flexor tendon sheath. The compressed median nerve in the carpal tunnel was decompressed. Complete excision of the affected tissues and tenosynovectomy of the wrist were performed and the median nerve was released. The specimens obtained from the thigh and one curetted from the wrist confirmed the diagnosis of caseous granulomatous inflammation. The patient was continued on a multidrug regime and gentle wrist mobilisation was started four days postoperatively. The use of rifampicin and isoniazid was continued for an additional nine months, to ensure adequate treatment of this advanced stage of disease. At 14 months follow-up, her wounds have healed uneventfully with no evidence of systemic or local recurrence.

## DISCUSSION

There have been very few reports of primary muscular TB in the English literature without the involvement of bone.<sup>(5,6)</sup> In our case, concomitant tuberculous pyomyositis and wrist involvement, which are extremely rare as extrapulmonary manifestations, were seen. The exact mechanism of how *M. tuberculosis* reaches the musculoskeletal system is not fully understood, although haematogenous dissemination after pulmonary disease and direct inoculation have been hypothesised. More often than not, however, and our case is no exception, there is no evidence of concurrent active or arrested tuberculous foci in any location other than the musculoskeletal system.<sup>(7)</sup> Our patient presented with an indolent onset, without any pulmonary or systemic symptoms suggestive of TB.

TB of the striated muscle is rare, even in countries where TB is a relatively common disease.<sup>(7)</sup> Skeletal muscle is one of the most resistant tissues to mycobacterial infection and the reasons hypothesised for this resistance include poor oxygen content, high lactic acid concentration, and a paucity of reticuloendothelial tissue.<sup>(8)</sup> Tuberculous pyomyositis, in the absence of a direct spread from an adjacent primary focus, may be found in three circumstances: immunocompromised patients,<sup>(7)</sup> inoculation through needles and syringes contaminated with mycobacterium,<sup>(9)</sup> and idiopathically in an immunocompetent host, as in this case.<sup>(5,6,10)</sup> The tuberculous abscess affected primarily the vastus lateralis without bony involvement in the initial stages. The first probability is that *M. tuberculosis* seeded the vastus muscle haematogenously. The steroid injections may have damaged the muscle, making it more susceptible to infection by *M. tuberculosis*. A second possibility is that the muscle infection was caused by spread from the adjacent greater trochanter. Tuberculous bursitis and osteitis are rare causes of lateral hip pain but do manifest as flecks of calcification within the bursa.<sup>(11)</sup> This patient might have had dormant tuberculous infection in the bursa, which might have been reactivated by the steroid injections. However, the trochanteric destruction did not become apparent until long after the pyomyositis was treated.

Initial radiological work-up, including CT and MR imaging, revealed features consistent with soft tissue malignancy. Malignant lesions tend to have shaggy or irregular edges, and show invasion into the fat planes on imaging. Because of this overlap in imaging appearances between extrapulmonary TB and malignancy, even in cases where the imaging and clinical features strongly suggest TB, the diagnosis

requires histopathological and bacteriological confirmation. MR imaging is more accurate in identifying and evaluating the loco-regional extension of pyomyositis, as the signal alteration consisting of T1-hypointensity and T2-hyperintensity, with a homogeneously-enhanced abscess wall, allows recognition of contiguous skeletal structures, especially by using fat suppression and a paramagnetic contrast agent.<sup>(12)</sup> These findings are known to be due to oxygen free radicals and macrophage sequestration iron, from microvascularisation, in the wall of the abscess.<sup>(12)</sup> The signal intensity of the peripheral rim is helpful in differentiating the abscess from cystic tumour of the soft tissue.

Chronicity and delay in making a specific diagnosis of tuberculous tenosynovitis was evident in our case, and is typical of reports in the literature.<sup>(3,12)</sup> The initial decision to try antituberculous therapy first and not to intervene operatively, was taken in view of previous drainage of a significant amount of pus. "Rice bodies" or "melon seeds" fibrinous masses (tubercles) are present in 50% of cases of articular TB.<sup>(12)</sup> Caseating granulomas may occasionally be seen with non-TB mycobacterial and fungal infections, sarcoidosis, and gout.<sup>(12)</sup> The flexor tendon sheath and radioulnar bursae have been reported to be the most common sites of tenosynovitis.<sup>(13)</sup> Moreover, tuberculous infection of the wrist has been described to usually originate from the tenosynovium and then extend to the joint or bone.<sup>(14)</sup> We believe this happened in our case, as flexor tendon sheath involvement preceded the MCP joint involvement. A strikingly similar clinical and histological presentation to tuberculous tenosynovitis can be seen with tenosynovitis caused by non-TB mycobacteria with *M. marinum* being the commonest, followed by *M. kansasii*, *M. chelonae*, *M. terrae*, *M. fortuitum*, and *M. avium-intracellulare*.<sup>(11)</sup>

Kim et al also suggested that MR imaging with gadolinium enhancement, if performed early enough in the disease process, could be used to differentiate between the pre-abscess invasive stage and the suppurative stage, which frequently requires drainage.<sup>(8)</sup> Because of ineffective initial needle drainage of the abscess in our case, surgical intervention was required, in addition to antituberculous medications. Surgical treatment varies depending on the extent of the disease and may include limited excision of the infected tissue, synovectomy, or wide debridement of soft and bony tissue. Tuberculous tenosynovitis has a tendency for local recurrence, with more than 50% of cases recurring within one year of treatment.<sup>(15)</sup> Isolated medical or surgical treatment alone significantly increases the risk of recurrence. In conclusion, we believe that osteoarticular TB should be considered in patients

who present with unexplained soft-tissue swelling and pain. This line of reasoning should be applied even to immunocompetent patients, and in the absence of osseous involvement. This case illustrates the advantage of a clinically-directed multi-modality imaging approach to diagnosis. Increased awareness and a high index of suspicion of extrapulmonary TB is the cornerstone to making an early diagnosis, and preventing deformities and a reduction in function.

#### REFERENCES

1. Bocanegra TS. Mycobacterial, fungal and parasitic arthritis. In: Klippel J, Dieppe P, eds. Rheumatology. London: Mosby, 1994:1-12.
2. Harrington JT. Mycobacterial and fungal infections. In: Ruddy S, Harris ED, Sledge CB, Kelley WN, eds. Kelley's Textbook of Rheumatology. Philadelphia: Saunders, 2001: 1493-505.
3. Albornoz MA, Mezgarzede M, Neumann CH, Myers AR. Granulomatous tenosynovitis: a rare musculoskeletal manifestation of tuberculosis. Clin Rheumatol 1998; 17:166-9.
4. González-Gay MA, García-Porrúa C, Cereijo MJ, et al. The clinical spectrum of osteoarticular tuberculosis in non-human immunodeficiency virus patients in a defined area of northwestern Spain (1988-1997). Clin Exp Rheumatol 1999; 17:663-9.
5. Trikha V, Gupta V. Isolated tuberculous abscess in biceps brachii muscle of a young male. J Infect 2002; 44:265-6.
6. Abdelwahab IF, Kenan S. Tuberculous abscess of the brachialis and biceps brachii muscles without osseous involvement: A case report. J Bone Joint Surg Am 1998; 80:1521-4.
7. Yao DC, Sartoris DJ. Musculoskeletal tuberculosis. Radiol Clin North Am 1995; 33:679-89.
8. Kim JY, Park YH, Choi KH, Park SH, Lee HY. MRI of tuberculous pyomyositis. J Comput Assist Tomogr 1999; 23:454-7.
9. Heycock JB, Noble TC. Four cases of syringe-transmitted tuberculosis. Tubercle 1961; 42:25-7.
10. Ergin F, Arslan H, Bilezikçi B, Agildere AM, Ozdemir N. Primary tuberculosis in the gluteal muscle of a patient with chronic renal failure. A rare presentation. Nephron 2001; 89:463-6.
11. Serhan E, Newton P, FitzGerald R, Jassim I. A visible and palpable cause of backache. Ann Rheum Dis 2000; 59:164-5.
12. Garrido G, Gomez-Reino JJ, Fernández-Dapica P, Palenque E, Prieto S. A review of peripheral tuberculous arthritis. Semin Arthritis Rheum 1988; 18:142-9.
13. Jaovisidha S, Chen C, Ryu KN, et al. Tuberculous tenosynovitis and bursitis: imaging findings in 21 cases. Radiology 1996; 201:507-13.
14. Steindler A. Tuberculous tenosynovitis of the wrist. J Iowa Med Soc 1936; 26:142-4.
15. Watts HG, Lifeso RM. Tuberculosis of bones and joints. J Bone Joint Surg Am 1996; 78:288-98.

**So many choices, too little time.**  
Tired of channel surfing?



**Singapore Medical Journal. The perfect channel for your publication.**

*The voice of academic medicine in Singapore and Southeast Asia since 1960.*

Tel: 65 6223 1264 Fax: 65 6224 7827 Email: [smj@sma.org.sg](mailto:smj@sma.org.sg)

[www.sma.org.sg/smj](http://www.sma.org.sg/smj)