

Adenocarcinoma of the rete testis with uncommon presentation as haematocele

Mehra B R, Thawait A P, Narang R R, Gangane N M, Vyas V J

ABSTRACT

Adenocarcinoma of the rete testis was encountered in a 62-year-old man. The tumour was localised in the region of the testicular hilum as a greyish-white nodule that showed no involvement of the adjacent testicular parenchyma or the epididymis. On microscopical examination, there was a well-differentiated adenocarcinoma separated by fibrovascular stroma, entirely confined to the testicular hilum. This primary carcinoma of the rete testis presented as a haematocele.

Keywords: adenocarcinoma, haematocele, rete testis, testicular tumour

Singapore Med J 2007;48(12):e311–e313

INTRODUCTION

Adenocarcinoma of the rete testis is a rare tumour with a varied presentation. A total of 44 cases have been reported.⁽¹⁾ Of these testicular tumours, primary nongerm cell tumours account for a minority of cases. Among this, adenocarcinoma originating in the rete testis is still rarer, and to our knowledge, this malignancy presenting as haematocele has not been reported in literature. It is a highly malignant tumour with poor prognosis. It is generally diagnosed clinically as a solid or cystic swelling. However, confirmation is made only on histological diagnosis. The diagnostic criteria of Nochomovitz for adenocarcinoma rete testis include (1) tumour origin around the hilum; (2) no involvement of the tunica; (3) demonstration of transition from normal to tumour epithelium; and (4) no evidence of teratoma or any other primary tumour elsewhere in the body.⁽²⁾

CASE REPORT

A 62-year-old man presented with complaints of swelling and pain in the right side of the scrotum for six months. Physical examination on admission revealed a well-developed and well-nourished man, having no abnormality except for a swelling of the right scrotum. On clinical examination, there was a

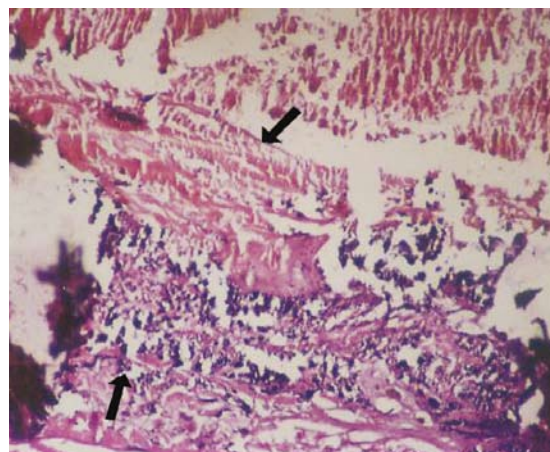


Fig. 1 Photomicrograph shows part of the haematocele (top arrow) and calcification (bottom arrow) (Haematoxylin & eosin, $\times 200$).

10 cm \times 6 cm swelling in right scrotal region. Fluctuation test was positive and transillumination was negative. With the provisional diagnosis of haematocele, exploration was done by scrotal incision. On exploration, there was blood mixed fluid in the scrotal sac with thickening of the tunica. There was a greyish-white nodule in the region of testicular hilum (Fig. 1). The testis was morphologically normal. With suspicion of a malignant nodule, scrotal incision was extended and a high right inguinal orchidectomy was performed. On light microscopical examination, there was a well-differentiated adenocarcinoma separated by fibrovascular stroma, that was entirely confined to testicular hilum. There was no extension of tumour to the testicular parenchyma or tunica (Figs. 2 & 3).

After confirming the histopathological diagnosis of adenocarcinoma of rete testis, further examination and investigation were done. Rectal examination demonstrated a moderately-enlarged prostate with no abnormal nodules. Laboratory examination revealed normal values of serum alpha-fetoprotein, alkaline phosphatase, and prostate specific antigen. Excretory urography showed normal upper urinary tracts. Chest radiographs, abdominal ultrasonography and computed

Department of Surgery,
Mahatma Gandhi
Institute of Medical
Sciences,
Sevagram,
Wardha 442102,
Maharashtra,
India

Mehra BR,
MBBS, MS
Associate Professor

Thawait AP, MBBS
Postgraduate

Narang RR,
MBBS, MS
Professor and Director

Department of
Pathology

Gangane NM,
MBBS, MS
Professor and Head

Department of
Radiotherapy

Vyas VJ, MBBS, MD
Professor and Head

Correspondence to:
Dr Bhupendra Kumar
Mehra
Type III,
Quarter No 8,
Kasturba Health
Society Campus,
Mahatma Gandhi
Institute of Medical
Sciences,
Sevagram,
Wardha 442102,
Maharashtra,
India
Tel: (91) 982 281 7958
Email: drbhupi_mehra
@rediffmail.com

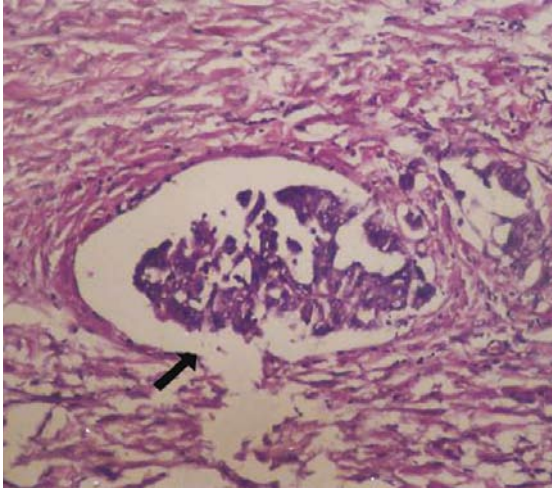


Fig. 2 Photomicrograph shows tumour cells forming a papillary configuration inside a space surrounded by fibrous tissue (Haematoxylin & eosin, $\times 200$).

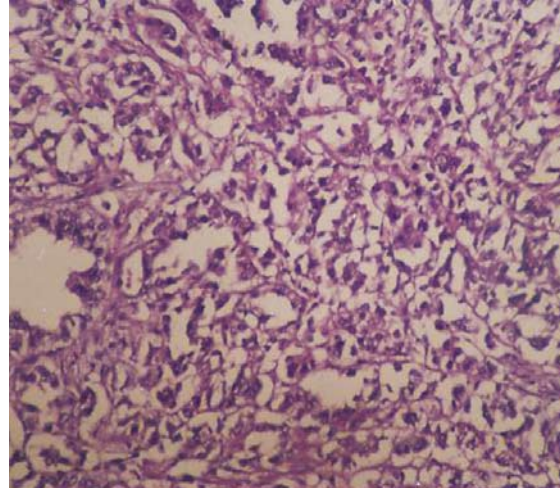


Fig. 3 Photomicrograph shows tumour cells arranged in a glandular pattern (Haematoxylin & eosin, $\times 200$).

tomography of the abdomen were normal. Considering all the above investigations, it was confirmed that the tumour was of primary origin. The postoperative recovery was uneventful. Our patient was initially uncontactable for follow-up, but subsequently returned for follow-up, and to date, no metastasis has been detected.

DISCUSSION

Carcinoma of the rete testis is a rare tumour, occurring most commonly in the fourth and fifth decades of life. However, patients may range from 20 to 80 years of age. A total of 44 cases have been reported. The carcinoma can affect either side, and occasionally may be bilateral. All races are equally affected. This is probably the fourth case being reported from India,^(1,3,4) but to our knowledge, it is the first case of adenocarcinoma rete testis which presented as haematocele. Carcinoma of the rete testis has usual association with hydrocele, epididymitis, inguinal hernia and occasionally, with undescended testis. In our case, it was a haematocele. Adenocarcinoma of the rete testis is generally diagnosed clinically as a solid or cystic intrascrotal swelling. In 25% of cases, it is misdiagnosed as hydrocele.

The tumour is confirmed only on histological diagnosis, which is governed by the Nochomovitz criteria. This includes: (1) location of the tumour around the hilum; (2) no involvement of the tunica; (3) histological evidence of tumour origin from the rete testis and demonstration of transition from normal to tumour epithelium; and 4) no evidence of teratoma or any other primary tumour elsewhere in

the body.^(2,5) We believe that these criteria have been fulfilled satisfactorily in the current case. On gross examination, the tumour may show a solid, nodular or cystic surface. Microscopically, there are three patterns. The papillary pattern, which is commonest, represents glomeruli with numerous microvilli projecting into cystic spaces. The rete epithelium shows deep narrow nuclear invaginations, apparent nuclear lobulations, small pleomorphic electron-dense membrane-bound granules in the basal cytoplasm, lipid droplets in the apical cytoplasm and bulbous cytoplasmic projections along the apical surface cells. The glandular pattern consists of moderately- to poorly-differentiated glands. Solid pattern shows irregular arrangement of cells along with greater cellular and nuclear pleomorphism. The differential diagnoses include malignant mesothelioma of the tunica, serous mullerian tumours of the testis, and Sertoli cell tumours.⁽⁶⁾ Mesothelioma involves the tunica. The reactive proliferations of the testis, which has varied composition on histopathology, can also be differentiated. The incidence of secondary testicular tumours generally ranges from 0.02% to 2.5%. The prostate is the most common primary site after leukaemia and lymphoma. Metastatic neoplasm from the prostate and lung is another differential diagnosis.

Adenocarcinoma of the rete testis is an aggressive malignant neoplasm. The treatment is primarily surgery (high inguinal orchidectomy).⁽⁷⁾ Radical orchidectomy, retroperitoneal lymph node dissection, radiotherapy and chemotherapy have been tried alone or in combination, with no fruitful results. The stage at diagnosis or any form of therapy has no influence

on final outcome, and prognosis remains poor. Patients seldom survive longer than one year, although survival rates up to five years without metastasis have been reported. Careful follow-up is advisable. Our patient did return, albeit belatedly for follow-up and till now, no metastasis has been detected.

REFERENCES

1. Menon PK, Vasudevarao, Sabhiki A, et al. A case of carcinoma rete testis. *Indian J Cancer* 2002; 39:106-11.
2. Nochomovitz LE, Orenstein JM. Adenocarcinoma of the rete testis. Case report, ultrastructural observations, and clinicopathologic correlates. *Am J Surg Pathol* 1984; 8:625-34.
3. Nair MB, Mohankumar V. Carcinoma of the rete testis resembling Sertoli-cell-tumour. *Indian J Pathol Bacteriol* 1966; 39:337-9.
4. Moghe KV, Soni PH. Carcinoma of rete testis – a case report. *Indian J Pathol Bacteriol* 1971; 14:184-8.
5. Young RH, Scully RE. Miscellaneous neoplasm and nonneoplastic lesions. In: Talerma A, Roth LM, eds. *Pathology of the testis and its adenexa*. New York: Churchill Livingstone, 1986:93-129.
6. Young RH, Scully RE. Testicular and paratesticular tumors and tumor-like lesions of ovarian common epithelial and müllerian types. A report of four cases and review of the literature. *Am J Clin Pathol* 1986; 86:146-52.
7. Fukunaga M, Aizawa S, Furusato M, Akasaka Y, Machida T. Papillary adenocarcinoma of the rete testis: a case report. *Cancer* 1982; 50:134-8.