

# Management of extensive subcutaneous emphysema and pneumomediastinum by micro-drainage: time for a re-think?

Srinivas R, Singh N, Agarwal R, Aggarwal A N

## ABSTRACT

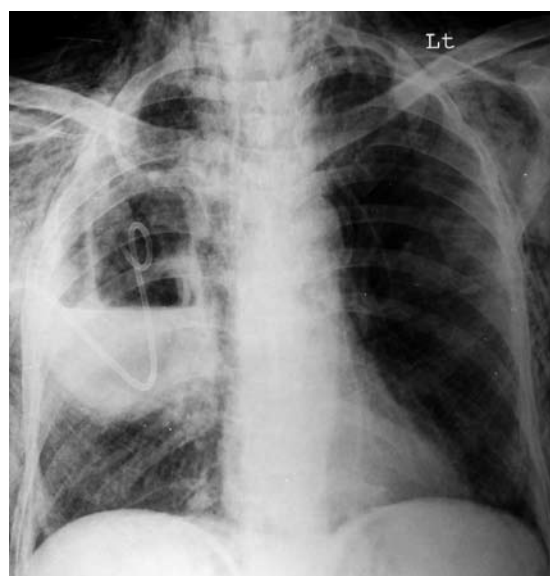
**Extensive subcutaneous emphysema (ESE) is not only disfiguring, uncomfortable and alarming for the patient, but can rarely be associated with airway compromise, respiratory failure and death. Traditionally considered a cosmetic nuisance, few reports on interventions to relieve ESE exist. Most interventions are too invasive and have not been widely used. Fenestrated catheters have been reported to be effective in ESE. We report our experience on micro-drainage with a fenestrated catheter and compressive massage in a 50-year-old man with ESE following pigtail insertion for drainage of lung abscess. The apparatus is easily constructed and the procedure is simple, painless, minimally invasive, highly effective and cosmetically aesthetic. Placement of an underwater trap and visualisation of bubbling can be used as end-points for adequate compressive massage. Routine management with this catheter can be considered as the procedure of choice for ESE.**

**Keywords: chronic obstructive pulmonary disease, extensive subcutaneous emphysema, micro-drainage, pigtail catheter, pneumomediastinum, subcutaneous emphysema**

*Singapore Med J 2007;48(12):e323–e326*

## INTRODUCTION

Subcutaneous emphysema (SE) without pneumothorax is an uncommon complication after pigtail drainage of pyogenic lung abscess. Infrequently, SE and pneumomediastinum have been reported spontaneously in tubercular cavities and cavitating malignancies. We report a 50-year-old man with chronic obstructive pulmonary disease (COPD), who presented with a large pyogenic lung abscess. In view of poor postural drainage and toxemia, he underwent pigtail drainage of



**Fig. 1** Frontal chest radiograph shows extensive right-sided cavity with air-fluid level and pigtail in-situ. Extensive subcutaneous air and pneumomediastinum are also evident.

the abscess. Extensive SE (ESE), pneumomediastinum and pneumoperitoneum without pneumothorax developed at 48 hours post-procedure. Insertion of a fenestrated catheter with underwater seal and compressive massage was done in view of the minimally invasive nature of the procedure,<sup>(1)</sup> with dramatic reduction of SE. We report on modification of the technique, duration of application, end points and advantages of this modality.

## CASE REPORT

A 50-year-old man, with known diabetes mellitus, presented to our chest clinic with history of fever, cough with expectoration, and anorexia with a two-week duration. He had a smoking history of 50 pack-years and had been diagnosed with COPD for the last two years. Upon examination, his temperature was 38.5°C, pulse rate 104 beats/minute, respiratory rate 36 breaths/minute and blood pressure of 134/82 mmHg. Auscultation of the chest revealed reduced breath

Department of Pulmonary Medicine, Postgraduate Institute of Medical Education and Research, Sector 12, Chandigarh 160012, India

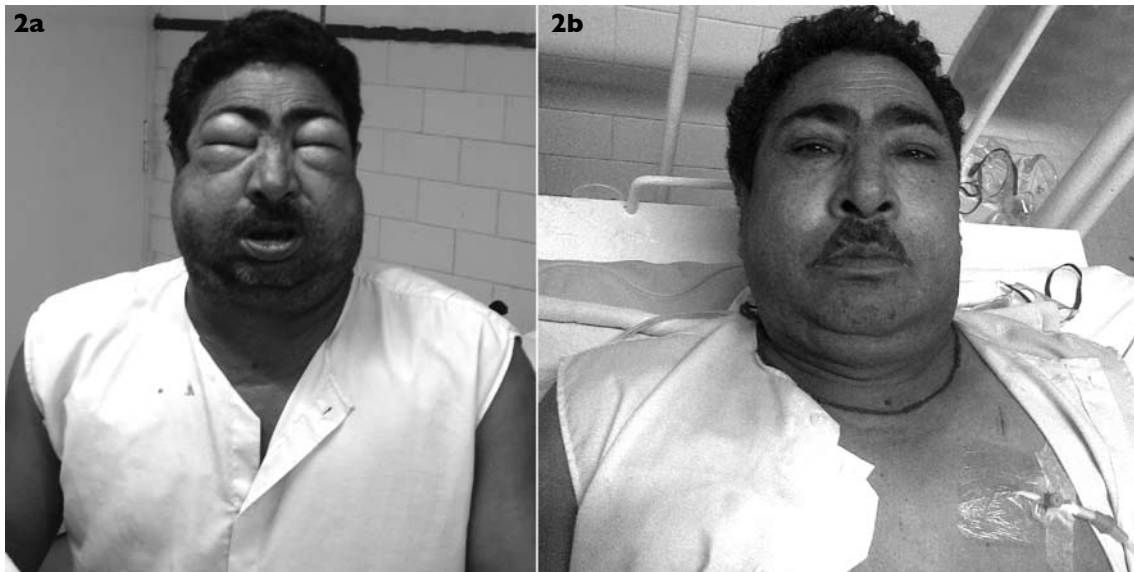Srinivas R, MBBS, MD  
Senior Resident

Singh N, MBBS, MD, DM  
Assistant Professor


Agarwal R, MBBS, MD, DM  
Assistant Professor

Aggarwal AN, MBBS, MD, DM  
Associate Professor

**Correspondence to:**  
Dr Rajagopala Srinivas  
Tel: (91) 172 275 6821  
Fax: (91) 172 274 5959  
Email: visitsrinivasan@gmail.com



**Fig. 2** Clinical photograph shows our patient with (a) extensive subcutaneous emphysema causing closure of palpebral fissure; and (b) after resolution 24 hours later, with the fenestrated microcatheter in-situ.



**Fig. 3** Close-up photograph shows the modified microcatheter with spiral fenestrations.

sounds in the right mammary area with crepitations. Rest of the examination was unremarkable. Chest radiograph revealed a large lung abscess on the right lower lobe (Fig. 1). He was admitted for evaluation and parenteral antibiotic therapy. Investigations revealed a leucocyte count of 14,000/ $\mu$ L with toxic granules, fasting blood glucose of 213 mg/dL and serum creatinine of 1.2 mg/dL. He was started on intravenous cefotaxime and clindamycin, and intensive glycaemic control with subcutaneous insulin. Sputum cultures showed *Klebsiella pneumoniae* (sensitive to cefotaxime) and three smears for acid-fast bacilli were negative.

He continued to be febrile, with minimal expectoration and persistent pus-fluid level in the cavity and underwent pigtail drainage of the abscess. At 48 hours after the procedure, he developed progressively increasing subcutaneous emphysema, pneumomediastinum and

pneumoperitoneum without pneumothorax, which was confirmed on computed tomography. ESE causing dysphonia and closure of palpebral fissures caused severe anxiety in the patient that could not be allayed (Fig. 2a). He did not develop respiratory failure or evidence of upper airway obstruction. In view of progressive worsening SE and extreme anxiety of the patient, a literature review on possible interventions in ESE was done. A 14-gauge catheter (Fig. 3) was modified according to a technique described earlier.<sup>(1)</sup>

Briefly, a 14-gauge venflon (Becton Dickinson Infusion therapy AB SE-251 06, Helsingborg, Sweden,) was taken and fenestrations created by leaving the catheter over the steel stylette, using a scalpel blade to create the holes. To enhance the rigidity of the catheter, the fenestrations were created in a spiral pattern. 5% w/v povidone-iodine was used to prepare the skin and local anaesthesia was achieved by infiltrating 2% lignocaine subcutaneously. The modified fenestrated catheter was inserted 2–3 cm lateral to the mid-clavicular line over the third rib at 45° angle until the tip was about 0.5–1 cm deep into the skin. The angle of insertion was then decreased, and the catheter was directed medially so that it was completely inserted and the tip was about 1–1.5 cm deep into the skin. The catheter was then secured by an adhesive and attached to an underwater seal for the duration of drainage.

We observed minimal drainage of gas post-procedure, and reasoned that poor drainage was due to the low-pressure differences across the system.

Active compressive massage face downwards and arm upwards towards the catheter was begun to elevate tissue hydrostatic pressures and facilitate drainage. Dramatic bubbling and significant improvement in SE was noted, and over the next few hours, there was resolution of the SE. The catheter could be removed at 24 hours with no recurrence of SE (Fig 2b). He completed his parenteral antibiotic therapy with resolution of symptoms and was discharged after two weeks of admission.

## DISCUSSION

Aberrant extra-alveolar air starts with alveolar rupture and leakage of air into the pulmonary interstitium. This air subsequently tracks along the perivascular space to the mediastinum. Further extension along tissue planes leads to subcutaneous emphysema, pneumopericardium and pneumoperitoneum.<sup>(2)</sup> The mediastinal pleura may rupture, causing pneumothorax. When leakage of air is greater than reabsorption, progressive accumulation in various tissue planes occurs. Commonly, the least resistance to expansion is offered by subcutaneous tissue, leading to worsening SE. Any SE on positive pressure ventilation, causing palpable cutaneous tension, palpebral closure, dysphagia, and dysphonia or associated with pneumoperitoneum, airway compromise, "tension phenomenon" and respiratory failure is labelled extensive subcutaneous emphysema.<sup>(1,3)</sup> ESE is not a mere tactile curiosity, but can rarely be associated with extreme discomfort, disfigurement, anxiety, protracted hospital stays,<sup>(1,4)</sup> upper airway obstruction,<sup>(5)</sup> respiratory failure,<sup>(6)</sup> pacemaker dysfunction,<sup>(7)</sup> and systemic air embolism.<sup>(4)</sup>

Several techniques have been reported to treat ESE. These have been either too invasive or ineffective. Methods of therapy include placing chest tubes<sup>(8)</sup>, infraclavicular "blow holes",<sup>(9)</sup> tracheostomy, subcutaneous pig-tail<sup>(10)</sup> or large-bore drains,<sup>(11)</sup> trocar-type drains with suction<sup>(12)</sup> and fenestrated catheters.<sup>(1,13,14)</sup> The value of placing chest tubes prophylactically to prevent pneumothorax in ESE is doubtful. The role of tracheostomy, other than for airway compromise, is controversial. Infraclavicular "blow-holes" have been considered the procedure of choice for ESE.<sup>(4)</sup> However, the procedure's utility is limited by scab formation, infection, residual scars, and is time-consuming. Drainage of the subcutaneous space by drains and pigtailed catheters need surgical expertise, are invasive, need suction and are liable to be infected. Locally-modified fenestrated catheters have recently been employed for management of ESE.<sup>(1)</sup> The equipment is widely available and easily modified, is simple to insert, maintain and is effective, painless,

minimally invasive, not complicated by infection and aesthetically appropriate.<sup>(1)</sup> However, mere adequate positioning is unlikely to resolve ESE, because of the low pressure gradients involved between the interstitial compartment and atmosphere.

The key step is to increase the interstitial hydrostatic pressure by sequential massage from the face downwards and arm upwards towards the catheter. We observed that the resolution of ESE after catheter placement started only after the above step. Placement of an underwater trap and visualisation of bubbling can be used as end-points for adequate compressive massage. Placement of incisions to place catheters which may also allow exit of residual air has been advocated<sup>(3)</sup> but it detracts from the minimally invasive nature of the procedure and may be obviated by the above technique. The time to complete resolution was 12 hours and the catheter could be removed at 24 hours. This was significantly shorter, despite the extensive nature of extra-alveolar air, compared to earlier reports (median 3.7 days).<sup>(3)</sup> This can be attributed to clear identification of goal (air bubbling) to be attained by compressive massages or the sealing of air-leak concurrent to catheter insertion. Ancillary adjuncts like adequate analgesia, cough suppression and supplemental oxygen therapy may have hastened recovery. Given the advantages of this technique, routine management with this catheter and compressive massage can be considered as the procedure of choice and may be more extensively employed.

In conclusion, ESE can be associated with extreme discomfort, disfigurement, anxiety, longer hospital stays and respiratory failure. Fenestrated catheters are simple to insert, maintain and the procedure is effective, painless, minimally invasive, infrequently complicated by infection and aesthetically appropriate. The key step is to increase the interstitial hydrostatic pressure by sequential massage. Placement of an underwater trap and visualisation of bubbling can be used as end-points for adequate compressive massage. Routine management with this catheter can be considered as the procedure of choice for ESE.

## REFERENCES

1. Beck PL, Heitman SJ, Mody CH. Simple construction of a subcutaneous catheter for treatment of severe subcutaneous emphysema. *Chest* 2002; 121:647-9.
2. Macklin CC. Transport of air along sheaths of pulmonic blood vessels from alveoli to mediastinum: clinical implications. *Arch Intern Med* 1939; 64:913-26.
3. Cesario A, Margaritora S, Porziella V, Granone P. Microdrainage via open technique in severe subcutaneous emphysema. *Chest* 2003; 123:2161-2.
4. Mason RJ, Murray JF, Broaddus VC, Nadel JA. Mediastinal disorders. In: Murray JF, Nadel JA, eds. *Murray and Nadel's Textbook of Respiratory Medicine*. 4th ed. Philadelphia: Elsevier Saunders, 2005: 2039-49.

5. Gibney RT, Finnegan B, FitzGerald MX, Lynch V. Upper airway obstruction caused by massive subcutaneous emphysema. *Intensive Care Med* 1984; 10:43-4.
6. Conetta R, Barman AA, Iakovou C, Masakayan RJ. Acute ventilatory failure from massive subcutaneous emphysema. *Chest* 1993; 104:978-80.
7. Giroud D, Goy JJ. Pacemaker malfunction due to subcutaneous emphysema. *Int J Cardiol* 1990; 26:234-6.
8. Mattox KL, Allen MK. Systematic approach to pneumothorax, hemothorax, pneumomediastinum and subcutaneous emphysema. *Injury* 1986; 17:309-12.
9. Herlan DB, Landreneau RJ, Ferson PF. Massive spontaneous subcutaneous emphysema. Acute management with infraclavicular "blow holes". *Chest* 1992; 102:503-5.
10. Crouch JD, Keagy BA, Delany DJ. "Pigtail" catheter drainage in thoracic surgery. *Am Rev Respir Dis* 1987; 136:174-5.
11. Kelly MC, McGuigan JA, Allen RW. Relief of tension subcutaneous emphysema using a large bore subcutaneous drain. *Anaesthesia* 1995; 50:1077-9.
12. Terada Y, Matsunobe S, Nemoto T, Tsuda T, Shimuzu Y. Palliation of severe subcutaneous emphysema with use of a trocar-type chest tube as a subcutaneous drain. *Chest* 1993; 103:323.
13. Leo F, Solli P, Veronesi G, Spaggiari L, Pastorino U. Efficacy of microdrainage in severe subcutaneous emphysema. *Chest* 2002; 122:1498-9.
14. Ozdogan M, Gurer A, Gokakin AK, et al. Treatment of severe subcutaneous emphysema by fenestrated angiocatheter. *Intensive Care Med* 2005; 31:168.