

# Arched left gonadal artery over the left renal vein associated with double left renal artery

Ranade A V, Rai R, Prahu L V, Mangala K, Nayak S R

## ABSTRACT

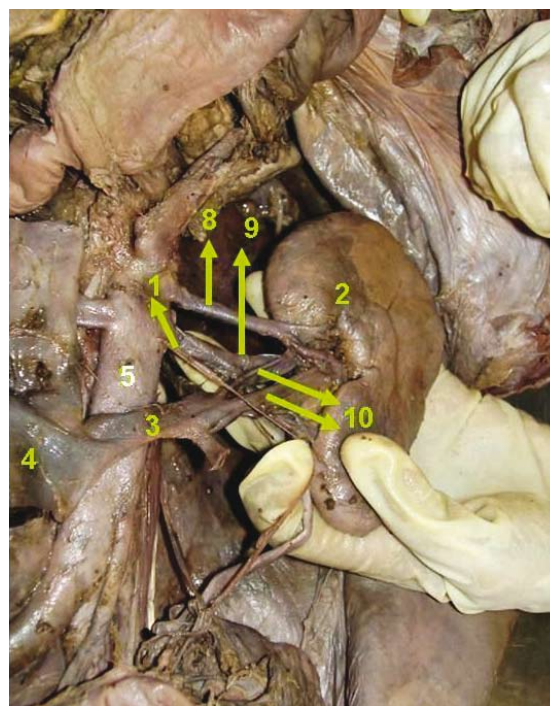
Variations in the anatomical relationship of the gonadal arteries to the renal vessels are frequently reported. We present, on a male cadaver, an unusual origin and course of a left testicular artery arching over the left renal vein along with double renal arteries. The development of this anomaly is discussed in detail. Compression of the left renal vein between the abdominal aorta and the superior mesenteric artery usually induces left renal vein hypertension, resulting in varicocele. We propose that the arching of left testicular artery over the left renal vein could be an additional possible cause of the left renal vein compression. Therefore, knowledge of the possible existence of arching gonadal vessels in relation to the renal vein could be of paramount importance to vascular surgeons and urologists during surgery in the retroperitoneal region.

**Keywords:** anomalous gonadal vessels, arched left gonadal artery, gonadal artery variations, gonadal artery development, left testicular artery, varicocele

*Singapore Med J 2007;48(12):e332–e334*

## INTRODUCTION

Reproduction is a fundamental process that allows the living organisms to preserve their progeny and evolve by transmitting genes. The testis is an important reproductive organ, upon which the survival of the human species depends.<sup>(1)</sup> The testicular vessels play major roles in the thermoregulation of this organ.<sup>(1)</sup> Normally, each testicular artery arises anteriorly from the aorta a little inferior to the renal arteries. According to Notkovich, the gonadal arteries have been classified into three types based on their anatomical relationship to the renal vein. These are: Type I, in which the gonadal arteries arise from the aorta behind or below the renal vein and proceed downwards and laterally into the inguinal canal; Type II, where the artery



**Fig. 1** Photograph shows the left testicular artery along with double left renal arteries after reflecting the inferior vena cava downwards.

1. Left testicular artery; 2. Left kidney; 3. Left renal vein; 4. Inferior vena cava; 5. Abdominal aorta; 8. Superior left renal artery; 9. Inferior left renal artery; and 10. Double left renal vein.

arises from the aorta above the level of the renal vein and crosses in front of it; and Type III, where the gonadal arteries arise from the aorta behind or below the renal vein and courses upwards to arch over the renal vein.<sup>(2)</sup>

Compression of the left renal vein can be a possible aetiological factor of idiopathic varicocele in man and/or orthostatic albuminuria<sup>(2)</sup> and can also lead to a phenomenon called the “nutcracker effect”, where the left renal vein is compressed between the aorta and superior mesenteric vessels.<sup>(3)</sup> We report a case in which the left testicular artery arched over the left renal vein. The development of these anomalies for the unusual vascular pattern coupled with the possible importance of this and similar anomalies in causing varicocele, and the related clinical and pathological importance of this case, are discussed.

Department of Anatomy,  
Kasturba Medical College,  
Mangalore 575004,  
Karnataka,  
India

Ranade AV, PhD  
Assistant Professor

Rai R, MSc  
Senior Lecturer

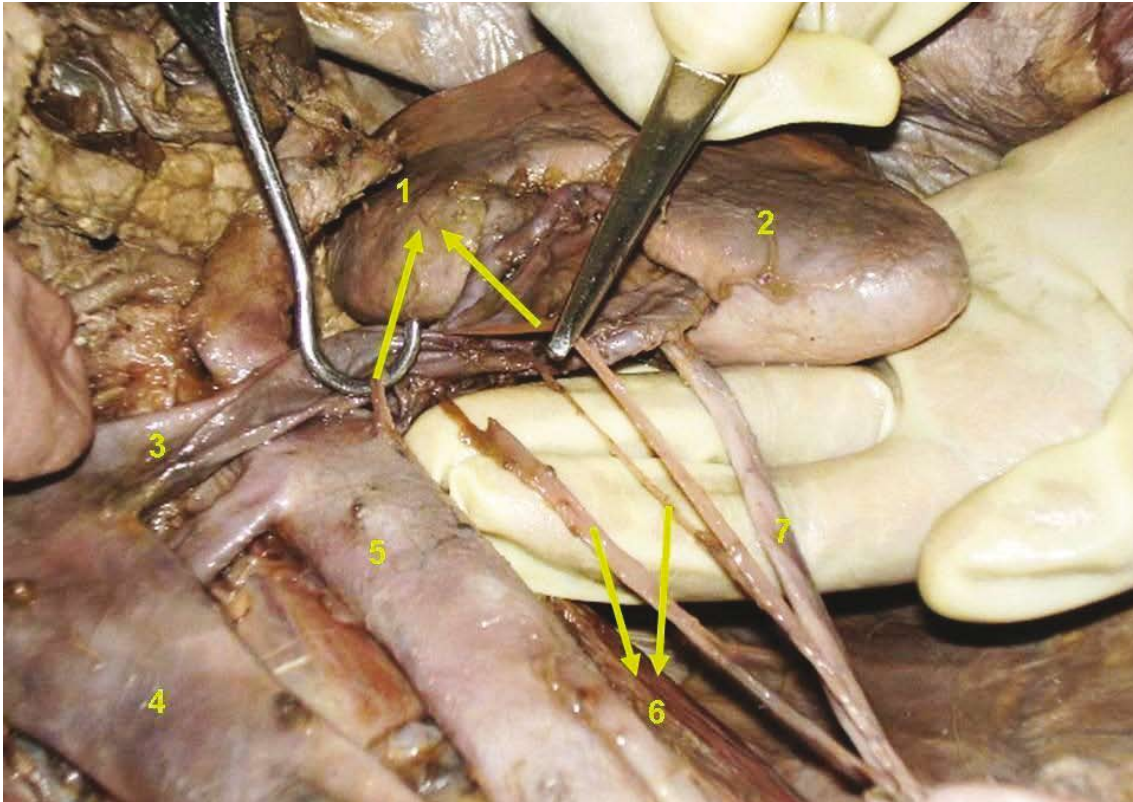
Prahu LV, MSc  
Professor and Head

Nayak SR, MSc  
Lecturer

Department of Anatomy,  
Yenepoya Medical College,  
Mangalore 575018,  
Karnataka,  
India

Mangala K, MSc  
Assistant Professor

**Correspondence to:**  
Dr Anu V Ranade  
Tel: (91) 824 221 1796  
Fax: (91) 824 242 8183  
Email: anuranade@gmail.com



**Fig. 2** Photograph shows the left testicular artery arching over the left renal vein.

1. Left testicular artery; 2. Left kidney; 3. Left renal vein; 4. Inferior vena cava; 5. Abdominal aorta; 6. Double left testicular veins; 7. Ureter

## CASE REPORT

An abnormal course of the left testicular artery was uncovered during routine dissection of the posterior abdominal wall in our first-year medical class. Two renal arteries arose from the abdominal aorta at a distance of about 2 cm from each other on the left side (Fig. 1). The left testicular artery arose from the anterior surface of the abdominal aorta below the origin of the inferior renal artery and ascended upwards and arched over the left renal vein and passes downwards and laterally (Fig. 2). Moreover, two renal veins emerged from the hilum and united to form a single renal vein on the left side. Two testicular veins that drained into the left renal vein separately accompany the left testicular artery.

## DISCUSSION

The variations of origin and course of arteries of different organs are not only of anatomical and embryological interest, but also of practical clinical importance. For example, when these variations are possibly the agents of pathological conditions, or in surgery, when knowledge of them can result in more accurate treatment.<sup>(2)</sup> The variations of the testicular

arteries can be easily understood in relation to the embryological development of the gonadal glands and kidneys and their vascular supply. The gonadal arteries are persistent branches of mesonephric arteries that develop cranially and caudally to the renal pedicle. If the latter persists, they produce the type I. If the former persists, they become type II by crossing the renal pedicle with the descent of the gonad. If the kidney ascends much higher, carrying its renal vein to a higher level than the origin of the gonadal artery, the latter will be forced to follow an arched course around that vein giving rise to the type III. The fact that the kidney ascends on the left side, generally higher than on the right, gives us the explanation for the higher frequency of the type III on left side.<sup>(2)</sup>

The embryological developmental explanation for the presence of accessory renal arteries could be due to the continuous change in the blood supply during the embryonic and early foetal life. A single renal artery is present in about 75% of people; about 25% of adult kidneys have two or four renal arteries. An accessory renal artery to the inferior pole may cross anterior to the ureter and obstruct it, causing hydronephrosis-distension of the renal pelvis and

calyces with urine. It is important to be aware that accessory renal arteries are end-arteries. Consequently, if an accessory renal artery is damaged or ligated, the part of the kidney supplied by it is likely to become ischaemic.<sup>(4)</sup>

Presumably, due to anatomical difference, varicocele are much more common on the left side. The incidence of bilaterality ranges from 15% to 50%. But isolated right varicoceles are fairly rare.<sup>(5)</sup> The left testicular vein empties into the left renal vein. It is about 8–10 cm longer than the right testicular vein, which drains into the inferior vena cava. This is believed to result in an increased hydrostatic pressure that is transmitted below the vein through the scrotal pampiniform plexus, causing dilatation and tortuosity of these vessels.<sup>(5)</sup> Palpable unilateral varicocele occurs on the left side in 85%–90% of the cases.<sup>(6)</sup> The high incidence of varicocele on the left side, compared to that of the right side is often attributed to the following causes:<sup>(7)</sup>

1. Left testicular vein joins left renal vein at a right angle, while the right testicular vein joins the inferior vena cava. The left testicular vein is a few centimeters higher than the right one with higher hydrostatic pressure.
2. The left testicular vein is longer than the right testicular vein, as the left testis is at a lower level. Hence, it has to bear a larger column of blood and therefore more pressure.
3. The loaded pelvic colon compresses the left testicular vein causing back pressure.
4. The left renal vein may be sandwiched between the abdominal aorta and trunk of the superior mesenteric vessels, increasing the pressure in the left renal vein with consequent dilatation of the left testicular vein. This theory is called “nutcracker phenomenon”.
5. The testicular artery may arch over the left renal vein and cause compression of the left renal vein.

Clinically, persistent left renal vein hypertension can cause the development of collateral veins and varicocele.<sup>(8)</sup> Nishimura et al reported that 88% (14 of 16) of patients with left renal bleeding of unknown origin had left renal vein hypertension.<sup>(9)</sup> The results suggest that the left renal vein hypertension is a cause of haematuria in a large percentage of patients with left renal bleeding of unknown origin. Compression of left renal vein by the arteries particularly when the subject is in the erect position may raise the venous pressure in the vein and be a factor in the aetiology of varicocele and proteinuria.<sup>(2,10)</sup> Knowledge of possible existence of arching of gonadal vessels in relation to the renal vein could be of paramount importance to the vascular surgeons and urologists during surgery in the retroperitoneal region.

## REFERENCES

1. Asala S, Chaudhary SC, Masumbuko-Kahamba N, Bidmos M. Anatomical variations in the human testicular blood vessels. *Ann Anat* 2001; 183:545-9.
2. Notkovich H. Variations of the testicular and ovarian arteries in relation to the renal pedicle. *Surg Gynecol Obstet* 1956; 103:487-95.
3. Hanna HE, Santella RN, Zawada ET Jr, Masterson TE. Nutcracker Syndrome: An under diagnosed cause for hematuria. *S D J Med* 1997; 50:429-36.
4. Moore KL, Persaud TVN. *The Developing Human: Clinically Oriented Embryology*. 6th ed. Philadelphia: WB Saunders, 1998.
5. Shafik A, Bedeir GA. Venous tension patterns in cord veins. I. In normal and varicocele individuals. *J Urol* 1980; 123:383-5.
6. Morag B, Rubinstein ZJ, Madgar I, Lunnenfeld B. The role of spermatic venography after surgical high ligation of the left spermatic veins: diagnosis and percutaneous occlusion. *Urol Radiol*. 1985; 7:32-4.
7. Kass EJ, Reitelman C. Adolescent varicocele. *Urol Clin North Am* 1995; 22:151-9.
8. Naito M, Terayama H, Nakamura Y, et al. Left testicular artery arching over the ipsilateral renal vein. *Asian J Androl* 2006; 8:107-10.
9. Nishimura Y, Fushiki M, Yoshida M, et al. Left renal vein hypertension in patients with left renal bleeding of unknown origin. *Radiology* 1986; 160:663-7.
10. Nathan H. Observations on aberrant renal arteries curving around and compressing the renal vein; possible relationship to orthostatic proteinuria and to orthostatic hypertension. *Circulation* 1958; 18:1131-4.