

Diffuse nodular hyperplasia of Brunner's gland presenting as upper gastrointestinal haemorrhage

Chattopadhyay P, Kundu A K, Bhattacharyya S, Bandyopadhyay A

ABSTRACT

Brunner's gland adenoma is a very unusual cause of upper gastrointestinal bleeding. We report a 16-year-old boy who presented with upper gastrointestinal haemorrhage from diffuse nodular hyperplasia of Brunner's gland without involvement of the first part of the duodenum. The patient was managed conservatively during his hospital stay, and was doing well without any recurrence after nine months of follow-up.

Keywords: Brunner's gland adenoma, duodenal polyp, nodular hyperplasia of Brunner's gland, upper gastrointestinal haemorrhage

Singapore Med J 2008; 49(1): 81-83

INTRODUCTION

In clinical practice, common causes of upper gastrointestinal haemorrhage are peptic ulcer disease, drug-induced gastritis, oesophageal varices, portal hypertensive gastropathy, and malignancy of the stomach and the duodenum. Duodenal polyps in isolation are not commonly found to be the source of bleeding. Brunner's gland adenoma (BGA), presenting as duodenal polyps, is a very rare cause of upper gastrointestinal haemorrhage. The disease spectrum of BGA includes diffuse nodular hyperplasia, circumscribed nodular hyperplasia, and Brunner's gland adenoma. It is still rarer to encounter diffuse nodular hyperplasia of Brunner's gland which spares the first part of the duodenum, and also presents with upper gastrointestinal bleeding. We report such a rare occurrence in a 16-year-old boy.

CASE REPORT

A 16-year-old boy, a non-smoker and non-drinker, presented to the department of medicine with a history of passage of black tarry stools for two days. He denied any recent intake of non-steroidal anti-inflammatory drugs. Enquiry revealed mild upper abdominal discomfort and post-prandial bloating sensation for the last few months. Although the patient was haemodynamically stable, he was admitted for investigations

and was prescribed proton-pump inhibitors. The vital signs were stable, he was not anaemic, and general physical examination was normal. Abdomen was soft, without any tender point or palpable organomegaly. On the next day, he had a bout of haematemesis. An upper gastrointestinal endoscopy revealed a normal-looking stomach and first part of duodenum (D1). Starting from the posterior wall of the junction of D1 and second part of duodenum (D2), multiple small sessile polyps about 0.5–0.7 cm in length, was found up to the distal D2 segment (Fig. 1). The mucosa over the polyps was smooth and whitish, without any ulceration or erosion.

A biopsy was taken from one of the polyps. The lesion showed proliferation and aggregation of normal Brunner's gland in a lobulated manner. The mucosa showed villi and feature of compression from the mass beneath the mucosa at one area (Fig 2). This feature was important, considering the young age of the patient, which suggested a developing process. No dysplastic cell, focus of malignancy or any other mature tissue component was seen. The histological diagnosis was Brunner's gland adenoma. A colonoscopy that was performed was normal. Barium study of the small bowel was unremarkable. As the lesions were too small and diffuse in nature, a diagnosis of nodular hyperplasia of Brunner's gland was made; endoscopic polypectomy or removal was not feasible and the patient was advised regular clinical follow-up. Even after nine months, he was asymptomatic without any further episode of bleeding.

DISCUSSION

Brunner's gland, originally thought to be pancreas secundarium by Brunner (1688), was correctly identified by Middeldorf (1846) as submucosal glands separate from duodenal glands, but structurally and functionally similar to glands of pylorus. Brunner's glands are mucin-secreting acinar glands situated in the deep mucosa and submucosa of duodenum, secreting mucus, pepsinogen and urogastrone in response to acid stimulation. They extend from pylorus distally for a variable distance usually up to the D2 segment, although in rare instances, it may reach up to the proximal jejunum, even the distal ileum.⁽¹⁾ In infants, Brunner's gland

Department of
Medicine,
Nil Ratan Sircar
Medical College,
138 AJC Bose Road,
Kolkata 700014,
West Bengal,
India

Chattopadhyay P, MD
Assistant Professor

Kundu AK, MD
Associate Professor

Department of
Pathology

Bhattacharyya S, MD
Assistant Professor

Endoscopy Unit

Bandyopadhyay A, DNB
Head

Correspondence to:
Dr Partha Chattopadhyay
West Jagtala – Batamore,
PO Maheshtala,
South 24-Parganas,
Kolkata 700141,
West Bengal,
India
Tel: (91) 332 490 3176
Fax: (91) 332 358 7282
Email: drpartha73@sify.
com; drpartha73@
hotmail.com

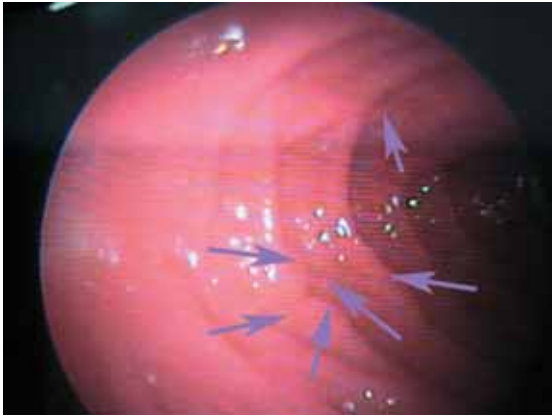


Fig. 1 Endoscopic photograph shows multiple small sessile polyps in the second part of the duodenum.

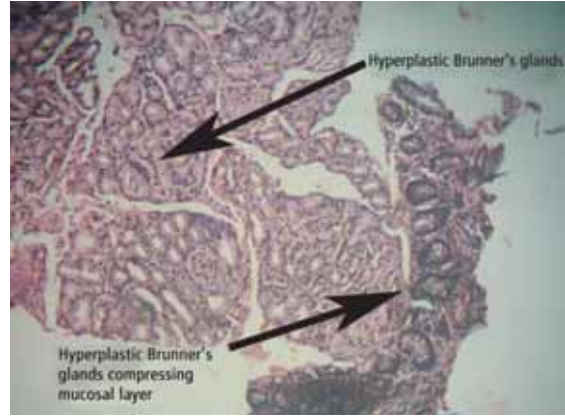


Fig. 2 Photomicrograph of a sessile polyp from the D2 segment shows proliferation and aggregation of normal Brunner's gland in a lobulated manner; the mucosa is compressed by the underlying mass at one area. (Haematoxylin & eosin, $\times 200$).

occupies 55% of total duodenal area; by 50 years of age, this drops to 35%.⁽²⁾ Adenoma of Brunner's gland was first reported by Cruveilhier in 1835.⁽³⁾ They account for 10.6% of benign duodenal tumours. Since then, almost 150 cases have been reported in peer-reviewed literature. The exact pathogenesis of BGA still remains elusive. Gastric hyperacidity was originally thought to induce hyperplasia by gland stimulation,⁽⁴⁾ but only 45% of patients had hyperacidity and 20% had hypoacidity. Concurrent *Helicobacter pylori* infection is very common in patients with BGA, but its pathogenic role in the development of Brunner's gland hyperplasia remains unclear.⁽⁵⁾ Proliferations in response to local irritation or parasympathetic hyperactivity were other suggested mechanisms.⁽⁶⁾ Association with peptic ulcer disease, chronic renal failure and chronic pancreatitis has been described.⁽⁷⁾

Feyrter classified three types of Brunner's gland hyperplasia: Type 1 has diffuse nodular hyperplasia confined to the mucosa with multiple sessile projections spread throughout the duodenum; Type 2 is the most common type and is limited to the duodenal bulb as circumscribed nodular hyperplasia, usually less than 1 cm in size; and Type 3 is adenomatous hyperplasia (also known as Brunner's gland hamartoma or adenoma), which generally present as a single polypoid lesion, with its size ranging from 0.7 to 12 cm, with a mean of 4 cm.⁽⁸⁾ Most BGAs are pedunculated and their incidence decreases from the proximal to distal duodenum. Some authors also describe adenoma with acute and/or chronic duodenitis, and adenoma with predominant erosive duodenitis.⁽⁹⁾ Hyperplasia refers to multiple lesions (usually less than 1 cm) and adenoma refers to a lesion larger than 1 cm.⁽¹⁰⁾ Brunner's gland adenomas are mostly benign, but malignant change associated with the lesion has been reported in two cases, including one patient with

microcarcinoid tumours.^(11,12) In hyperplasia of Brunner's glands, the microscopic picture is one of large numbers of lobules of well-differentiated, normal-looking Brunner's glands without cellular atypia in their usual alveolar pattern. Large lymphoid patches may be present, and the lobules are divided by musculofibrous strands believed to be extensions of the muscularis mucosa. The lobules may be in the mucosa and submucosa and may elevate the normal mucosa above them, forming sessile projections, or they may have a stalk of normal duodenal mucosa and present as a pedunculated polypoid mass.⁽¹³⁾

BGA mostly present in middle age without any gender predominance;⁽⁶⁾ however, cases have been described from early infancy to even 80 years of age.⁽¹⁴⁾ Three types of clinical picture have been described by Levine et al.⁽⁶⁾ An asymptomatic group comprising 11% were detected incidentally; 40%–50% present with upper gastrointestinal bleeding—melaena, fatigue, malaise, anaemia.⁽¹⁵⁾ Melaena is four times commoner than haematemesis. Distal tumours, rather than those found in the D1 segment, are more likely to bleed.⁽⁶⁾ Although blood loss is usually occult, massive even fatal haemorrhage has been described. 50% of cases present with obstructive symptoms, such as epigastric pain, nausea, vomiting, and postprandial discomfort.⁽¹⁵⁾ Rare presentations include duodenal intussusception, obstructive jaundice, pancreatitis and diarrhoea owing to motor disturbances.

Barium contrast studies of the small bowel are said to be most sensitive (92%)⁽¹³⁾ for the diagnosis of BGA and may reveal multiple small filling defects (Swiss cheese pattern) in Brunner's gland hyperplasia or a smooth polypoid defect in cases of adenoma.⁽¹⁵⁾ Hypotonic duodenography may have a role for delineating the surface of the lesion. Presently, upper intestinal endoscopy is the diagnostic

method of choice (added with endoscopic biopsy and occasionally ultrasonography). A deep enough endoscopic biopsy (for the submucosal nature of the lesion) usually clinches the diagnosis. The differential diagnosis usually includes leiomyoma, polypoid adenoma of the superficial mucosal glands, adenoma of the islet cells, lipoma, angioma, aberrant pancreatic tissue, duodenal duplication cyst, carcinoid tumour, prolapsed pyloric mucosa, antral polyp and malignant tumours, such as adenocarcinoma, lymphoma, carcinoid tumour and leiomyosarcoma. Endoscopic resection of a pedunculated tumour is more cost effective and less invasive than laparoscopic surgery. Large adenomas may be detected by ultrasonography.

Treatment is conservative for the asymptomatic cases. Medical treatment in the form of antacids, H₂-blocker or proton pump inhibitor usually fails to decrease the lesions. Symptomatic cases either need endoscopic removal or transduodenal exploration and excision of the polyp by laparoscopic or open surgery. A duodenal bypass may be necessary if safe excision is not possible in the diffuse or circumscribed nodular types presenting as obstructive lesions. Though malignant change associated with the lesion has been described twice, recurrence of a resected Brunner's gland adenoma is not documented in the literature. Our case fits with the description of diffuse nodular hyperplasia of Brunner's gland (Feyrter classification type 1) though there was no lesion in the D1 segment. Also, such types of lesion are less likely to present with upper gastrointestinal bleeding (distal, single, polypoid adenomatous growth are more likely). Apart from these two rarities, Brunner's gland

adenoma itself is a very rare cause of upper gastrointestinal bleed, especially from this part of the world.

REFERENCES

1. Henken EM, Forouhar F. Hamartoma of Brunner's gland causing partial obstruction of the ileum. *J Can Assoc Radiol* 1983; 34:73-4.
2. Fuller JW, Maj MC, Cruse CW, Williams JW. Hyperplasia of Brunner's glands of the duodenum. *Am Surg* 1997; 43:246-50.
3. Cruveilhier J. *Anatomie pathologique du corps humain*. Paris: JB Balliere, 1835.
4. Kovacevic I, Ljubicic N, Cupic H, et al. Helicobacter pylori infection in patients with Brunner's gland adenoma. *Acta Med Croatica* 2001; 55:157-60.
5. De Angelis G, Villanacci V, Lovotti D, et al. [Hamartomatous polyps of Brunner's gland. Presentation of 2 cases. Review of the literature]. *Minerva Chir* 1989; 44:1761-6. Italian.
6. Levine JA, Burgart LJ, Batts KP, Wang KK. Brunner's gland hamartomas: clinical presentation and pathological features of 27 cases. *Am J Gastroenterol* 1995; 90:290-4.
7. Farkas IE, Gerö G. The role of Brunner's glands in the mucosal protection of the proximal part of duodenum. *Acta Physiol Hung* 1989; 73:257-60.
8. Feyrter F. Über wucherungen der Brunnerschen Drüsen. *Virchows Arch* 1938; 293:509-26.
9. Merine D, Jones B, Ghahremani GG, Hamilton SR, Bayless TM. Hyperplasia of Brunner glands: The spectrum of its radiographic manifestations. *Gastrointest Radiol* 1991; 16:104-8.
10. Muezzino glu B, Ustum H, Demirhan B, Hilmio glu F. Brunner's gland adenoma: case report. *N Z Med J* 1995; 108:14.
11. Christie AC. Duodenal carcinoma with neoplastic transformation of underlying Brunner's glands. *Br J Cancer* 1953; 7:65-7.
12. Fujimaki E, Nakamura S, Sugai T, Takeda Y. Brunner's gland adenoma with a focus of p53-positive atypical glands. *J Gastroenterol* 2000; 35:155-8.
13. Kaplan EL, Dyson WL, Fitts WT Jr. Hyperplasia of Brunner's glands of the duodenum. *Surg Gynecol Obstet* 1968; 126:371-5.
14. Kaplan EL, Dyson WL, Fitts WT Jr. The relationship of gastric hyperacidity to hyperplasia of Brunner's glands. *Arch Surg* 1969; 98:636-9.
15. De Castella H. Brunner's gland adenoma: unusual cause of intestinal bleeding. *Br J Surg* 1966; 53:153-5.