

Conservative treatment for transient osteoporosis of the hip in middle-aged women

Diwanji S R, Cho Y J, Xin Z F, Yoon T R

ABSTRACT

Transient osteoporosis of the hip is a clinical entity that is being diagnosed and reported with increasing frequency. Its aetiology remains a matter of speculation, and the same remains true for its treatment. Many researchers have proposed different surgical and non-surgical treatment strategies; but the conservative approach, which takes the form of analgesics, intermittent traction, range of motion exercises, abductor strengthening exercises and restricted weight bearing, is preferred. The authors report on two patients, both women, aged 35 years and 42 years, respectively, with transient osteoporosis of the hip that were successfully treated using a conservative approach.

Keywords: bone marrow oedema syndrome, transient osteoporosis of the hip

Singapore Med J 2008; 49(1): e17-e21

INTRODUCTION

Transient osteoporosis of the hip (TOH) is a self-limiting entity of unknown aetiology. It is characterised by disabling pain in one or more joints associated with radiographical evidence of osteopenia limited to involved joints, and the absence of another recognisable cause of bone or joint pathology.⁽¹⁾ The condition was first described by Curtiss and Kincaid in 1959,⁽¹⁾ and was later termed transient osteoporosis of the hip by Lequesne.⁽²⁾ More than 200 cases have been reported in the literature, but the disease appears to be rare in Asians, and few cases have been reported from Asian countries.⁽³⁾ TOH has been reported under different names, i.e., transitory demineralisation, migratory osteolysis, algodystrophy of the hip, and bone marrow oedema syndrome.⁽⁴⁾ Two-thirds of cases have been reported in healthy middle-aged men between the ages of 40 and 60 years, while the remaining one-third of cases reported in women, have occurred almost exclusively in the third trimester of pregnancy or during the early postpartum period. Although the hip is the most commonly affected,

transient osteoporosis can affect the knee, foot, and ankle, and less frequently, the shoulder, lumbar spine, elbow, wrist, and hand.⁽⁴⁾ Concern about TOH increased after it was reported to be an early stage of avascular necrosis (AVN) of the femoral head.⁽⁵⁻⁸⁾ Many authors have recommended surgical interventions, such as core decompression, to confirm diagnosis and prevent disease progression.^(7,8) Likewise, a number of pharmaceutical agents have been examined; these claimed to shorten symptom duration.⁽⁹⁾ We report two cases of TOH, one in a pregnant, and the other in a non-pregnant, woman. Both patients were treated conservatively and made uneventful recoveries.

CASE REPORTS

Case One

A 35-year-old woman presented with a complaint of pain in the left hip and knee of two months duration, which had started abruptly after the birth of her second child. The pain was aggravated by walking and relieved by rest, but there was no nocturnal pain, or history of trauma or pain in any other joint. On examination, she had a limping gait. Minimal tenderness was observed in the groin, and hip movements were terminally restricted (flexion 110°, abduction 30°, adduction 15°, external rotation 25°, and internal rotation 10°). Examinations of the spine, contralateral hip, and both knees revealed no abnormality.

Laboratory investigations were normal. A radiograph of both hips showed diffuse osteopenia in the left femoral head and neck region, with preservation of normal contour and joint space (Fig. 1). Magnetic resonance (MR) imaging showed low signal intensity diffusely involving the femoral head and neck on T1-weighted images and matching high signal intensity on T2-weighted images. Joint effusion was observed on both images (Fig. 2). Dual energy X-ray absorptiometry showed a bone density of 0.647 g/cm² in the femoral neck, with a T-score of -2.11 and an age-matched Z score of -1.86. Bone mineral density in Ward's triangle was 0.580 gm/cm² (T score -2.16); in the trochanter, it was 0.520 gm/cm² (T score -1.64), and the average result between the second and fourth lumbar vertebrae was 0.811 gm/cm² (T score -2.64 in the second, -2.91 in the third and

Center for Joint Disease,
Chonnam National University Hwasun Hospital,
160 Ilsim-Ri, Hwasun-Eup, Hwasun-Gun, Jeonnam 519-809, Korea

Diwanji SR, MS
Fellow

Cho YJ, MD
Resident

Yoon TR, MD
Professor

Brain Korea 21 Project for Biomedical Human Resources, Chonnam National University Hospital, 8 Hak Dong, Dong gu, Guang Ju 561-746, Korea

Xin ZF, MD
Researcher

Correspondence to:
Dr Taek Rim Yoon
Tel: (82) 61 379 7677
Fax: (82) 61 379 7681
Email: tryoon@chonnam.ac.kr

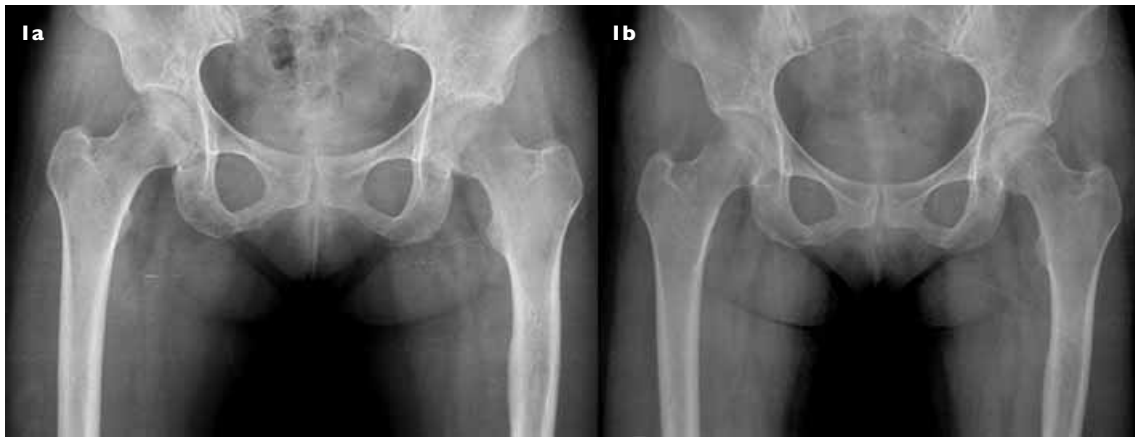

Fig. 1 Case 1. (a) Anteroposterior pelvic radiograph shows osteopenia with loss of a trabecular pattern in the left femoral head. (b) Radiograph taken nine months later shows complete recovery with equal density of both femoral heads.

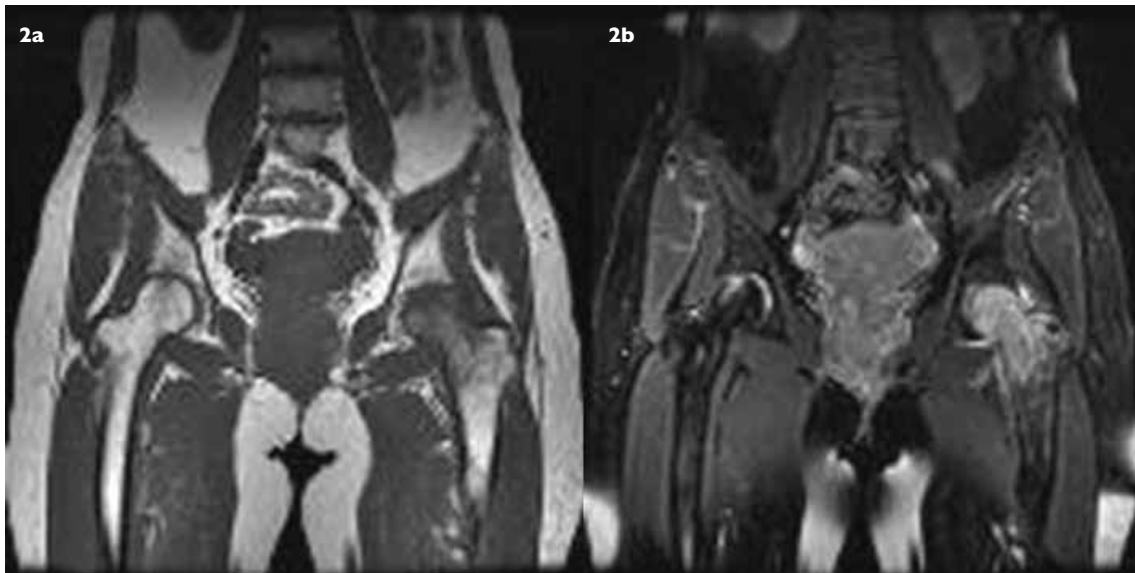


Fig. 2 Case 1. (a) Coronal T1-W MR image shows uniformly decreased signal intensity in the left femoral head and neck. (b) Coronal T2-W MR image shows hyperintensity typical of bone marrow oedema extending up to the intertrochanteric region. Joint effusion is also well visualised.

-2.25 in the fourth lumbar vertebrae). Based on clinical and imaging findings, she was diagnosed as having TOH.

She was treated using intermittent skin traction, analgesics, and range-of-motion exercises for two weeks, followed by non-weight bearing crutch walking and abductor muscle strengthening exercises. Radiographs were obtained monthly. Clinical improvement, in terms of absence of pain on walking and range of motion, was noticed after two months, and radiological improvement was reported after three months. Radiographs and MR imaging were completely normal after nine months. After nine months, bone mineral density in the femoral neck improved from .647 g/cm² to 0.679 g/cm² (T score improved from -2.11 to -1.8). BMD in Ward's triangle changed from 0.580 g/cm² to 0.539 g/cm² (T score changed from -2.16 to -2.6), whereas BMD in the trochanter changed from 0.520 to 0.537 g/cm²

(T score changed from -1.64 to -1.9). She had no residual disability and returned to her routine activities. At the last follow-up ten months post-symptom relief, radiographs were completely normal.

Case Two

A 42-year-old woman presented with a complaint of pain in the right hip of two weeks duration. The pain was localised to the right groin and was typically aggravated by weight bearing. There was no history of trauma. Examination of the right hip revealed minimal groin tenderness, mild flexion deformity (10°), and movement restriction (flexion 80°, abduction 10°, adduction 0°, external rotation 15°, and internal rotation 0°). Laboratory findings were normal, but a radiograph of the pelvis and both hips showed osteopenia of the right femoral head

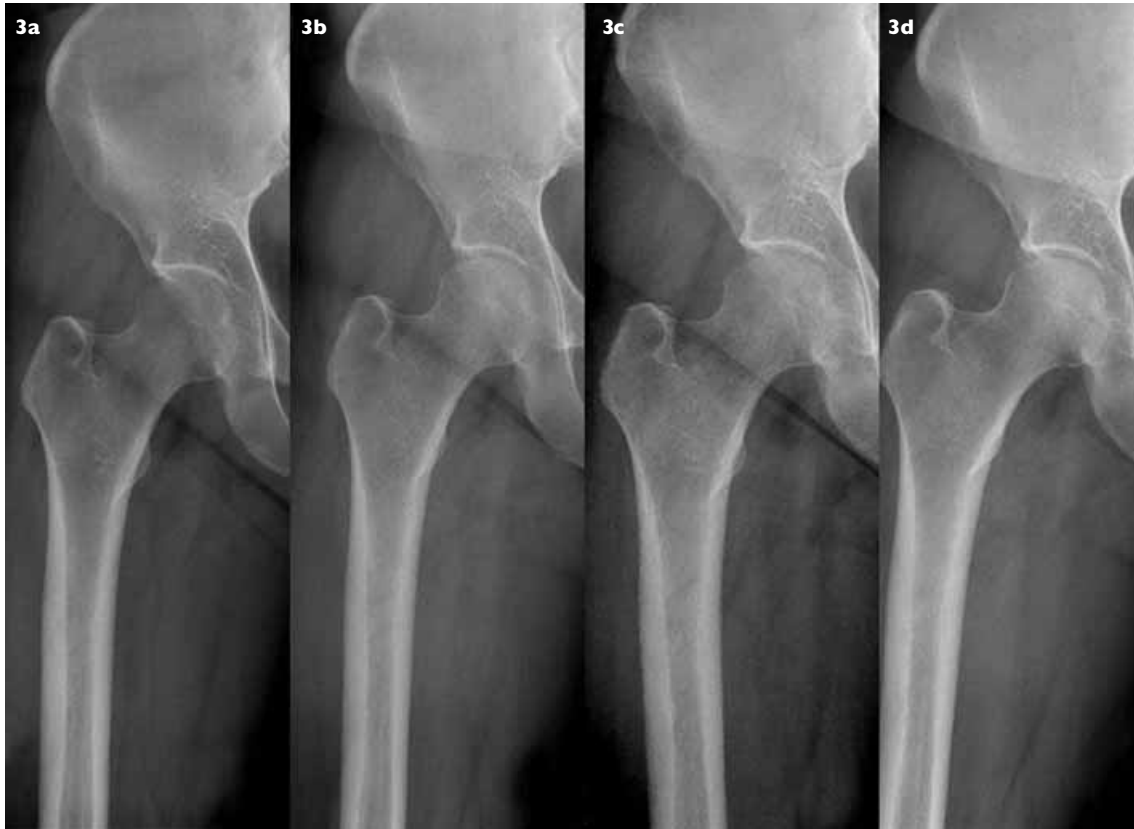


Fig. 3 Case 2. Serial anteroposterior radiographs of the right proximal femur. (a) Radiograph taken at the time of diagnosis shows diffuse osteopenia affecting the right femoral head and neck regions. Radiographs taken at (b) one month and (c) four months, show an improved trabecular pattern. (d) Radiograph taken after 7 months shows a normal femoral head and neck density.

and neck without joint space reduction (Fig. 3). A pin-hole bone scintiscan showed uniformly increased uptake in the right femoral head (Fig. 4). MR imaging showed low signal intensity in the femoral head and neck on T1-weighted images and heterogeneous high signal intensity on T2-weighted images, with joint effusion and joint space preservation. Imaging findings were consistent with the diagnosis of TOH.

She was treated using skin traction, non-steroidal anti-inflammatory drugs (NSAIDs), and range of motion exercises. She was allowed to walk (non-weight bearing) after her pain was reduced, and the flexion deformity corrected. She showed marked clinical and radiological improvement after one month. Abductor muscle strengthening exercises were then started, and imaging studies were repeated at regular intervals (Fig. 3). Seven months after diagnosis, she was absolutely symptom-free and had a full range of motion and normal radiographs. At the last follow-up 22 months post-symptom relief, radiographs were completely normal.

DISCUSSION

Aetiological factors implicated in TOH include a genetic

predisposition, compression of the obturator nerve, Sudeck's atrophy, bone medullary hypertension and small vessel ischaemia, fatty marrow conversion of the proximal femoral metaphysis, and chemical or hormonal factors related to pregnancy.^(3,9,10) Angiographical and scintigraphical studies show that nutrient arteries of the femoral head are dilated and that perfusion is higher than in the unaffected contralateral side. These findings suggest that TOH may be the result of a vasomotor response to an undisclosed aetiological factor, though ischaemia is most likely.^(10,11) Whatever the cause, large numbers of osteoclasts are activated in the femoral head, and osteoid is then deposited, mineralised, and remodelled. Moreover, significant bone loss occurs between resorption and formation; this reduces radiographical density. In addition, this weakened bone is vulnerable to microfractures, which are considered to cause pain on weight bearing.⁽⁹⁾

It is very important for the clinicians to differentiate TOH from AVN. The clinical features of TOH are well described in the literature. The disease is classically characterised by a disabling pain, which is exacerbated by weight bearing and relieved by rest. A striking feature of the condition is that during the period of maximum

symptoms, there is a disproportionate functional disability.^(1,2) On physical examination, the hip may or may not be found to be slightly tender. Range of motion is usually preserved, with occasional restrictions on rotation and abduction. Biochemical, haematological, bacteriological, and serological tests are usually normal.⁽¹⁾ Patients with AVN usually present with groin or hip pain radiating to the buttocks, anteromedial thigh and knee. Pain may be present for several months, and increases in intensity over a period of time. Patient may have any of the risk factors (such as steroid intake, alcoholism, trauma and haemoglobinopathies). Physical examination reveals restriction of movement, especially after the collapse of the femoral head. Symptoms usually correlate with the radiological changes. The characteristic radiographical appearance of TOH is usually present within one or two months of symptom onset. Radiographs reveal diffuse osteopenia of the entire femoral head and neck, which may progress to complete effacement of the subchondral cortex of the femoral head, and in some patients, to the near total disappearance of the osseous architecture. This creates an optical void and a femoral head with a so-called phantom appearance. Rarely, the trochanters, acetabula, and even iliac wings and ischiopubic rami may be affected. However, the joint space is invariably preserved, and at no time is osseous erosion or subchondral collapse observed.⁽¹⁾ In AVN, the classic appearance is that of a mottled radiolucent area surrounded by an area of sclerosis. In the late stages,

radiolucent crescent sign may develop just distal to the articular surface due to subchondral collapse, before flattening of the articular surface.

In TOH, bone scintiscans usually reveal diffuse, increased uptake involving the entire femoral head and neck, and extending to the intertrochanteric line.⁽¹⁾ In AVN, increased uptake is limited to the femoral head and may be less intense. Occasionally, uptake of the isotope over the anterosuperior region of the femoral head is decreased, surrounded by an area of increased uptake due to reactive hyperaemia, forming a cold in hot spot; this is almost pathognomonic to AVN and is never seen in TOH. A study utilising bone densitometry showed that femoral neck bone density 3–5 months after symptom onset was 20% less than in age-matched controls, and that this returned to normal at two years.⁽⁹⁾ Bone densitometry in the present cases showed osteopenia (T score of -2.11) and no significant improvement after nine months.

T1-weighted MR images showed low signal intensity and T2-weighted images revealed matching high signal intensity extending from the femoral head to the intertrochanteric region.^(1,11) In addition, in TOH, effusion is usually present. As is the case with the scintigraphy, abnormalities on MR imaging have been reported within 48 hours after the onset of symptoms for TOH, and findings on serial scans become normal after approximately 6–8 months.^(1,11) Some authors have described low-intensity bands within the bone marrow oedema pattern and suggested that they are either epiphyseal stress fractures or insufficiency fractures of the femoral head.⁽¹²⁾ Vande Berg et al found that the absence of any subchondral changes on MR imaging has a 100% positive predictive value for transient lesions;⁽¹⁾ our findings concur with others concerning the total lack of subchondral change in TOH.^(11,13) Since a bone marrow oedema pattern on MR imaging is observed in both TOH and AVN of the hip, these two diseases are difficult to differentiate from each other. However, it has been demonstrated that the initial MR imaging finding in AVN is a band pattern, though no diffuse bone marrow oedema pattern was observed prior to this on T2-weighted or short inversion time inversion recovery (STIR) images. Moreover, collapsed AVN is commonly visualised as a bone marrow oedema pattern resulting from concomitant oedema after collapse.⁽⁵⁾

Various treatments have been attempted in TOH, but have offered little benefit, and the currently-accepted practice is usually supportive. This entails judicious use of analgesics, NSAIDS, protected weight-bearing, and a graduated physiotherapy regime. The aim is to reduce microfractures and prevent pathological stress fractures.

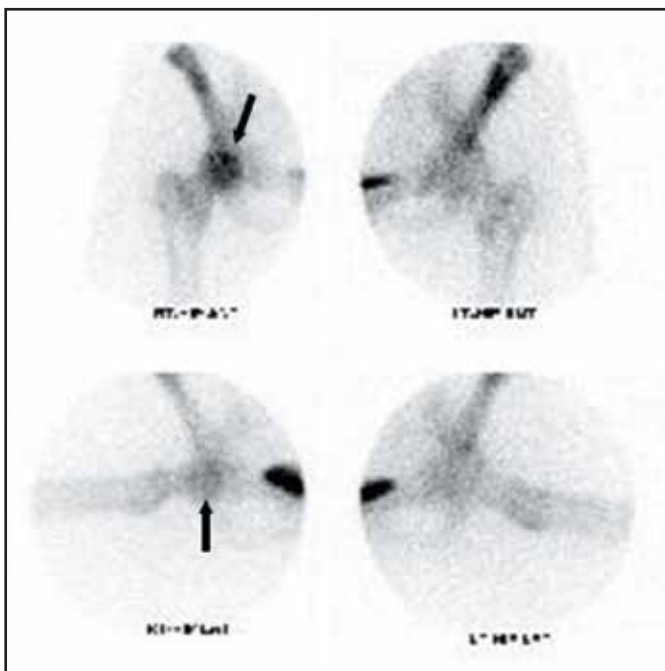


Fig. 4 Case 2. Bone scintiscan shows the entire right femoral head appearing as an area of increased uptake (black arrow), whereas the left femoral head shows normal uptake.

Traction has been used for treatment, but not in pregnant women. Intermittent traction would prove helpful in preventing and/or correcting flexion deformity associated with joint effusion. Range of motion exercises should be started as soon as a patient is comfortable, in order to prevent contracture. Prolonged bed rest leads to profound abductor muscle weakness in these patients and thus, abductor muscle strengthening exercises are an important component of conservative treatment.

Elective caesarean section has been reported for bilateral severe TOH,^(1,9) and bone mineral density improvements have been reported after weaning. Typically, a rapid decrease in symptoms occurs after childbirth.⁽¹⁾ In addition, oral, intravenous and intramuscular bisphosphonates have been reported to have beneficial effects.^(9,14) Calcitonin, prednisolone, and the bone-sparing steroid, deflazacort, have also been used.⁽⁹⁾ The mode of action of antiresorptive agents in TOH is unknown; but it is probably unrelated to the inhibition of osteoclast bone resorption, which is histologically absent in TOH. These agents may be active because of their anti-inflammatory properties, for example, pamidronate reduces proinflammatory cytokine production by activated T-cells. Alternatively, they could act by preventing osteoblast apoptosis, and thus promoting bone formation.⁽⁴⁾ However, all these pharmaceutical studies had small sample sizes and lacked case controls. Thus, the potential benefits of these pharmaceutical agents for the management of a self-limiting condition, particularly in pregnant and lactating women, should be weighed against the risks involved.

Core decompression has been performed to eliminate the risk of progression to full osteonecrosis, to relieve pain, and to reduce symptom duration. However, this procedure seems unnecessarily aggressive for a condition with a uniformly good prognosis without operative intervention.⁽¹⁾ It should be remembered that traumatic and stress fractures and iatrogenic femoral neck fractures have been identified in TOH patients by biopsy.^(5,15) Sympathectomy and a sympathetic nerve blockade appeared to provide pain relief, but did not accelerate recovery.⁽⁴⁾ Both of our patients recovered well on conservative treatment, and in one patient, clinical and radiological improvements were evident within just one month. This is why we do not recommend operative intervention, and advise that the patients' progress be followed closely at regular intervals by imaging.

Most authors reported that TOH completely improved ~12–24 months after onset of disease.^(4,14) However, Radke et al reported that AVN of the femoral head developed at one year after treatment of TOH.⁽¹⁶⁾ Thus, we believe patients with TOH must be followed-up for about two years after disease treatment. We confirmed no development of osteonecrosis in our cases at two years. In conclusion, TOH, though uncommon in non-pregnant women, should be considered in the differential diagnosis of acute onset of hip pain in a middle-aged woman. MR imaging is the most sensitive modality for an early diagnosis. Patients correctly diagnosed as having TOH usually recover well on conservative treatment.

REFERENCES

- Guerra JJ, Steinberg ME. Distinguishing transient osteoporosis from avascular necrosis of the hip. *J Bone Joint Surg Am* 1995; 77:616-24.
- Lequesne M. Transient osteoporosis of the hip. A nontraumatic variety of Sudeck's atrophy. *Ann Rheum Dis* 1968; 27:463-71.
- Kim SY, Koo KH, Suh KT, et al. Fatty marrow conversion of the proximal femoral metaphysis in transient bone marrow edema syndrome. *Arch Orthop Trauma Surg* 2005; 125:390-5.
- Arayssi TK, Tawbi HA, Usta IM, Hourani MH. Calcitonin in the treatment of transient osteoporosis of the hip. *Semin Arthritis Rheum* 2003; 32:388-97.
- Yamamoto T, Kubo T, Hirasawa Y, et al. A clinicopathologic study of transient osteoporosis of the hip. *Skeletal Radiol* 1999; 28:621-7.
- Turner DA, Templeton AC, Selzer PM, Rosenberg AG, Petasnick JP. Femoral capital osteonecrosis: MR finding of diffuse marrow abnormalities without focal lesions. *Radiology* 1989; 171:135-40.
- Hofmann S, Engel A, Neuhold A, et al. Bone marrow edema syndrome and transient osteoporosis of the hip. *J Bone Joint Surg Br* 1993; 75:210-6.
- Hofmann S, Kramer J, Schneider W, Plenk H Jr. Transient osteoporosis may represent a reversible early form of avascular necrosis of the hip joint. *Current Orthop* 1997; 11:164-72.
- Ma FY, Falkenberg M. Transient osteoporosis of the hip: an atypical case. *Clin Orthop Relat Res* 2006; 445:245-9.
- Koo KH, Ahn IO, Song HR, Kim SY, Jones Jr JP. Increased perfusion of the femoral head in transient bone marrow edema syndrome. *Clin Orthop Relat Res* 2002; 402:171-5.
- Malizos KN, Zibis AH, Dailiana Z, et al. MR imaging findings in transient osteoporosis of the hip. *Eur J Radiol* 2004; 50:238-44.
- Miyaniishi K, Yamamoto T, Nakashima Y, et al. Subchondral changes in transient osteoporosis of the hip. *Skeletal Radiol* 2001; 30:255-61.
- Balakrishnan A, Schemitsch E H, Pearce D, McKee M D. Distinguishing transient osteoporosis of the hip from avascular necrosis. *Can J Surg* 2003; 46:187-92.
- La Montagna G, Malesci D, Tirri R, Valentini G. Successful neridronate therapy in transient osteoporosis of the hip. *Clin Rheumatol* 2005; 24:67-9.
- Wood ML, Larson CM, Dahners LE. Late presentation of a displaced subcapital fracture of the hip in transient osteoporosis of pregnancy. *J Orthop Trauma* 2003; 17:582-4.
- Radke S, Kenn W, Eulert J. Transient bone marrow edema syndrome progressing to avascular necrosis of the hip. *Clin Rheumatol* 2004; 23:83-8.