

# Intraperitoneal extravasation of total parental nutrition infusate from an umbilical venous catheter

Shareena I, Khu Y S, Cheah F C

## ABSTRACT

A preterm male infant who had an umbilical venous catheter (UVC) *in situ* for infusion of total parenteral nutrition (TPN) subsequently developed abdominal distension. He was initially diagnosed to have necrotising enterocolitis. However, a diagnostic abdominal paracentesis yielded fluid which biochemical analysis found to be consistent with TPN. TPN is often infused through a UVC, in the first few days of life, for the nutritional support of a premature infant. Various complications have been reported to be associated with this path of delivery, one of which will be illustrated in this case report.

**Keywords:** ascites, paracentesis, total parenteral nutrition, umbilical venous catheter

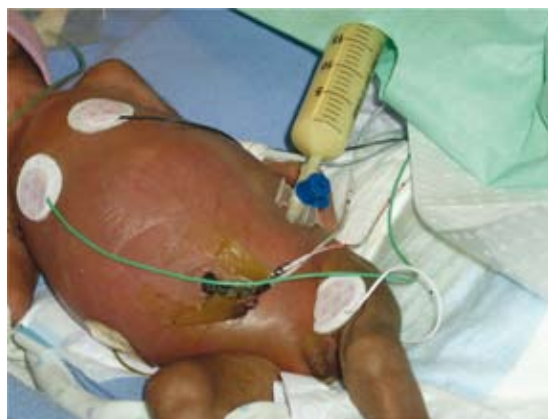*Singapore Med J 2008; 49(2):e35-e36*

## INTRODUCTION

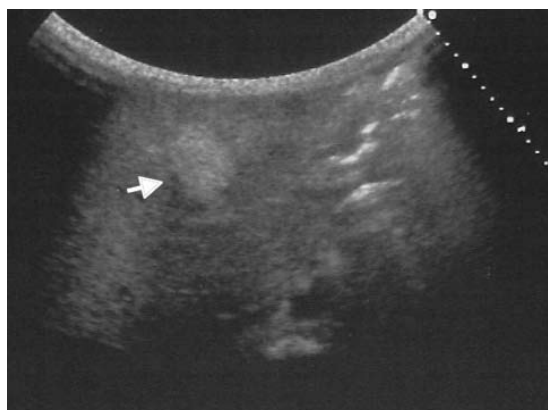
The insertion of a umbilical venous catheter (UVC) is a common procedure in the neonatal intensive care unit. Intraperitoneal extravasation of total parenteral nutrition (TPN) has been cited as one of the complications associated with malpositioned UVC, which may lead to vessel perforation or liver capsule disruption as a result of hepatic necrosis.<sup>(1)</sup> Prognosis is generally good with spontaneous resorption. We report a preterm infant initially diagnosed to have worsening necrotising enterocolitis (NEC), but paracentesis revealed intraperitoneal extravasation of TPN from an UVC.

## CASE REPORT

A size 5-F double-lumen silicon catheter (Utah Medical Products, West Midvale, UT, USA) was inserted into the umbilical vein of a preterm male infant of 27 weeks gestation, without much difficulty. The infant weighed 1,100 g. The tip of the UVC was confirmed to be at the level of the 11th thoracic vertebra on plain radiograph. From day one of life, TPN was commenced by continuous infusion through the UVC. Enteral feeds of 1 ml every three hours was started at day two of life, and was subsequently increased to 1.5 ml every three hours the next day. However, a day later, he appeared lethargic and



**Fig. 1** Photograph shows an intraperitoneally extravasated total parenteral nutrition infusate delivered via a malpositioned umbilical venous catheter tip in the liver. A total of 135 ml of the infusate was removed by paracentesis.



**Fig. 2** US image of the abdomen shows an area of increased echogenicity (arrow) in the left lobe of the liver, which may be due to the tip of the malpositioned UVC.

developed abdominal distension. He was hyperglycaemic and his arterial blood gas showed evidence of metabolic acidosis. He was also thrombocytopenic.

Abdominal radiograph showed dilated loops of the bowels and he was treated as having sepsis with early stage NEC. He was kept nil by mouth, commenced on parenteral antibiotics and established on full TPN support (Glucose 15%, Vaminolact® 3.5 g/kg/day and Intralipid® 20% 3 g/kg/day [Fresenius Kabi AG, Bad Hamburg v.d.H, Germany]) at 150 ml/kg/day. Despite repeated sterile blood cultures and resolved biochemical and haematological abnormalities, his abdominal distension progressively worsened. A repeat abdominal radiograph on day nine showed generalised haziness with minimal

Department of  
Paediatrics,  
Faculty of Medicine,  
Universiti  
Kebangsaan  
Malaysia,  
Bandar Tun Razak,  
Kuala Lumpur  
56000,  
Malaysia

Shareena I, MBBS,  
MMed  
Lecturer

Khu YS, MBBS  
Senior Medical  
Officer

Cheah FC, MD,  
MMed, PhD  
Consultant  
Neonatologist

**Correspondence to:**  
Dr Shareena Ishak  
Tel: (60) 3 9170 2192  
Fax: (60) 3 9173  
7827  
Email:  
shareena@mail.  
hukm.ukm.my

bowel shadows and an ultrasonography confirmed the presence of ascites.

His abdomen became very tense three days later, and this was associated with worsening respiratory function requiring ventilatory support. Increasingly high peak inspiratory pressures were necessary to facilitate adequate chest expansion and oxygenation. To relieve diaphragmatic splinting from the ascites, and to determine if there were evidence of bowel perforation and peritonitis secondary to NEC, paracentesis was performed. A total of 135 ml of yellowish and milky-looking fluid, that appeared like a mixture of the TPN infusate, was removed (Fig. 1). Results from biochemical analysis of the fluid were consistent with the contents of TPN (protein 29 g/L and triglycerides 22.97 mmol/L). The serum protein and triglycerides taken simultaneously was 43 g/L and 2.18 mmol/L, respectively. Microscopic examination revealed a paucity of cellular components and the culture of the fluid was sterile.

A diagnosis of intraperitoneal extravasation of TPN from the UVC was made. The catheter was promptly removed. Ventilatory support could be weaned off rapidly after the abdominal decompression and there was marked clinical improvement. Feeds were recommenced three days later. Repeat ultrasonography of the abdomen showed minimal residual ascites, and a rounded hyperechoic lesion in the left lobe of the liver (Fig. 2). Subsequently, his condition improved, and was discharged without any further complication related to the UVC insertion.

## DISCUSSION

Umbilical venous catheterisation provides a quick and easy access for the initial administration of fluid therapy to critically-ill preterm neonates. Ideally, the UVC tip should be in the inferior vena cava at the level of the diaphragm. This normally corresponds to the level between the seventh and ninth thoracic vertebrae on a radiograph. The majority of UVC tips sited below this level were found to be within the liver.<sup>(2)</sup> Among the numerous complications associated with malpositioned UVC tips, leading to intraperitoneal spillage, are perforation of vessels and intra-abdominal haemorrhage, as well as ascites from intraperitoneal extravasation of TPN.<sup>(3,4)</sup> The insidious nature of the abdominal distension, and the absence of haemodynamic instability in this case, suggests that direct vessel perforation was unlikely to have preceded the TPN

extravasation. Instead, as described by Coley et al,<sup>(5)</sup> hepatic necrosis leading to disruption of the liver capsule was more likely to have been the antecedent event.

Prior reports have identified risk factors predisposing to hepatic necrosis, including hypertonicity of the infusate and a longer duration of placement of the catheter.<sup>(5)</sup> Hypertonic solutions may produce local hepatic parenchymal injury and necrosis, even in the absence of an associated vascular thrombus.<sup>(5)</sup> The patient had received TPN ranging from approximately 800–1,000 mosmol/L via the UVC. Due to difficult venous access, his catheter was *in situ* for almost two weeks. Furthermore, the hyperechoic lesion in the liver (Fig. 2) might represent evidence of hepatic parenchymal insult in the vicinity of the UVC tip.

Prognosis of intraperitoneal TPN extravasation is generally good, with recovery following spontaneous resorption. The paracentesis performed in this case had helped to clinch the diagnosis, and also averted the risk of an air-leak syndrome from increasing airway pressures due to mechanical ventilation to overcome diaphragmatic splinting. Even though free flow of blood on aspiration may indicate intravascular placement of an UVC, the identification of an appropriately sited UVC tip using ultrasonography provides a more accurate confirmation of catheter placement than radiography.<sup>(2,6)</sup> Intermittent assessment of the location of the tip of the UVC should be carried out to reduce the complications that may arise. This is advisable before a UVC access is considered safe for longer term TPN or other fluid infusion therapy.

## REFERENCES

1. Rejjal AR, Galal MO, Nazer HM, Karim AA, Osba YA. Complications of parenteral nutrition via an umbilical vein catheter. *Eur J Pediatr* 1993; 152:624.
2. Greenberg M, Movahed H, Peterson B, Bejar R. Placement of umbilical venous catheters with use of bedside real-time ultrasonography. *J Pediatr* 1995; 126:633-5.
3. Kanto WP Jr, Parrish RA Jr. Perforation of the peritoneum and intra-abdominal hemorrhage: a complication of umbilical vein catheterizations. *Am J Dis Child* 1977; 131:1102-3.
4. Panetta J, Morley C, Betheras R. Ascites in a premature baby due to parenteral nutrition from an umbilical venous catheter. *J Paediatr Child Health* 2000; 36:197-8.
5. Coley BD, Seguin J, Cordero L, et al. Neonatal total parenteral nutrition ascites from liver erosion by umbilical vein catheters. *Pediatr Radiol* 1998; 28:923-7.
6. Raval NC, Gonzalez E, Bhat AM, Pearlman SA, Stefano JL. Umbilical venous catheters: evaluation of radiographs to determine position and associated complications of malpositioned umbilical venous catheters. *Am J Perinatol* 1995; 12:201-4.