

Subungual squamous cell carcinoma masquerading as a melanotic macule

Oon H H, Kumarasinghe S P W

ABSTRACT

Subungual squamous cell carcinoma is a rare condition. Diagnosis is often delayed because it presents with minimal nail changes and mimics a number of benign nail conditions. We report a 43-year-old Chinese man who presented with a three-year history of an indolent melanotic macule of the fingernail. Histology from a punch biopsy revealed a well-differentiated squamous cell carcinoma. Wide local excision with full thickness skin grafting was performed. Physicians should have a high index of clinical suspicion as early nail biopsy and prompt tumour clearance can preserve joint function.

Keywords: fingernail bed tumour, melanotic macule, squamous cell carcinoma, subungual squamous cell carcinoma

Singapore Med J 2008;49(3):e76-e77

INTRODUCTION

The vast majority of nail bed conditions treated by clinicians are benign. Although rare, subungual squamous cell carcinoma (SCC) is the most common malignancy affecting the nail bed.⁽¹⁾ Presenting symptoms can range from deceptively benign nail plate dyschromia, onycholysis and paronychia, to bleeding, frank ulceration and distant metastases. A nail biopsy is diagnostic but often delayed, due to lack of physician awareness of malignancy, and treatment delay for benign conditions, such as warts and fungal infection. This case illustrates the need for a high index of suspicion when faced with a newly-acquired pigmented acral lesion.

CASE REPORT

A 43-year-old Chinese man on regular attendance at our dermatology department for lichen amyloidosis of the legs presented with a three-year history of an asymptomatic, stable discolouration affecting his left fourth fingernail. Previous cultures excluded onychomycosis. Examination revealed a 3-mm linear pigmented band at the distal radial aspect of the nail bed, extending to the distal nailfold with subungual hyperkeratosis. There was no history of immunosuppression or trauma. Systemic examination was unremarkable. Clinically, the differential diagnoses of melanotic macule or subungual melanoma were considered.

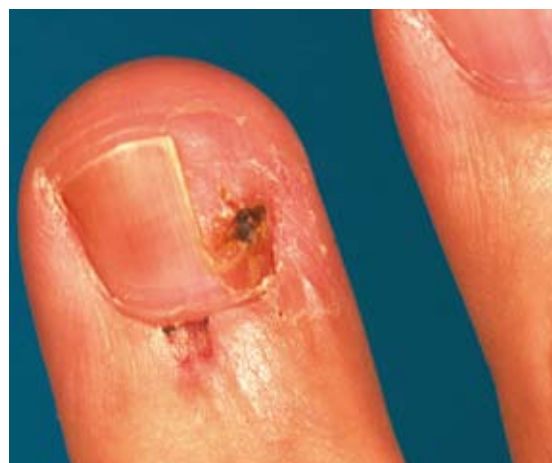

Fig. 1 Clinical photograph shows subungual squamous cell carcinoma after exploratory nail plate removal.

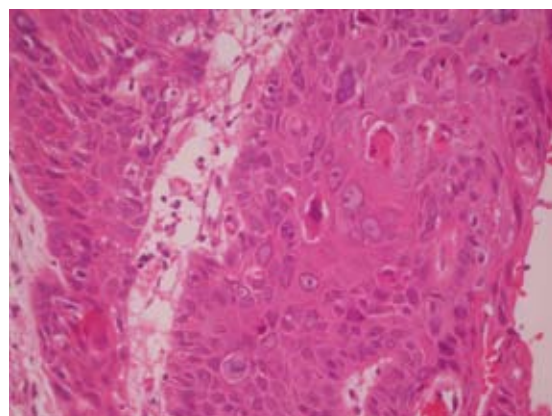


Fig. 2 Photomicrograph shows squamous cell carcinoma with marked cellular pleomorphism and mitoses (Haematoxylin & eosin, $\times 40$).

A punch biopsy was performed for a definitive diagnosis. Removal of the nail plate showed a well-circumscribed pigmented macule of the nail bed. Two weeks post-biopsy, the lesion showed residual pigmentation with mild crusting and haemorrhage (Fig. 1). The punch biopsy was consistent with moderately-differentiated SCC with no features of viral warts (Fig. 2). Following the biopsy report, re-excision of the lesion was performed with a full-thickness skin graft. Histopathology of the excised residual lesion re-confirmed the diagnosis of an *in situ* moderately-differentiated SCC. Excision margins were clear of tumour. Radiograph of the finger was normal.

National Skin Centre,
1 Mandalay Road,
Singapore 308205

Oon HH, MD, MMed,
MRCP
Registrar

Kumarasinghe SPW,
MD, FCCP, FAMS
Senior Consultant

Correspondence to:
Dr Hazel H Oon
Tel: (65) 6253 4455
Fax: (65) 6253 3225
Email: hazeloon@nsc.gov.sg

DISCUSSION

SCC is the commonest malignancy of the nail unit.⁽¹⁾ However, subungual SCC is rare among Asians. Lai et al reported a patient from Taiwan with a fungating digital mass, axillary lymphadenopathy and bony involvement.⁽²⁾ Another two Taiwanese patients presented with chronic ulcers of the nail bed.⁽³⁾ Chang et al described a Korean patient with metastatic SCC of the nail bed from a primary lung malignancy.⁽⁴⁾ Two patients from Hong Kong had ulcerated and discharging lesions, while the third case had chronic pain and swelling over the radial right finger of a year's duration.⁽⁵⁾

While the precise aetiology of subungual SCC remains to be determined, risk factors include sun exposure, trauma, immunosuppression, human papilloma virus infection, radiation⁽⁶⁾ and ectodermal dysplasia.⁽⁷⁾ Our patient was relatively young and did not possess any of these risk factors. Diagnosis of this condition is inherently difficult, because of its resemblance to a variety of benign conditions, such as viral warts, onychomycoses, paronychia, glomus tumours, keratoacanthomas and melanotic naevi.^(5,9) A rapidly-growing, ulcerating lesion would certainly alert the clinician to investigate further for malignancy. However, subungual SCC runs an indolent course and may present with minimal symptoms.⁽⁸⁾

The diagnosis of SCC of the nail bed is frequently delayed. The time to diagnosis has been reported to be four years on average,⁽¹⁾ and in some cases, may not be detected for up to 40 years.⁽⁹⁾ We highlight the need for a high index of suspicion when confronted with a chronic pigmented acral lesion, with early biopsy and histology for definitive diagnosis. Dermoscopy of the nail apparatus has been shown to be increasingly helpful in differentiating between pigmentation from non-melanocytic origin such

as subungual haematoma, bacterial or fungal infections, and the melanocytic lesions of benign naevi, racial pigmentation and melanoma.⁽¹⁰⁾ Up to 55% of the cases of subungual SCC may result in bony invasions.⁽⁹⁾ We believe that in our patient, early diagnosis and referral for excision while the tumour remained confined to the nail bed obviated the need for amputation of the phalanx.

ACKNOWLEDGEMENT

We are grateful to Dr Christopher CI Foo (Consultant, Raffles Medical Hospital) and Dr Beng Hock Ong (Visiting Dermatopathologist, National Skin Centre) for their assistance with the histopathological aspects of this case.

REFERENCES

1. Carrol RE. Squamous cell carcinoma of the nail bed. *J Hand Surg Am* 1976; 1:92-7.
2. Lai CS, Lin SD, Tsai CW, Chou CK. Squamous cell carcinoma of the nail bed. *Cutis* 1996; 57:341-5.
3. Yip KM, Lam SL, Shee BW, Shun CT, Yang RS. Subungual squamous cell carcinoma: report of 2 cases. *J Formos Med Assoc* 2000; 99:646-9.
4. Chang SE, Choi JH, Sung KJ, Moon KC, Koh JK. Metastatic squamous cell carcinoma of the nail bed: a presenting sign of lung cancer. *Br J Dermatol* 1999; 141:939-40.
5. Wong TC, Ip FK, Wu WC. Squamous cell carcinoma of the nail bed: three case reports. *J Orthop Surg (Hong Kong)* 2004; 12:248-52.
6. Guitart J, Bergfeld WF, Tuthill RJ, et al. Squamous cell carcinoma of the nail bed: a clinicopathological study of 12 cases. *Br J Dermatol* 1990; 123:215-22.
7. Campbell CJ, Keokam T. Squamous-cell carcinoma of the nail bed in epidermal dysplasia. *J Bone Joint Surg Am* 1966; 48:92-9.
8. Hale LR, Dawber RP. Subungual squamous cell carcinoma presenting with minimal nail changes: a factor in delayed diagnosis? *Australas J Dermatol* 1998; 39:86-8.
9. Lumpkin LR 3rd, Rosen T, Tschen JA. Subungual squamous cell carcinoma. *J Am Acad Dermatol* 1984; 11:735-8.
10. Braun RP, Baran R, Le Gal FA, et al. Diagnosis and management of nail pigmentations. *J Am Acad Dermatol*. 2007; 56:835-47.